

REMINISCENT RADIOPACITY WITHIN A RADIOLUCENCY: AN INTERESTING CASE REPORT

DEFINITION

- **WHO** defines ameloblastic fibrodentinoma (AFD) lesion as a very rare neoplasm composed of odontogenic epithelium and an immature odontogenic connective tissue, characterised by the formation of dysplastic dentin.
- Also called a dentinoma or fibroameloblastic dentinoma.
- An intermediate stage between ameloblastic fibroma and ameloblastic fibro-odontoma.
- First case of ameloblastic fibrodentinoma was reported by Straith in 1936.
- Most studies showed that AFD occurred in two forms, mature and immature dentinoma.

EPIDEMIOLOGY

- Incidence - 0.1% of benign tumours.
- Age - In young individuals, mainly 1st and 2nd decades.
- Gender- Males > Females with a ratio of 3:1.
- Site - Incisor area in primary teeth, mandibular molar area in permanent teeth

CLINICAL FEATURES/IMAGING

- Presents itself as an asymptomatic slow-growing swelling commonly associated with an unerupted tooth.
- Central as well as peripheral AFD have been reported.
- Radiographically shows a fairly well-delineated radiolucency with varying degree of radiopacity owing to the formation of dentin.

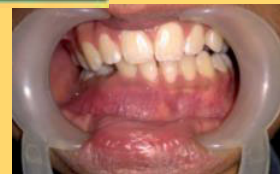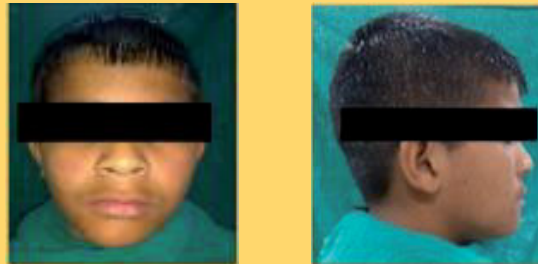CASE PRESENTATION

HISTORY OF ILLNESS

- 13-year-old male.
- Firm swelling in lower jaw region on right side for 3 months with mild intermittent pain while eating & speaking for 2 months.
- Non-contributory medical and trauma history.
- Not associated with any discharge.

EXAMINATION

- Obliteration of buccal vestibule
- Swelling was non compressible, non-fluctuant, non-tender, afebrile and normal colour of overlying skin.
- 43 was missing with displacement 42 and 44.



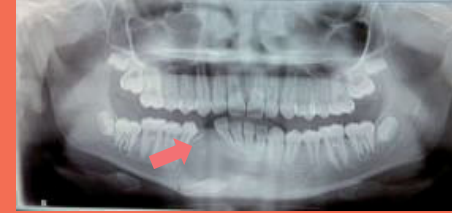PROVISIONAL DIAGNOSIS

Dentigerous cyst with respect to 43

DIFFERENTIAL DIAGNOSES

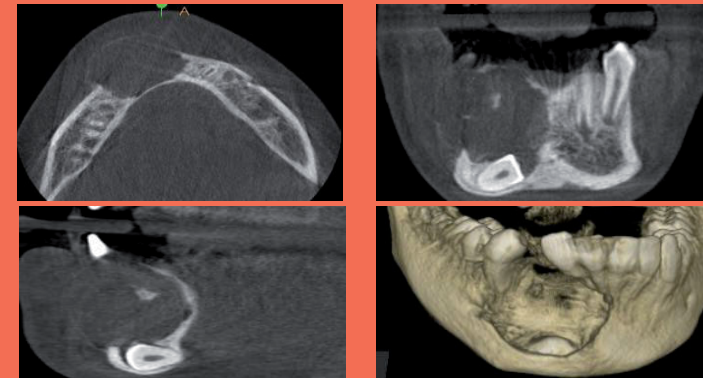
- Adenomatoid odontogenic tumour (AOT)
- Ameloblastic fibroma
- Central giant cell granuloma (CGCG)
- Odontogenic myxoma
- Giant cell lesion of hyperparathyroidism
- Aneurysmal bone cyst (ABC)
- Ameloblastoma

IMAGING

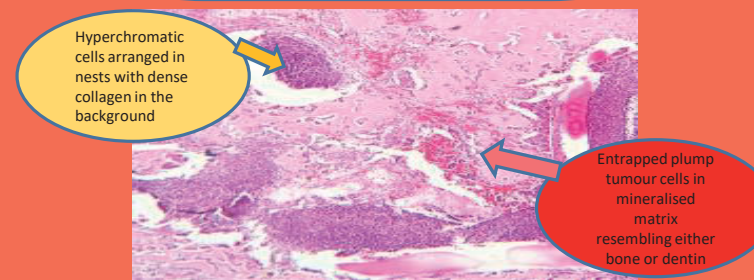


- Osteolytic lesion on right side of mandible with flecks of calcification.
- Flaring of roots of 42 & 44.
- Horizontally impacted 43 is seen.

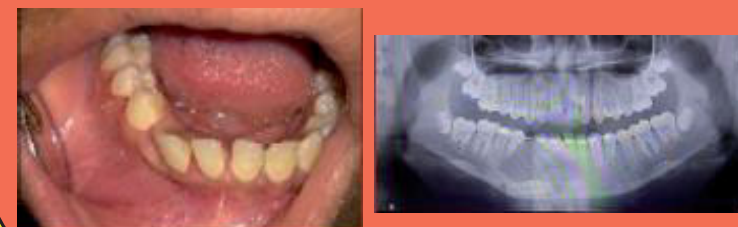CBCT VIEWS



HISTOPATHOLOGY



POST OPERATIVE PHOTOGRAPH



DISCUSSION

- Although it is a benign, rare, and non-recurrent tumour, delayed eruption, missing, or impaction of permanent teeth in paediatric patient emphasises the importance of early radiographic examination of these conditions for early detection, diagnosis, and treatment considering AFD in its differentials.
- It accounts for a small percentage of odontogenic tumours, and only around 65 cases have been reported so far.

DIFFERENTIAL DIAGNOSES

Adenomatoid odontogenic tumour

Central Giant Cell Granuloma

Aneurysmal Bone Cyst

Odontogenic Myxoma

Ameloblastic Fibroma

Ameloblastoma

Brown's tumour

REFERENCES

- Bhargava D,Dave A,Sharma B,Nanda K. Ameloblastic fibrodentinoma. Indian J Dent Res 2011;22:345-7.
- Akal U,Gunhan O, Guler M. Ameloblastic fibrodentinoma: Report of two cases. Int J Oral Maxillofac Surg 1997;26:455-7.
- AhmedM, Sadat SM,Rita SN. Ameloblastic fibrodentinoma of mandible: A case report. J Bangladesh Coll Phys Surg 2006;24:119-21.
- Kramer IR, Pindborg JJ, Shear M. Histological typing of Odontogenic Tumor. 2 ed. Germany Springer Verlag;1992.
- Chrcanovic BR,Gomez RS: Ameloblastic fibrodentinoma and ameloblastic fibroodontoma : an updated systematic review of cases reported in the literature. J Oral Maxillofac Surg. 2017,1:113.10.1016/j.joms.2016.12.038.
- Bavle R M, Muniswammappa S, Venugopal R, et al. (June 14, 2017) Ameloblastic Fibrodentinoma A Case with Varied Patterns of Dysplastic Dentin. Cureus 9 (): e1349.DOI 10.7759/cureus.1349.
- Sabu,A.M.,Gandhi, S.,Singh,I. et al. J. Maxillofac. Oral Surg. (2018) 17: 444. <https://doi.org/10.1007/s12663-017-1062-3>.