

DZZ

1 | 2020
2. VOLUME

INTERNATIONAL

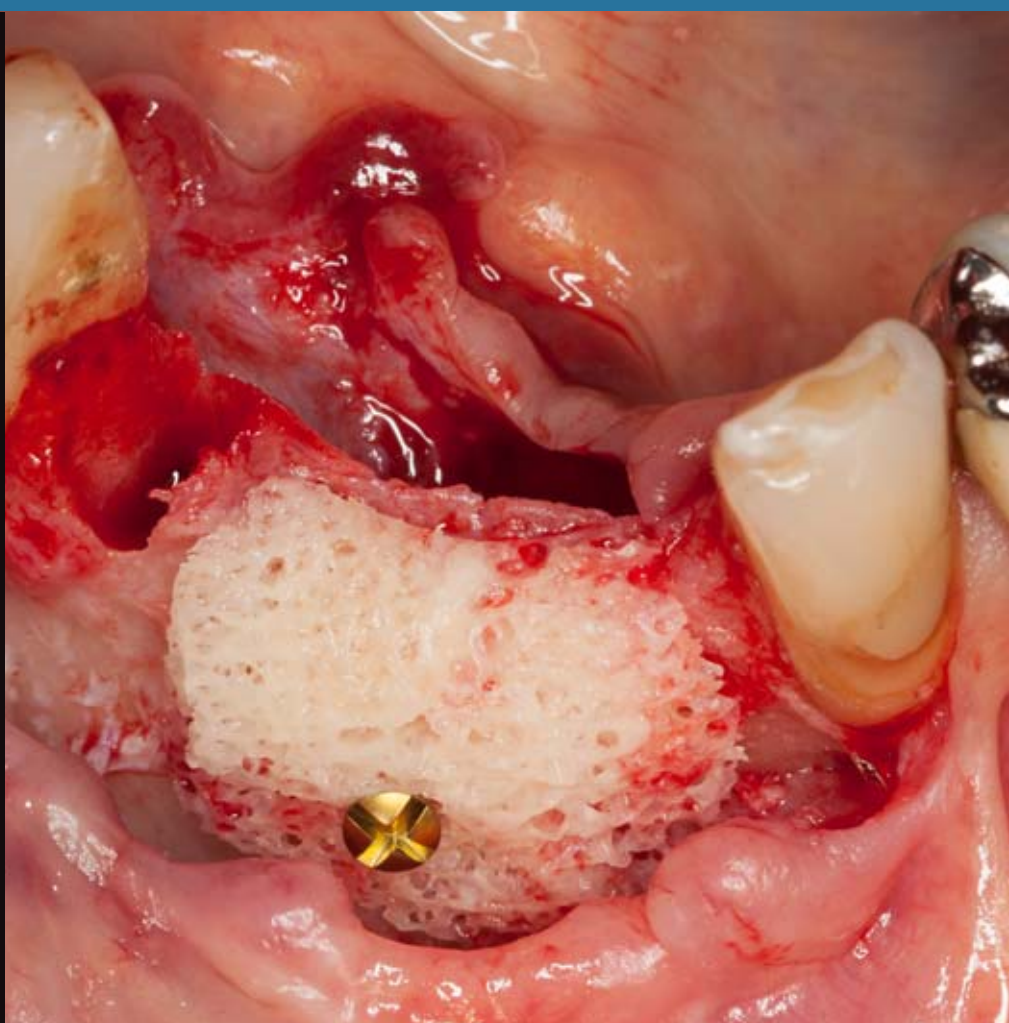
German Dental Journal International – www.online-dzz.com
International Journal of the German Society of Dentistry and Oral Medicine

Changing the bite position
in a patient with tooth hard
substance loss

Implant-prosthetic rehabili-
tation using individualized
allogeneic bone blocks for
bone defects caused by
peri-implantitis

Use, attitudes, side effects
and satisfaction with nitrous
oxide sedation for dental
treatment in Germany

Self-assembling peptides for
caries prevention and treat-
ment of initial carious lesions



This journal is regularly listed
in CCMED / LIVIVO.

 Deutscher
Ärzteverlag

PRACTICE**MINIREVIEW**

Michael Behr, Jochen Fanghänel, Angelika Rauch

3 Changing the bite position in a patient with tooth hard substance loss**CASE REPORT**

Alice Josephine Müller, Simon Peroz, Frank Peter Strietzel

8 Implant-prosthetic rehabilitation using individualized allogeneic bone blocks for bone defects caused by peri-implantitis**RESEARCH****ORIGINAL ARTICLE**

Christian Splieth, Ibraheem Hatout, Johanna Splieth, Julian Schmoeckel, Mhd Said Mourad, Mohammad Alkilzy

14 Use, attitudes, side effects and satisfaction with nitrous oxide sedation for dental treatment in Germany**REVIEW**

Mohammad Alkilzy, Christian H. Splieth

21 Self-assembling peptides for caries prevention and treatment of initial carious lesions, a review**26 LEGAL DISCLOSURE**

Title picture: From case report of Alice Josephine Müller, Simon Peroz and Frank Peter Strietzel, here figure 7: Intraoperative situation after fixation of the patient-specific allografts (Maxgraft Bone Builder®, Botiss, Zossen, Deutschland), p. 8–13; (photo: A.J. Müller)

Online-Version of DZZ International: www.online-dzz.com

Changing the bite position in a patient with tooth hard substance loss



Question?

Can we easily just raise the vertical dimension of occlusion?

Background

For esthetic and functional reasons, patients with visible attrition of their teeth often have the wish to compensate the loss of their tooth hard tissue (Fig. 1). Many dentists try to accommodate these concerns. In this regard, they reconstruct the original tooth shape by means of prosthetic measures such as by crowning the teeth or by applying veneers or table-tops. In doing this, the majority of dentists assume, that by restoring the original tooth shape and size, that they automatically reconstruct the original vertical dimension of occlusion. They simply equate the loss of tooth structure with a loss of bite height.

However, the question arises if the view that tooth hard substance loss automatically leads to a loss of the vertical dimension of occlusion (bite reduction) is correct. This view has been doubted for many years [2, 6, 8] and increasingly more in the last while [1, 10, 13]. Critics, like Dawson [8], believe that the occlusion's vertical dimension remains largely at the same level in relation to the skull, even when the tooth structure is subjected to wear (Fig. 2). Hence, Dawson strongly warns against applying prosthetic restorations in cases that involve massive

tooth hard tissue loss, where solely the original, esthetically correct tooth height and shape is taken into account. Due to the "overcompensation" of the supposed reduction of the occlusal vertical dimension, parafunctions are all the more likely to be triggered.

On the one hand, there are patients who repeatedly show up during office hours for masticatory system dysfunctions, who do not tolerate the measures taken to raise their bite position. On the other hand, there are patients who can, without problems, adapt to a raised bite position by means of an occlusal splint or prosthetic measures. This article will therefore examine which physiological structures control the adjustment of the vertical bite position.

After the development of the 3 cotyledons (Fig. 3), an unpaired neural crest develops after the closure of the neural folds. From the neural crest, ectodermal cells, or so-called neural crest cells, migrate into the areas corresponding to the upper and lower jaws (Fig. 4). The neural crest cells use molecules of the extracellular matrix as a pathway for their migration. Subsequently, a first primitive oral cavity develops, which is lined with epithelial cells. In the area of these epithelial cells, there is a local increase in the number of cells with an accompanying ball-shaped growth in density [5, 11]. The odontogenic epithelium arises, which in

interaction with the adjacent mesenchyme produces ameloblasts on the epithelial side and odontoblasts on the mesenchyme side (Fig. 5). Embryonic tooth development explains why teeth have the ability to maintain eruption in an occlusal direction and have a mesial migration tendency throughout their life. This ability is comparable to the lifelong growth of hair and nails, which are also of ectodermal origin. The logic behind the lifelong ability of our teeth to erupt and migrate in a mesial direction was described by Begg in 1954 [2] when he examined the teeth of Australian Aboriginal people. Owing to their diet, young adults already had considerable occlusal and circular tooth substance loss; the original cusps and their enamel were largely abraded. In spite of this, the dental arches were free of any gaps due to the migration and eruption processes of the teeth. Furthermore, the older the patients were, the more frequent were an end-to-end bite and a tooth-to-tooth relation. The currently accepted textbook-type of occlusion together with a sagittal step and an overbite was only present in adolescents. The authors Alt et al. [1] assume that the occlusal relations described above were widespread throughout our population until about 300 years ago. Nowadays, due to the transition towards a diet based on softer food, more pronounced bite positions and overbites have developed, which can

also be seen in older adults. In light of this fact, Alt et al. [1] see this as the cause for tooth crowding and malpositions in our time.

Due to the permanent ability of teeth to erupt and migrate in the mesial direction, tooth hard substance loss in the vertical dimension was compensated for in Aboriginal people. Also, the alveolar bone grew together with the eruption of the teeth throughout life. Thus, Begg assumed that “as occlusal attrition occurs, occlusal contact of all teeth is maintained, without reduction in the interalveolar distance, by the hereditary process of continual tooth eruption” [2]. This fact means: if the wear of the hard tooth substance is continuous and slow, the vertical dimension of occlusion remains to a great extent identical throughout life.

The adjustment of the bite position and masticatory plane is related to the interplay between the eruption tendency of the teeth and the activity of the masticatory muscles [3] (Fig. 6). To illustrate this, when deglutition occurs unconsciously about 1000 to 2000 times during the day, the adductor muscles of mastication briefly pull the lower jaw in the retruded contact position of occlusion; this short impulse of tooth contact is registered by the various periodontal receptors. Furthermore, during deglutition, receptors (Ruffini endings, Pacini corpuscles, Golgi tendon organs, free nerve endings) register the position of the temporomandibular joint, the muscles as well as the surrounding soft tissue of the stomatognathic system. It is likely that via these receptors, comparisons in the centers of the somatosensory system take place, which analyze the position of teeth, masticatory plane, musculature, and joint. Depending on the analysis of the receptor impulses, instructions are then provided by the motor cortex to the basal ganglia and the red nucleus; for example, this may involve coordinating the muscles to bring about the resting position, or in the case of “disturbances” such as a raised bite position, it may involve triggering muscle activity to eliminate the disturbing contact (Fig. 6).

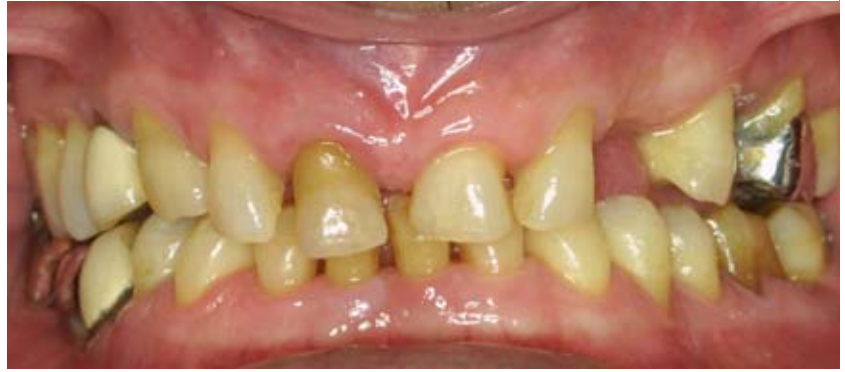

Figure 1 72 year-old patient with attrition of the tooth hard substance

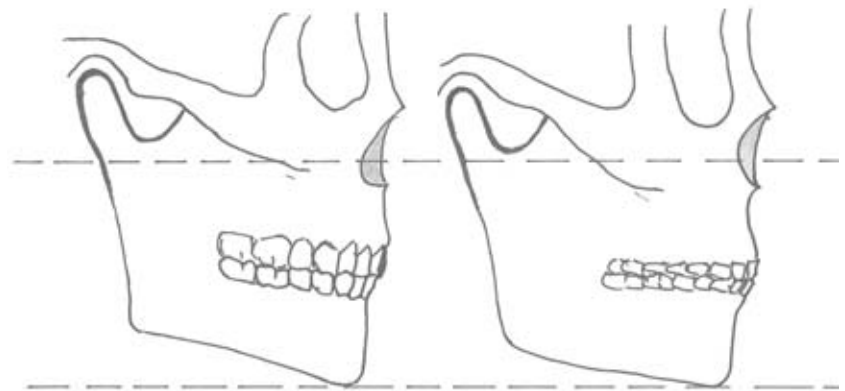


Figure 2 Based on Dawson's theory, the vertical dimension of occlusion remains largely intact even if there is a loss of tooth hard substance (right picture). Redrawing according to [8].

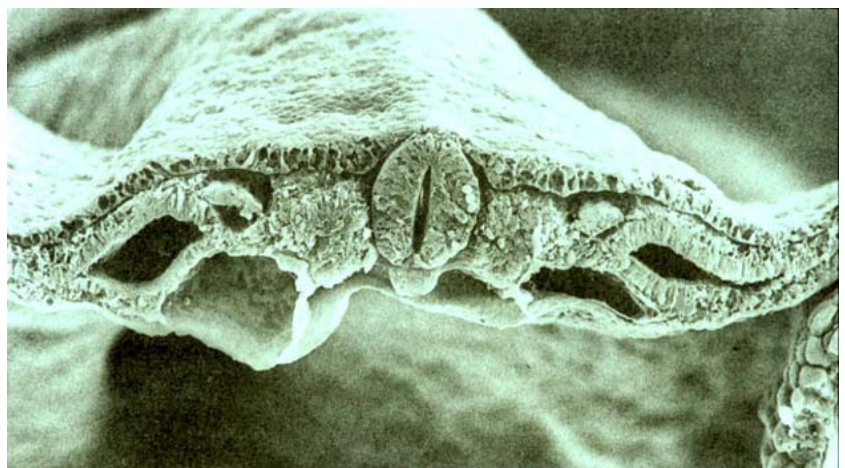


Figure 3 Cross-section of a late three-sheet germinal disc. Image taken with an electron microscope. In the middle is the closed neural tube. On both sides, the neural crests are still separated. Directly below the neural tube is the notochord [12].

Based on the observations of Begg [2] and other dental anthropologists [1, 10], “wear” of the tooth

structure must be considered as a natural and, to a certain extent, necessary phenomenon. All of the

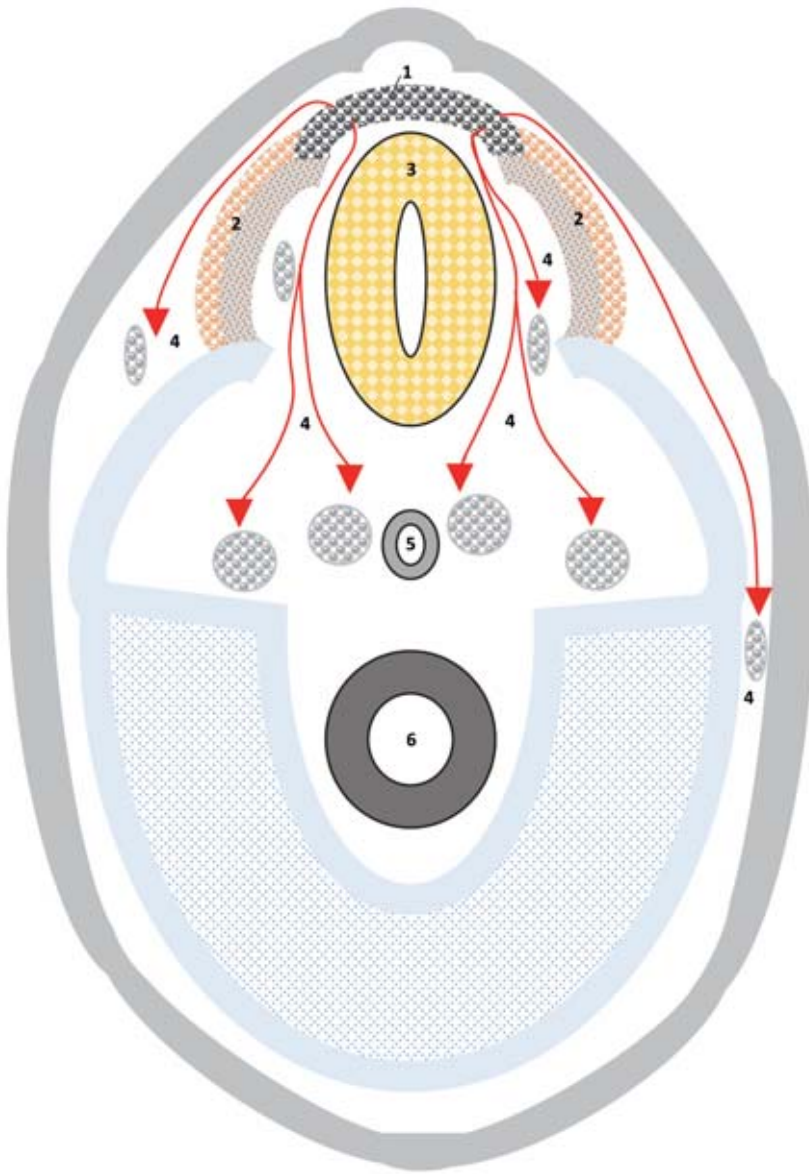


Figure 4 Migration of embryonic material (neural crest cells) during blastogenesis and embryogenesis. 1 = Definitive neural crest; 2 = Not yet united neural crests; 3 = Closed neural tube; 4 = Pathways of neural crest cells; 5: Notochord; 6: Primitive intestine; the neural crest cells have a high plasticity with regard to their differentiation possibilities according to [12].

components of the stomatognathic system can adapt through growth and resorption processes; this includes bones, periodontium, muscles, and soft tissues. It is just our teeth which are formed once and which are not adaptive; during their period of use, they can only “wear”. Structures such as bones, muscles and the periodontium react to this fact. The tooth serves as the fixed element, while the other structures serve as the flexible elements in the stomatognathic system. In this context, the current concepts for the reconstruction of a dentition that has undergone erosion must be critically considered. To begin with, many of our modern materials are much more wear-resistant than enamel. This applies especially to monolithic zirconia dioxide [4]. Reconstruction of the occlusion should not prevent the natural wear of a dentition with age. Given that wear of the tooth hard substance has slowly taken place over the years, it must be assumed that adaptive processes have largely maintained the vertical dimension of occlusion.

Statement

Abrupt increases of the bite position are to be avoided in these cases. General statements such as “5 mm bite elevations always work” are certainly not correct. From splint therapy, it is known that bite elevations can be adjusted [7, 9]. Following elevation of the bite, a floating resting position should still be present; moreover, the elevation should be planned in the centric relation of the lower jaw relative to the upper jaw in order that the increase takes place as near as possible to the pure rotational movement of the lower jaw. According to our clinical observations, reconstructions with bite elevations fail in particular when they were not made in the retruded position, but rather shifted in a sagittal direction towards an anterior position.

Whoever faces the challenge of “elevating the bite position” should thoroughly study the etiology that led to the loss of hard tooth substance in patients. The new bite position should be tested in centric relation with an occlusal bite block [3]

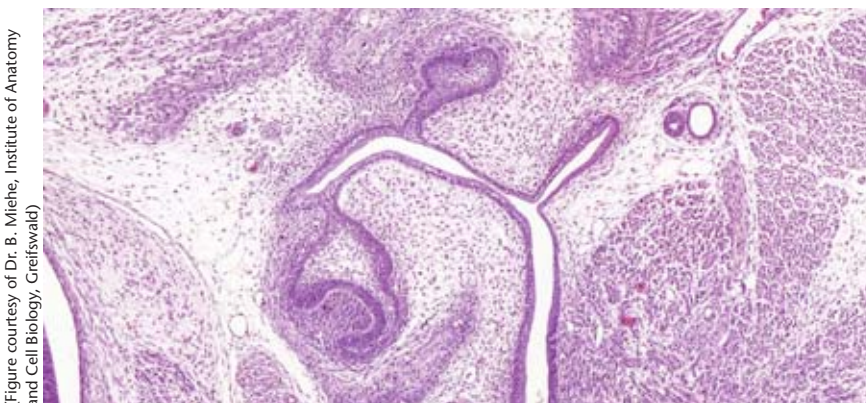


Figure 5 Tooth bell stage. Note the connection of the oral cavity epithelium to the developing tooth structure. Magnification 200x, HE staining.

(Figure courtesy of Dr. B. Miehle, Institute of Anatomy and Cell Biology, Creifswald)

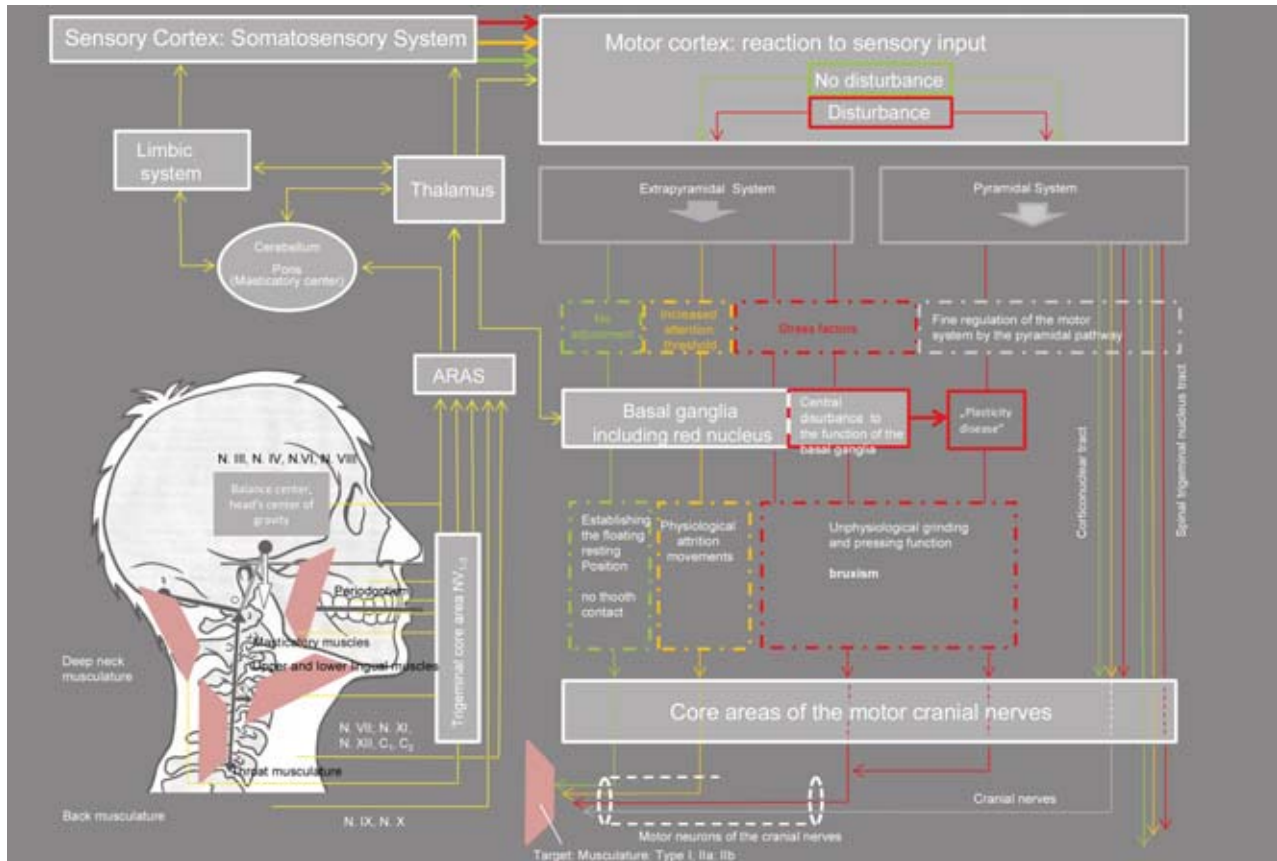


Figure 6 Principles of neuromuscular control of the masticatory muscles. See text for explanation [3]. (ARAS = Ascending Reticular Activating System)

(Fig. 7). The classical Michigan splint is the method of choice, and if necessary, bite elevation should be performed in several steps. By using a well-polished occlusal splint, worn especially during the day, but excepting mealtimes, parafunctional occlusal wear patterns can be easily identified. In cases where clear tooth wear patterns exist, elevation of the bite position is risky. This is because the wear patterns are indicative of the fact that the patient has not adapted the new bite position thus far; the selected bite position has led to (renewed) parafunctions, which can later lead to damage such as chipping of the veneering ceramic.

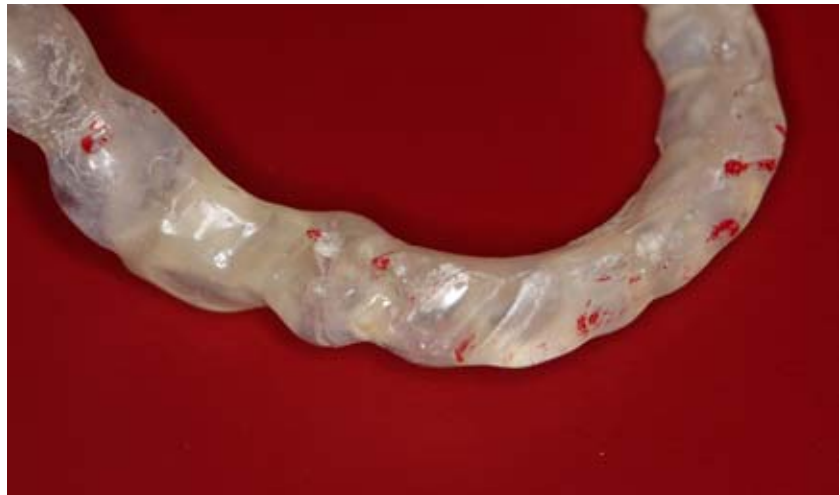

Figure 7 The occlusal surfaces of the Michigan splint showed pronounced parafunctional wear patterns after 6 weeks of wear. The existing bite position was not adapted. The appliance is fractured in the area of tooth 45.

References

1. Alt KW, Garve R, Türp JC: Ist Abnutzung der Zahnhartsubstanz ein pathologischer Prozess? Eine dentalanthropologische Perspektive. Dtsch Zahnärztl Z 2013; 68: 550–557
2. Begg PR: Stone age man's dentition. J Orthod 1954; 40: 298–312, 373–383, 462–475, 517–531
3. Behr M, Fanghänel J: Kраниоmandибулярэ Dysfunktionen. Antworten aus Fragen aus der Praxis. Thieme, Stuttgart, New York 2020
4. Behr M, Proff P, Rosentritt M: Führt die Anwendung von monolithischem Zirkoniumdioxid möglicherweise zu Funktionsstörungen? Dtsch Zahnärztl Z 2019; 74: 86–89
5. Berkovitz BK, Boyde A, Frank RM et al.: Teeth. Springer, Berlin, Heidelberg 1989
6. Berry DC, Poole DF: Attrition: Possible mechanisms of compensation. J Oral Rehabil 1976; 3: 201–206
7. Carlsson GE, Ingerval B, Kocak GI: Effects of increasing of vertical dimension on the masticatory system in subject with natural teeth. J Prothet Dent 1979; 41: 281–289
8. Dawson PE: Functional Occlusion. From TMJ to smile design. Mosby, St. Louis 2007
9. Helsing G: Functional adaptation to change in vertical dimension. J Prosthet Dent 1984; 52: 867–870
10. Kaidonis JA: Tooth wear: the view of the anthropologist. Clin Oral Invest 2008; 12 (Suppl1): S21–26
11. Schumacher GH, Schmidt H: Anatomie und Biochemie der Zähne. VEB Volk und Gesundheit, Berlin 1982
12. Schumacher GH, Fanghänel J, Persaud TVN: Teratologie. Fischer, Jena 1992
13. Türp JC: Okklusion in der Dentalanthropologie und Zahnmedizin. 4. Konferenz des AK Ethno- und Paläo-Zahnmedizin der DGZMK. J Cranio-mandib Func 2019; 11: 371–376



(Foto: UKR)

**PROF. DR. MED. DENT.
MICHAEL BEHR**

University of Regensburg
Faculty of Medicine
Franz-Josef-Strauss-Allee 11
93053 Regensburg
michael.behr@klinik.uni-regensburg.de



(Foto: UKR)

**PROF. DR. MED.
JOCHEN FANGHÄNEL**
University of Regensburg
Faculty of Medicine
Franz-Josef-Strauss-Allee 11
93053 Regensburg
jochen.fanghaenel@ukr.de



(Photo: Ingolf Riemer)

**DR. MED. DENT. M.SC.
ANGELIKA RAUCH**
Department of Dental Prosthetics and
Materials Science
University of Leipzig
Liebigstr. 12, 04103 Leipzig, Germany
angelika.rauch@medizin.uni-leipzig.de

Alice Josephine Müller, Simon Peroz, Frank Peter Strietzel

Implant-prosthetic rehabilitation using individualized allogeneic bone blocks for bone defects caused by peri-implantitis

Introduction: Implant-prosthetic rehabilitation after previous implant loss due to peri-implantitis and periodontitis is considered to be challenging and risky, as the remaining alveolar process defects are often extensive and may also affect neighboring regions. A 68-year-old female patient with advanced peri-implantitis in region 44 and a severely atrophied alveolar ridge in region 32–41 requested a new fixed implant-prosthetic restoration of the lower jaw. The patient had an inconspicuous general medical history and previous periodontitis therapy had been performed. Subsequent to explantation at site 44, pronounced horizontal and vertical defects of the alveolar ridge in region 44 to 46 and in region 32 to 41 were identified both clinically and using 3D radiographic imaging (cone-beam computed tomography, CBCT). Prior to implant planning, the status of peri-implantitis and periodontitis was re-evaluated, as there was a suspicion of residual cement-associated peri-implantitis, which could have resulted in implant loss.

Material and Methods: Two patient-specific allogeneic bone grafts were made using CAD-CAM (Maxgraft bone builder, Botiss, Zossen, Germany) and were securely introduced for bone defect reconstruction. Despite dehiscence in region 31, both transplants showed revascularization and integration after 6 months. Implant placement ensued in regions 31, 41, 44 and 46. Thereafter, a fixed implant-supported restoration could be successfully applied 3 months later.

Results: This case report demonstrates that satisfactory bone defect reconstruction, meeting both functional and esthetic criteria, is possible even subsequent to peri-implantitis, explantation and rigorous periodontal pretreatment of chronic marginal periodontitis by means of a two-staged surgical approach. A small dehiscence above the allograft did not curtail the overall result of the augmentation. Long-term studies must show the extent to which the augmentation result remains stable.

Keywords: implant-prosthetic rehabilitation; peri-implantitis; periodontitis; allogeneic grafts

Charité – Medical University Berlin, Charité Center 3 for Dental, Oral, and Maxillary Medicine, Department for Oral Medicine Dental Radiology, and Oral Surgery (Head: Univ.-Prof. Dr. Andrea-Maria Schmidt-Westhausen); Dr. Alice Josephine Müller, PD Dr. Frank-Peter Strietzel

Charité – Medical University Berlin, Charité Center for Dental, Oral, and Maxillary Medicine, Department of Prosthodontics, Geriatric Dentistry and Craniomandibular Disorders (Director and Chairman: Univ.-Prof. Dr. F. Beuer); Simon Peroz

Translation from German: Christian Miron

Citation: Müller AJ, Peroz S, Strietzel FP: Implant-prosthetic rehabilitation using individualized allogeneic bone blocks for bone defects caused by peri-implantitis. *Dtsch Zahnärztl Z Int* 2020; 2: 008–013

Peer-reviewed article: submitted: 12.07.2019, revised version accepted: 30.10.2019

DOI.org/10.3238/dzz-int.2020.0008–0013

Introduction

Implant-prosthetic rehabilitation of extended horizontal and vertical bone defects due to previous peri-implantitis in conjunction with explantation is considered to be challenging. Often, crater-shaped peri-implant bone defects are extensive and they can additionally affect neighboring regions. Their specific and highly individual geometry makes the selection of a suitable augmentation procedure for reconstruction difficult. Currently, the reconstruction of pronounced alveolar process defects with autologous bone grafts is the gold standard. The high degree of difficulty associated with this surgical procedure together with donor site morbidity and the longer duration of the operation are fueling the desire to find alternative methods: one possibility is the use of custom-made allografts.

Case report

Patient presentation: A 68-year-old female patient with an inconspicuous general medical history presented herself to the Department of Oral Medicine, Dental Radiology and Surgery at the Charité Center for Dental, Oral, and Maxillary Medicine of the Charité-Medical University in Berlin with the wish for a new fixed prosthetic, or more specifically, implant-prosthetic restoration. Preliminary examinations had already been carried out by several dentists; the patient was repeatedly shown that the implant 44 and the tooth 45 were not worth preserving and that a new fixed implant-prosthetic restoration was not possible due to the pronounced bone defects in the lower jaw. Nevertheless, the patient had a

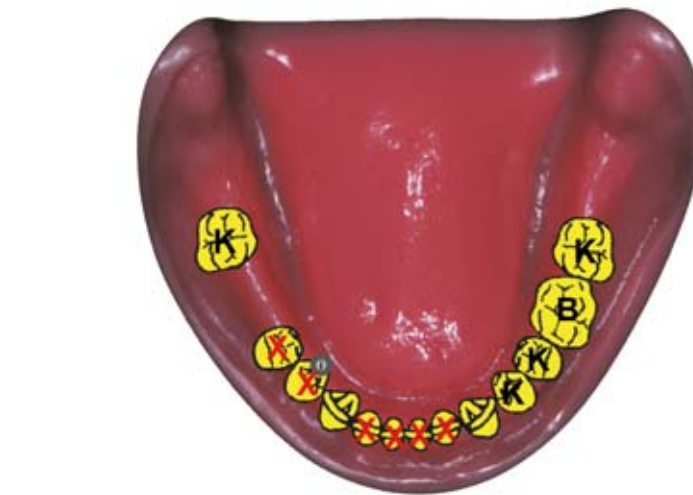


Figure 1 Initial situation

strong desire to be treated with a fixed restoration (Fig. 1 initial situation).

Additional findings

In the lower jaw, it was revealed that teeth 32–42 were not worth preserving due to an advanced marginal periodontitis and that teeth 43 and 33 required crowns owing to pronounced abrasion. Due to chipped ceramic veneering and insufficient crown margins, the crowns on teeth 34 and 47 were in need of renewal, as was the bridge on teeth 35 to 37. Additionally, all crowns in the maxilla were found to be in need of renewal due to insufficient crown margins (teeth 15–25, 27 and implants 17, 16 and 26). The implants showed incipient horizontal bone loss and the endodontic treatment of tooth 21 needed revision due to over-pressed root canal filling material. Although

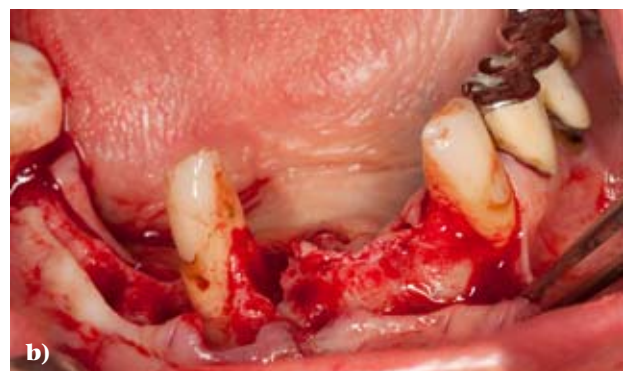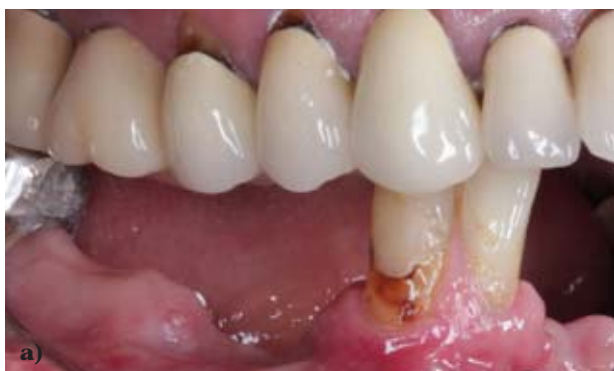the teeth displayed no apical lesions, cervical bone loss was evident.

Therapeutic alternatives

Alternatively, a removable denture could have been made for the lower jaw. To achieve this, a telescopic bridge/removable denture or a partial cast denture anchored by means of clasps could have been plausible. A fixed restoration was only possible using implants in this case.

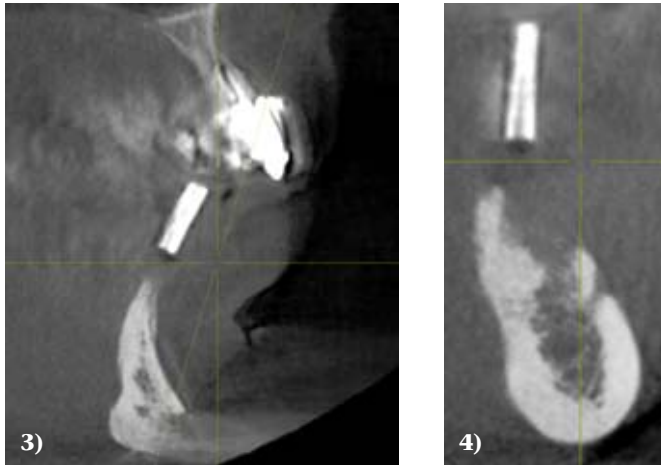
Treatment

First, the explantation of 44 and the extraction of tooth 45 was performed. The ensuing partial edentulous dentition was treated with a periodontally-supported temporary splint. After the wound healing phase was complete, a 3D X-ray using radiopaque reference markers (X-ray template with titanium sleeves [10 mm long] in the regions 46, 44, 32, 41 ac-



(Fig. 2a: S. Peroz, fig. 2b: A.J. Müller)

Figure 2a Clinical condition regio 32 and regio 44/45, **2b** intraoperative condition after flap formation



Figures 3 und 4 CBCT imaging in region 32 und region 44/45 (Galileos, Dentsply Sirona, Bensheim, Germany)

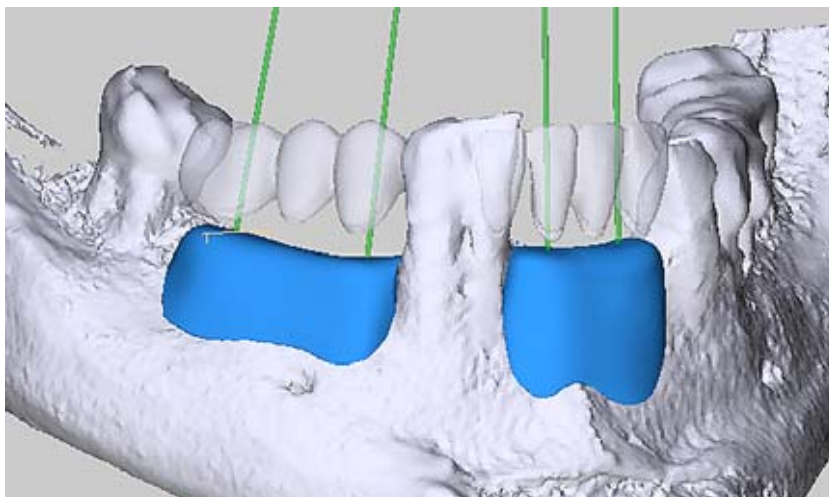
cording to the previously prepared diagnostic model of the missing teeth) was made. CBCT imaging revealed pronounced horizontal and vertical alveolar process defects in these regions, which at first excluded implantation and necessitated a multi-step approach (Fig. 3 and 4). In addition, the commonly used intraoral donor sites for autologous grafts were considered to be dimensionally too small. The use of autologous bone grafts was therefore eliminated as a treatment alternative. The suggestion of augmentation using patient-specific allogeneic bone blocks ensued (Maxgraft Bone Builder, Botiss, Zossen, Germany). The patient was fully informed with regard to other existing treatment options (in-

cluding iliac crest grafting and the use of bone substitute material in particulate form as part of a controlled bone regeneration with the creation of a compartment) with the associated benefits and risks as well as the expected costs. Maxgraft Bone Builder are custom-made allogeneic transplants that are prepared preoperatively by means of digital three-dimensional planning (SMOP, Swissmeda AG, Baar, Switzerland) and match the patient's bone defect site (Fig. 1). They are obtained from the Cells+Tissuebank Austria (tissue bank) from the femoral heads of living donors and processed in several steps. They undergo various antigen and serological tests to exclude the transmission of infections. The bone

blocks are prepared by means of ultrasonic baths (cleaning from blood, cell and tissue components), diethyl ether and ethanol rinsing (denaturation of non-collagen protein and pathogens), oxidative treatment (elimination of potential antigens), lyophilization (preservation of structure and residual moisture) and final gamma radiation (sterilization and preservation). Through this manufacturing process, the open porous cancellous bone structure is preserved with a pore size of 100–1800 μm (data according to the manufacturer) [5, 10].

For the patient, 2 patient-specific allografts were prepared using the method described above. Following cortical conditioning at the recipient sites and after rehydration of the grafts using autogenous plasma fraction enriched with growth factors (PRGF Endoret Phase 2, BTI, Karlsruhe, Germany), the 2 grafts were fixed with 2 osteosynthesis screws (Minischrauben, Straumann, Freiburg, Germany) (Figs. 6 and 7), each of which was inserted from vestibular. Subsequent to the mobilization of each respective vestibular mucosal periosteal flap and the covering of the transplants with fibrin membrane (PRGF Endoret, Phase 1, BTI, Karlsruhe, Germany), tension-free, primary wound closure ensued. During the healing phase of the grafts, the patient wore the adapted periodontally-supported temporary splint as much as possible in order to protect the augmented sites from mechanical stress. In addition, systemic antibiotic prophylactic therapy (amoxicillin) was administered perioperatively for 7 days (2 g amoxicillin beginning one hour preoperatively, then 1 g every 8 hours). The wound healing proceeded without complications and, according to the patient, was almost painless. Monthly controls of the augmentation area were performed. Shortly before the end of the 6-month healing phase, a small dehiscence was observed in region 31. The surrounding tissues were free of any irritation.

Before planning the subsequent implantation, a radiographic re-evaluation of the augmented bone was made. An increase in vertical and

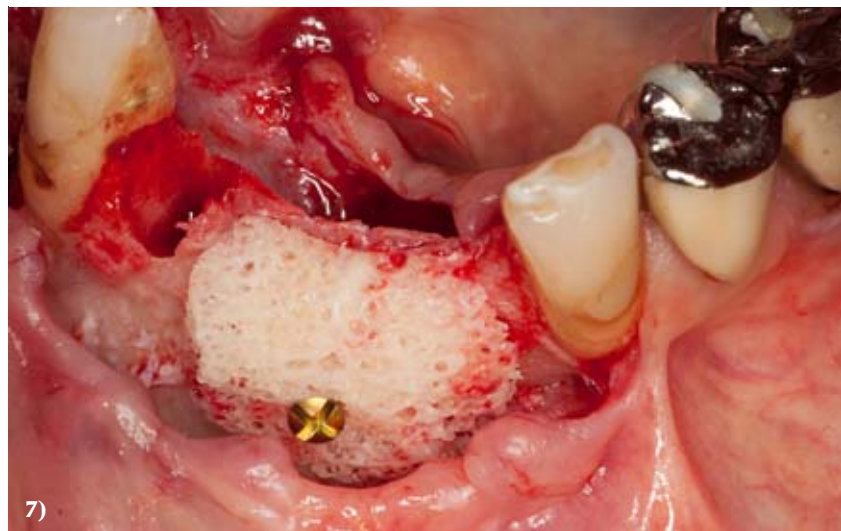
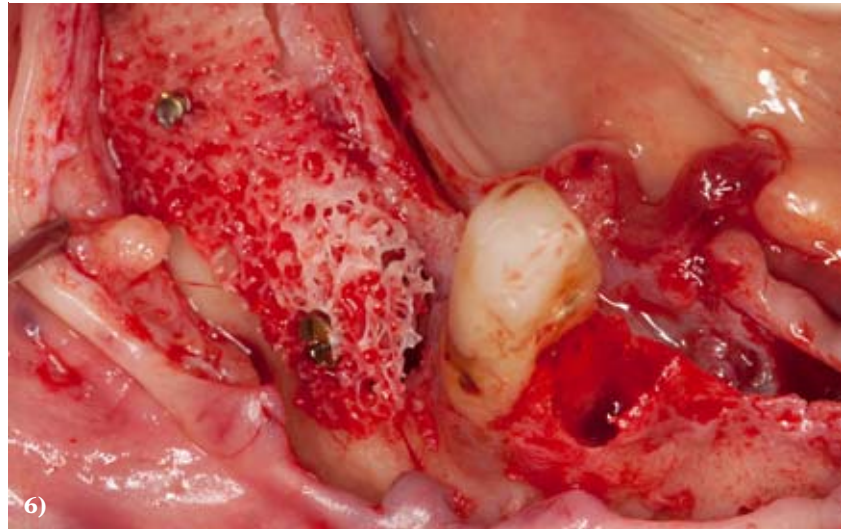


(Fig. 5: Christin Hohmann, Botiss biomaterials GmbH, Zossen)

Figure 5 3-D planning from the company Botiss (Straumann, Freiburg, Deutschland) mit SMOP (Swissmeda AG, Baar, Schweiz)

transversal bone supply for implantation was seen in both clinical and radiographic examinations. Implant planning was carried out after calibration of the PSA using 10 mm long divisible X-ray, or more specifically, drill sleeves and measurement of the regions 32, 41, 44 and 46 that were to receive implants.

The osteosynthesis screws were removed immediately before placing the implants. In the area of the osteosynthesis screws, the allografts displayed a resorption of approximately 1.5 mm (Fig. 8) in the horizontal dimension. Both grafts underwent osseointegration and vascularization. The implants of type Astra EV (Dentsply, Sirona, Bensheim, Germany) were inserted as planned in regions 32, 41, 44 and 46 (Figs. 9 and 10). Furthermore, controlled bone regeneration using bovine bone graft substitutes (Bio Oss, Geistlich Biomaterials, Waldenburg, Switzerland) and a porcine collagen membrane cover (Bio Gide, Geistlich Biomaterials, Waldenburg, Switzerland) were used to protect against resorption and to cover the vestibular implant shoulder in regions 41, 44 and 46. Here too, an accompanying systemic antibiotic therapy with amoxicillin was also administered. Wound healing took place free of any complications. After another 3 months, the implants were exposed and additional vestibuloplasty was performed in regions 32 to 42 and 44 to 46; the multiple augmentations with the associated mobilization of the mucosa had shifted the mucogingival border crestally. By means of vestibuloplasty, a sufficiently wide zone of keratinized gingiva in the area of the implants could once again be restored. Three weeks following the operation, old restorations were removed and the teeth 37, 35, 33, 43 were prepared; the subsequent impression with simultaneous bite registration and face bow application took place. A set-up for trial fitting as well as the custom-milled titanium abutments was fabricated in the dental laboratory (Zahntechnik Mehlhorn, Berlin). Minor chair-side esthetic and functional corrections were made. All bridges and crowns in the lower jaw were made of zirconia with individ-



Figures 6 und 7 Intraoperative situation after fixation of the patient-specific allografts (Maxgraft Bone Builder®, Botiss, Zossen, Deutschland)

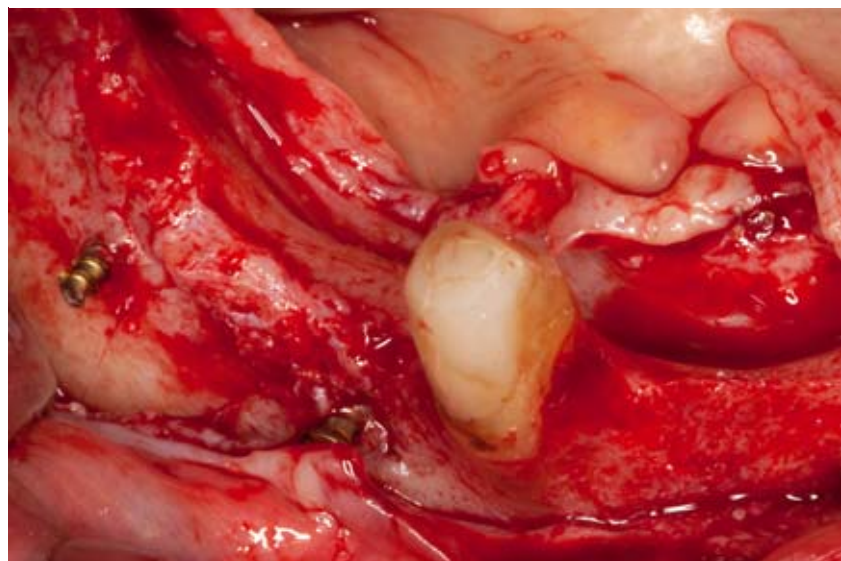
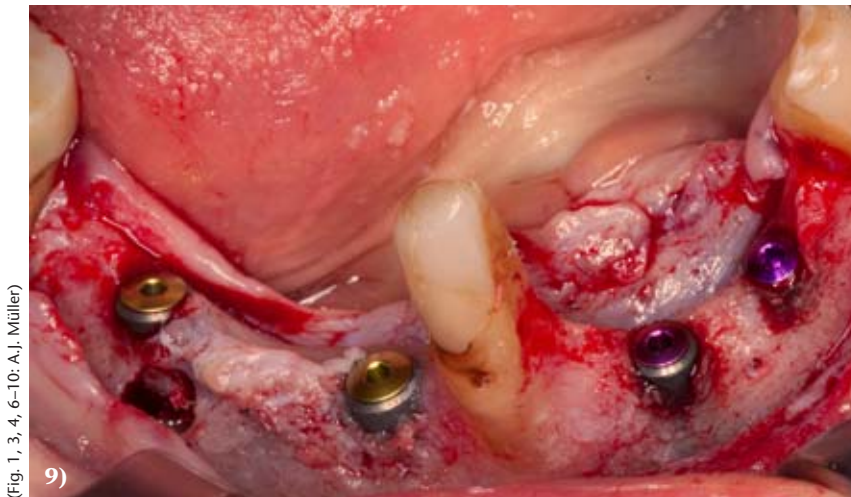
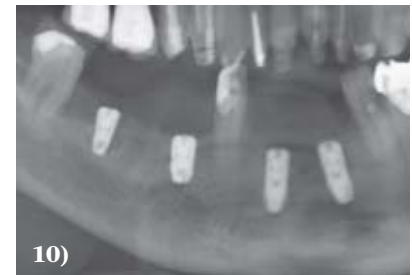

Figure 8 Status after the 6-month healing phase, approx. 1.5 mm resorption is noticeable in the area of the screw heads



(Fig. 1, 3, 4, 6-10: A.J. Müller)



Figures 9 und 10 Status after the removal of the osteosynthesis screws and implant insertion in regions 32, 41, 44, 46, "subsequent augmentation" in region 41, 44 and 46.

ualized ceramic veneering. All tooth-supported crowns and bridges were permanently cemented (Ketac Cem, 3M, Neuss, Germany), while all implant-supported bridges were semi-permanently cemented (Improv, Dentegris, Monheim am Rhein, Germany) (Fig. 11 and 12). At the time when rehabilitation of the mandible was complete, the maxillary teeth were still treated with PMMA-milled long-term provisionals.

Follow-up

The first check-up took place 3 months after the prosthetic treatment and normal peri-implant tissue was seen.

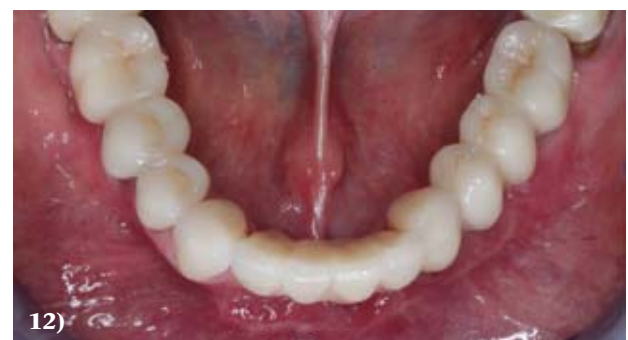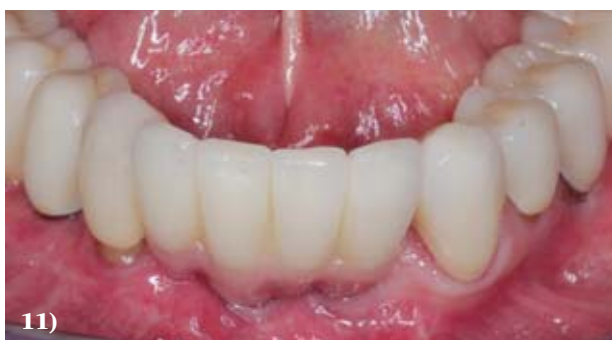Discussion and Epicrisis

In cases of extensive alveolar ridge defects, advanced patient age and multiple revision treatments, the limits are reached for obtaining autologous bone grafts from intraoral donor regions for the purpose of treating affected regions. Iliac crest

transplantation, which is the alternative, deters many patients and is associated with a certain morbidity following bone removal [12] as well as an inpatient stay.

In an intraoperative context, CAD/CAM ("computer-aided design" and "computer-aided manufacturing") milled patient-specific bone blocks (Maxgraft Bone Builder) offer the advantage of a relatively short operation time due to the accurate fit of the grafts. The large contact area between the graft and donor site facilitates exchange at the interface to occur, as well as revascularization and osseointegration by continuous substitution of the augmentation with own bone [2]. The chosen volume of the patient-specific allogeneic bone block is not allowed to be too large, so that revascularization at the surface and the remodeling process are ensured [3]. Also, the thickness of the covering mucosa is decisive for the success of the augmentation; with this in mind, the maxilla is theoretic-

cally, with an average mucosa thickness of 3 to 6 mm, more suitable than the mandible for transplant use; this is because a proportionally thicker mucosal membrane facilitates both tension-free wound closure as well as nourishment of the periosteal mucosa flap [11]. For a long time, there have been varied opinions regarding the potential risk of disease transmission from donor to recipient through the use of allografts; however, since the introduction of DNA-based blood tests as well as the preparation of the grafts by solvent dehydrogenation, oxidative treatment and gamma irradiation, no cases of disease transmission from donor to recipient have been demonstrated [4]. Moreover, the issue of antigenicity to the human leukocyte antigen (HLA) is also driven into the background by the multi-step processing techniques of allogeneic bone grafts, which are used nowadays. To date, antigenicity has been observed especially in connection to cryopreservation [7, 8]



(Fig. 11 und 12: S. Peroz)

Figures 11 und 12 Status after completion of implant-prosthetic treatment

and freshly frozen allografts [9]. A detailed explanation of the type, origin and characteristics of the intended bone substitute material is required in each case [1]. When comparing autologous and allogeneic grafts, Kloss et al. found similar resorption rates after a 12-months observation period based on radiographic controls [6]. This can, like in the course of the present treatment, make an additional augmentation necessary afterwards; however, the augmentation can nonetheless be performed concomitantly with implant placement.

Especially in the production of a prosthesis fixed on implants, red-white esthetics plays a major role and this can only be achieved satis-

factorily if defect reconstruction also takes place in the vertical direction. In the present case, this was fully achieved only in regions 44 to 46; in regions 32 to 42, additional pink ceramic needed to be used to compensate for the missing gingival height.

Conclusion

In overview of all factors, allogeneic patient-specific bone blocks represent an alternative to autologous bone blocks or the shell technique for the reconstruction of alveolar process defects. By means of digital planning and diagnostics using CBCT, possible augmentation procedures can be evaluated and discussed with the patient together. The lower morbidity and shorter operation time (given

that bone harvesting and adaptation of autologous bone blocks are not necessary) are important arguments in selecting a suitable augmentation technique. Long-term follow-up studies must show the extent to which the augmentation results remain stable and how the retention rates of the implants in a reconstructed implant-bearing tissue of this type develop.

Conflicts of interest:

The authors declare that there is no conflict of interest within the meaning of the guidelines of the International Committee of Medical Journal Editors.

References

1. Benz K, Buchbinder B, Strietzel FP, Fehn BJ, Jackowski J: Allografts und Aufklärung – Schutz für Patienten und Behandler. *Quintessenz Zahnmedizin* 2019; 70: 8
2. Burchardt H: The biology of bone graft repair. *Clin Orthop Relat Res* 1983; 174: 28–42
3. Fretwurst T, Spanou A, Nelson K, Wein M, Steinberg T, Stricker A: Comparison of four different allogeneic bone grafts for alveolar ridge reconstruction: a preliminary histologic and biochemical analysis. *Oral Surg Oral Med Oral Pathol Oral Radiol* 2014; 118: 424–431
4. Hinsenkamp M, Muylle L, Eastlund T, Fehily D, Noel L, Strong DM: Adverse reactions and events related to musculoskeletal allografts: reviewed by the World Health Organisation Project NOTIFY. *Int Orthop* 2012; 36: 633–641
5. www.botiss-dental.com/de/products/maxgraft-bonebuilder-de/
6. Kloss FR, Offermanns V, Kloss-Brandstatter A: Comparison of allogeneic and autogenous bone grafts for augmen-
7. Mosconi G, Baraldi O, Fantinati C et al.: [Anti-HLA antibodies after bone graft and their impact on kidney transplant programs]. *G Ital Nefrol* 2009; 26 (Suppl 45): S58–63
8. Mosconi G, Baraldi O, Fantinati C et al.: Donor-specific anti-HLA antibodies after bone-graft transplantation. Impact on a subsequent renal transplantation: a case report. *Transplant Proc* 2009; 41: 1138–1141
9. O'Sullivan ED, Battle RK, Zahra S, Keating JF, Marson LP, Turner DM: All sensitization following bone graft. *Am J Transplant* 2017; 17: 2207–2211
10. Pecanov-Schröder A: Allogene Transplantate – sicher wie Arzneimittel. *Implantologie Journal* 2017; 12: 4
11. Plöger M: Autologe Blocktransplantate bei Hypodontie lateraler Inzisivi. *Implantologie Journal* 2019; 5: 8
12. Sudhakar KNV, Mohanty R, Singh V: Evaluation of donor site morbidity associated with iliac crest bone harvest in oral and maxillofacial, reconstructive surgery. *J Clin Diagn Res* 2017; 11: ZC28–ZC33



(Photo: Elmar Wurster, Charité Berlin)

DR. ALICE MÜLLER
Charité – Medical University Berlin,
Charité Center 3 Dental, Oral and
Maxillofacial Surgery
Division of Oral medicine, Dental
Radiology and Surgery
Alßmannshäuser Str. 4-6
14197 Berlin
alice.mueller@charite.de

Christian Splieth, Ibraheem Hatout, Johanna Splieth, Julian Schmoeckel, Mhd Said Mourad, Mohammad Alkilzy

Use, attitudes, side effects and satisfaction with nitrous oxide sedation for dental treatment in Germany

Introduction: The use of nitrous oxide for minimal sedation in dentistry is only recently advocated by European and German associations, but its use in dental practice routine is hardly examined. Thus, the aim of this study is to evaluate the circumstances of nitrous oxide sedation in German dental practices.

Materials and methods: A questionnaire on the knowledge and attitudes of general dentists towards nitrous oxide sedation was sent to a representative sample of 100 dentists from the lists of the dental associations. A second questionnaire for 210 dentists who had purchased the according equipment covered domains of the user profile, indications, equipment and techniques and the procedure of their last nitrous oxide sedation.

Results: In general, German dentists exhibit a neutral (57 %) or positive attitude (29 %) towards minimal sedation with nitrous oxide (response rate 14 %). Due to the recent purchase of the devices, the years of experience of users were mostly low (only 16 % > 3 years, response rate 30 %) with varying levels of formal training. Still, the equipment, techniques and outcomes were in line with established recommendations. Mainly adults (62 %) with anxiety (87 %) were treated with surgical procedures (59 %) with a very high success rate and few minor side effects such as euphoria (5 %), sweating, nausea or vomiting (3 % each).

Conclusion: The responding dentists and patients were highly satisfied and saw nitrous oxide as an easy and predictable way to achieve minimal sedation during dental treatment, sometimes preventing a referral to general anesthesia. Thus, there is a potential that nitrous oxide could be as widely used in Germany as it is in other countries.

Keywords: dentistry; nitrous oxide; paediatric dentistry; sedation

Preventive & Pediatric Dentistry University of Greifswald, Walther-Rathenau-Str. 42a, 17475 Greifswald; Prof. Dr. Christian Splieth, Johanna Splieth, Dr. Julian Schmoeckel, Mhd Said Mourad, Mohammad Alkilzy

Pediatric Dentistry, Practice Dr. Derin, Boulaaouin Dentists, Zeil 65, 60313 Frankfurt am Main; Ibraheem Hatout

Citation: Splieth CH, Hatout I, Splieth J, Schmoeckel J, Mourad MS, Alkilzy M: Use, attitudes, side effects and satisfaction with nitrous oxide sedation for dental treatment in Germany. *Dtsch Zahnärztl Z Int* 2020; 2: 014–020

Peer-reviewed article: submitted: 22.07.2019, revised version accepted: 14.10.2019

DOI.org/10.3238/dzz-int.2020.0014–0020

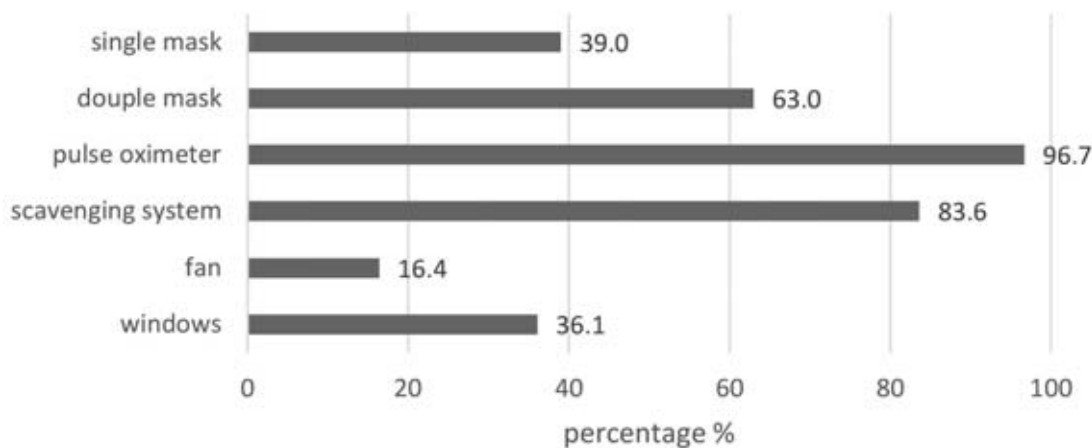


Figure 1 Use of equipment for application, monitoring and ventilation during sedation with nitrous oxide in German dental practices (multiple answers were possible)

1. Introduction

Nitrous oxide sedation is an old and established technique for the reduction of stress and anxiety during dental treatment [1]. According to the Council of European Dentists [20], the European Academy of Paediatric Dentistry [11] and a consensus paper by German anesthesiologists and German dentists [21], the use of nitrous oxide has recently been encouraged for minimal sedation in dental treatment.

However, there are only a few studies from continental Europe about how nitrous oxide is applied in dentistry [9, 12]. A study conducted in France with nitrous oxide as 50:50 premix with oxygen evaluated the treatment in 549 patients with intellectual disability, pre-cooperative children, adults or children with dental phobia and patients requiring a single complex dental treatment [12]. The dental procedures such as extractions, fillings, endodontics, surgery, scaling and impression were performed with a very high success rate (93.7 %) under nitrous oxide sedation. In 12.6 % of the sample, mild side effects were registered; mostly euphoria (3.5 %), nausea or vomiting (2.8 %). However, the French study used a system where no titration was possible due to the 50:50 premix, which could be a reason for higher complication rates.

Other studies showed that conscious sedation with nitrous oxide improved the cooperation during

dental care for patients with behavioral difficulties such as very young children, patients with dental anxiety or phobia, and persons with intellectual disability [3, 9].

In Germany, as in many other countries, there is no comparable, published data about the use of sedation with nitrous oxide in dental practice or the views of the dentists about this technique. Studies on this topic can lead to a better implementation of nitrous oxide sedation and improve the training of current and future dentists. Thus, the aim of this study is to evaluate the following questions in a representative sample of German general dentists and dentists who had purchased nitrous oxide equipment:

- How high is the number of anxious patients in dental practices in Germany who could benefit from minimal sedation with nitrous oxide?
- How high is the number of general dental practitioners who are willing to use nitrous oxide in their practices?
- What are the reasons for not using nitrous oxide?
- What are the indications for nitrous oxide in dental treatment according to German dentists?
- What side effects of nitrous oxide did the users encounter and how often?
- How high is the failure rate of nitrous oxide in terms of both dental treatment and sedation?

- How is the satisfaction level of German dentists with nitrous oxide devices?
- How many dentists have the suitable equipment and have suitable space for applying nitrous oxide?
- In how many patients could the higher risk and cost of dental treatment under general anesthesia possibly be avoided with the help of nitrous oxide?
- What safety standards are applied when using nitrous oxide in the dental offices in Germany?

2. Materials and Methods

After approval by the Ethics Committee at the University of Greifswald, a first questionnaire was sent to 210 dentists who had purchased a nitrous oxide machine from the 3 main distributors in Germany (70 dentists each). The questionnaire covered domains of the user profile (time since graduation, years of experience with nitrous oxide), their attitudes towards nitrous oxide sedation, indications and referral patterns, frequency of application, equipment (type of sedation machine, use of pulse oximeter, ventilation system, type of masks), formal training (duration) and the techniques employed (titration, maximum concentration). In addition, for the procedure of the last treatment performed under sedation with nitrous oxide, patient characteristics (age, indication, dental procedure, duration), success rates (sedation, dental procedure), satisfaction

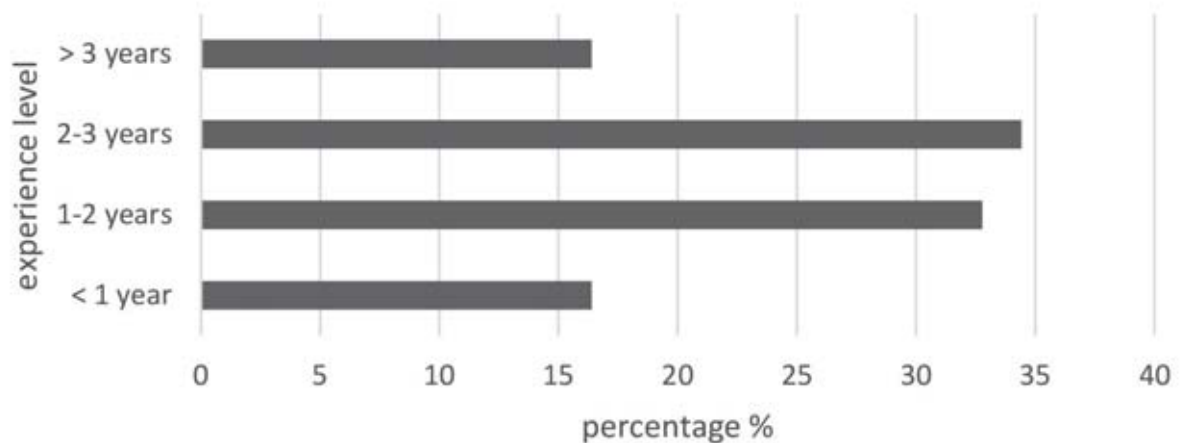


Figure 2 Years of experience in the use of nitrous oxide sedation in German dentists

by dentist and patient, next treatment options as well as complications and side effects were analysed. Data were recorded anonymously.

A second questionnaire on the knowledge and the attitudes of general dentists towards nitrous oxide sedation for dental treatment was sent to a representative sample of 100 dentists whose addresses were collected from the public internet pages of the 17 regional dental associations according to the relative size of the region. These data were also collected anonymously and contained information on their source of information on nitrous oxide sedation, their view on possible indications and a referral as well as past and future use of nitrous oxide sedation.

The descriptive analysis of data included ranges, frequency distributions and mean values. Analytical statistics are aiming at the different profiles of users and use of sedation with nitrous oxide, differences in use by general dentists, oral surgeons and pediatric dentists. Also patterns for side effects and complications during sedation were analyzed.

3. Results

3.1 Use of nitrous oxide in Germany

Sixty-one dentists who had purchased a nitrous oxide device returned the questionnaire (response rate 30.5 %). The systems for treatment with nitrous oxide that the 3 com-

panies provided were "Acutron" (41 %), "Tecno-Gaz" (39 %), "Matrix" (13 %) and "Porter" (7 %).

The vast majority (83.6 %, Fig. 1) of the dentists had an extra suction system to evacuate the nitrous oxide, whereas 36.1 % of the dentists just open the window to reduce nitrous oxide concentrations. Few dentists used a fan (16.4 %) and 4.9 % employed other methods for ventilation (multiple answers were possible).

The use of a pulse oximeter in order to monitor heart frequency and oxygen saturation levels in the blood was an established standard (96.7 %). About two thirds used double masks for application (63.9 %) and 39.3 % used simple masks.

There was an unanimous consent that the prime indication for nitrous oxide sedation are patients with anxiety or phobia (95 %), while 49 % of the users also saw an indication for patients with complex treatment. Fewer dentists would use it for uncooperative children under 5 years of age or with mentally handicapped patients (20 % and 18 %, resp.). While half of the dentists applied nitrous oxide on patients without a relevant systemic disease only (46 %), the other half, used it on patients with medical conditions that were compensated or well controlled (53 %). Only one dentist used it also on patients with complex medical conditions.

Very few dentists applied nitrous oxide for dental treatment more than once per day 3.3 %, while most of

them used it once per week (42.6 %) or once per month (41.0 %). 13.1 % reported a daily use.

The vast majority of dentists using nitrous oxide equipment (68 %) were completely satisfied with their devices. Twenty-eight percent of users were satisfied and only few dentists (3 %) were neither satisfied nor unsatisfied. No dentist that had purchased a nitrous oxide machine was unsatisfied or completely unsatisfied.

3.2 Experience levels and training

Fifty-four percent of the dentists had graduated from 1991 to 2000 and about equal numbers graduated before 1990 and from 2001 to 2010 (21 % and 23 %, resp.). Only one dentist had experienced training in nitrous oxide sedation during his undergraduate curriculum (1.6 %). The majority of the dentists who used nitrous oxide in their offices had taken part in training courses for 2 days (67 %), 15 % for less than 2 days and 18 % for more than 2 days.

Regarding the dentists' experience with nitrous oxide almost all dentists were using nitrous oxide sedation for less than 3 years (Fig. 2).

3.3 Report on patient treatment

The vast majority of patients treated with nitrous oxide during the last appointment were adults (62.2 %, Fig. 3), less than 20 % were children below the age of 10 years.

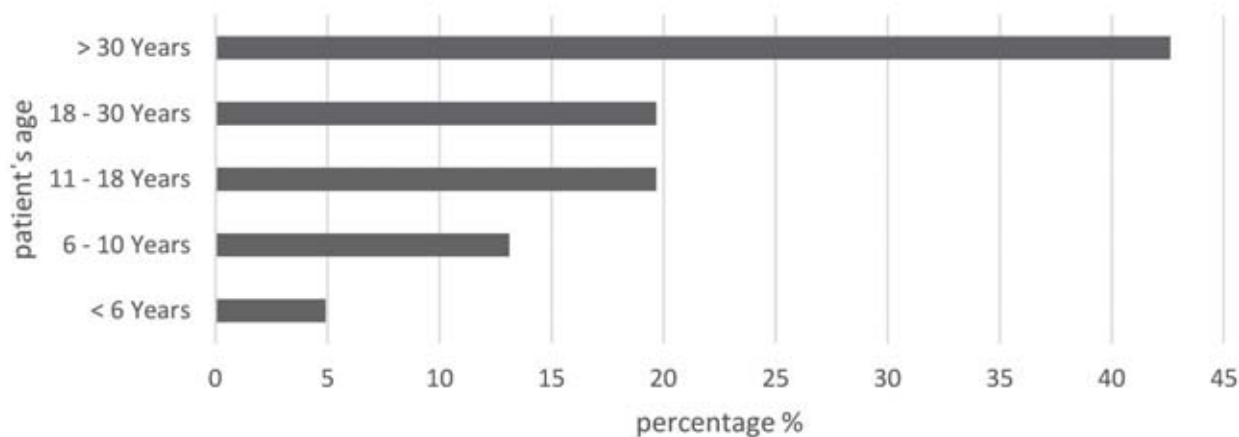


Figure 3 Age categories for patients treated with nitrous oxide sedation in German practices

The patients were mostly characterized by fear or phobia (87 %), a few were uncooperative children under the age of 5 years (7 %), mentally handicapped (5 %) or in need of complicated treatment (8 %).

The dental treatment performed under minimal sedation with nitrous oxide reflected the whole spectrum of dentistry with a clear focus on extractions (32.9 %) and fillings (30.4 %, Fig. 4).

The maximum concentration of nitrous oxide applied for the last patient was mostly 30–40 % (48 %) followed by 40–50 % (33 %). A minority had used a low concentration of 20–30 % (20 %).

The treatment time was mostly 30 to 60 min (44 %) or even shorter (30 %: 15–30 min, 7 %: less than 15 min). Few procedures lasted more than 60 min (20 %).

Titration time was mostly rather short with 69 % of the users reaching the maximum concentrations of nitrous oxide in up to 5 min. Just 3 % started with the maximum concentration right away, while 28 % need more than 5 min to titrate to the maximum concentration.

Eighty-four percent (84 %) of the cases with nitrous oxide sedation showed no complication. The complications that the dentists observed were of minor severity: 5 % experienced euphoria during treatment, in 2 % of the cases patients had restlessness, 3 % each exhibited sweating, nausea or vomiting. In another 8 % of the cases, patients had other kinds

of complications (multiple answers were possible).

The success rate for both dental treatment and minimal sedation with nitrous oxide was 100 % for the patients the dentists had treated last. The patients were also highly satisfied being treated with nitrous oxide, from the dentists' point of view (98 %). Only one dentist reported that the patient was dissatisfied with the treatment. 90 % of the dentists and even 98 % of the patients opted for performing the next dental treatment again with nitrous oxide as minimal sedation.

3.4 View of general dentists on nitrous oxide

The questionnaires were returned by the general dentists selected from the dental registers at a rate of 14 %. All general dentists who responded to the questionnaire knew about the use of nitrous oxide in dentistry. The majority of them (70 %) read about it either in newspapers or in magazines, 53 % knew about it via conferences, 39 % via the internet and only very few via television. However, only a small number of dentists had already used nitrous oxide themselves (17 %).

The majority (57 %) of the responding general dentists reported a neutral attitude towards nitrous oxide and the other third thought of it as a positive method. In consequence, 36 % of the responding dentists were undecided about using nitrous oxide in the future, 21 %

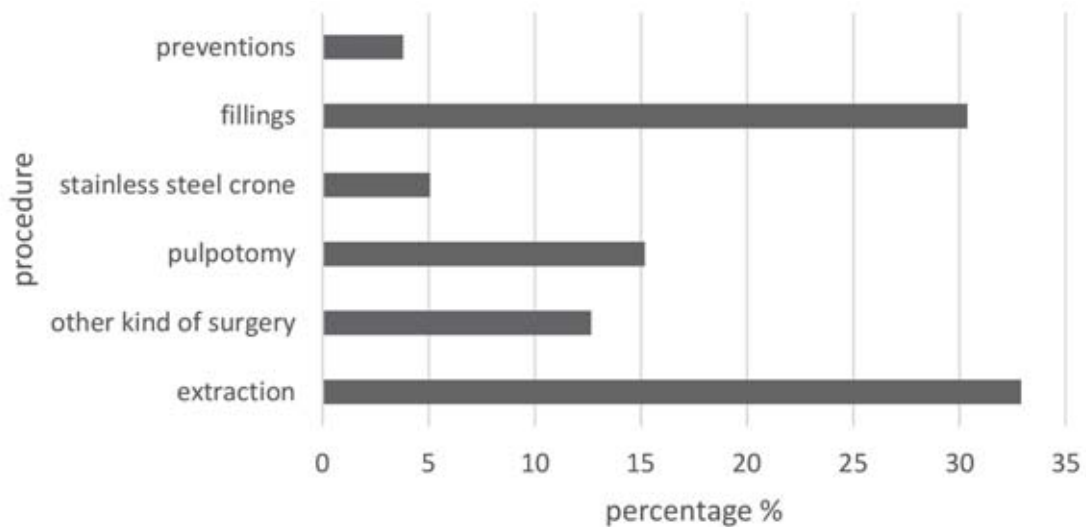
were willing to use this technique themselves, whereas one third declined this.

In contrast to the large majority (71 %) of the general dentists who refer patients to treatment under general anesthesia, they rejected a referral to another dentist for dental treatment under minimal sedation with nitrous oxide almost unanimously (91 %). As a consequence of negligible inclination to employ nitrous oxide sedation themselves or via a referral, most general dentists performed treatment in uncooperative children under 5 years of age (83 %), patients with a mental handicap (75 %) or anxiety (83 %). On the other hand, the general dentists saw exactly these patients being suited for treatment under nitrous oxide.

4. Discussion

As there was no published data on the use of nitrous oxide in dental practice in Germany, this study allowed a look into this technique which has been revived by the European and German recommendations [20, 21].

The cooperation of the suppliers of nitrous oxide equipment and the randomized collection of German dental registers allowed to select 2 representative samples of general dentists and purchasers of sedation equipment for the first study on the attitudes and use of minimal sedation with nitrous oxide in Germany. As it was a self-report questionnaire, there could be a recall bias



(Fig. 1–4: Authors)

Figure 4 Dental procedures with nitrous oxide sedation in German practices

and a selection bias of dentists, especially in the sample of the general dentists where the response rate was just 14 %. On the other hand, professional questionnaires very often result in low response rates which does not automatically create a non-responder bias [17]. There could be a tendency that especially the questionnaire for general practitioners was answered by dentists who were more in favor or familiar with the nitrous oxide sedation. Dentists without any interest or knowledge could have refrained from answering. Thus, the views and knowledge could be slightly too optimistic compared to all dentists. In contrast to this, the users of nitrous oxide equipment responded at a higher percentage (30 %) and very consistently. Due to the selection by purchasing lists, the long-term users and pioneers of nitrous oxide in Germany who mostly bought their equipment directly from foreign companies would be excluded resulting in a sample of users with reduced years of experience.

4.1 Application standards and training

The application of any health-related technique is judged by its outcome, such as the feasibility of its application, side effects, safety standards, environmental impact and the satisfaction level of its user and the patient. Nitrous oxide sedation has

proven to satisfy high standards [1, 5, 11], but its proper application needs skilled handling and suitable equipment. This includes sufficient monitoring of the patient with a pulse oximeter and ventilation which the German dentists fulfilled mostly with additional scavenging systems, but also ventilators or opening the window. Overall, there was good awareness about the safe use of nitrous oxide sedation, as long and chronic exposure might cause unwanted health effects [16, 18, 24]. The mode of usage of nitrous oxide reported by the German dentists minimizes undesirable effects for the dental team through chronic exposure with nitrous oxide [6, 7].

The European guidelines [20] suggest a training course before the use of nitrous oxide by dentists which cover behavior management, physical and biological properties of nitrous oxide and basic life support, besides, 10–12 h of lectures, practical training with 5 observations, assistance and supervised sedation treatments each. Due to the new introduction of nitrous oxide in Germany, there were few certified courses available and the study reveals a broad picture of the training of dentists using nitrous oxide. Still, most of the users (67 %) attended courses for 2 days reflects the duration of the European and German recommendations [20, 21].

4.2 Application technique and maximum concentration

The effective usage of nitrous oxide sedation depends on the proper concentration during its application. The EAPD recommended 30–40 % for adults to reach excellent sedation levels in patients which can be increased during some painful procedure such as extraction and local anesthesia or be reduced during simple ones like restorations [11].

Almost all dentists used a titration technique for finding an individual effective concentration of nitrous oxide. The maximum concentrations within this study were all below 50 % and mostly even in the range of 30–40 %. This minimizes the risk of side effects which is increased with concentrations above 50 % inducing deep sedation or as an anesthetic agent during major surgery [22, 25].

4.3 Indications, frequency of use and referrals

In this part of the study, only 14 out of 100 (14 %) questionnaires were returned. The prime indication for nitrous oxide was anxious patients reported by 95 % of the dentists which is in agreement with observational studies and reviews [1, 11, 12, 20]. This was followed by complex dental treatments (49 %), while non-cooperative children or mentally-handicapped patients were not considered

the main indications for nitrous oxide (20 and 18 %, resp.). In the literature, publications and recommendations on non-cooperative children and pediatric dentistry dominate [11, 21]. But at least in this German study, as in the French one, the use in adults seems to be more frequent [12].

In very few practices, nitrous oxide sedation was a standard procedure for several patients a day (3.3 %). Many dentists used it 1–3 times per month (41.0 %) or even less, which might make it difficult to gain experience which could lead to elevated levels of side effects [13, 25].

Referrals are a key element in specialized dental treatment and, e.g., an Irish study showed that 87 % of general dentists referred children to GA for extractions. As 29 % of the Irish general practitioners had the equipment for minimal sedation with nitrous oxide, the majority of them discussed the sedation as alternative treatment option with their patients and their parents instead of general anesthesia [10]. Nevertheless, the referral rate was high. Similarity in this German study, 71 % of the responding general dentists referred patients to GA, but in contrast to that, none of them referred patients to be treated with nitrous oxide sedation. On the other hand, 71 % of these general practitioners considered non-cooperative children or anxious patients an eligible indication for nitrous oxide, 50 % also patients with a mental handicap and 42 % patients with complex treatment procedures. This also mirrors the actual use of minimal sedation with nitrous oxide in a French study [12].

A shift from treatment under GA to sedation with nitrous oxide could be accompanied by a greater reduction of anxiety [3], possibly through conditioning patients under regular dental treatment modalities which might reduce the need for future GA even further [18].

4.4 Side effects and safety

The general side effects of nitrous oxide sedation are over sedation, vomiting, nausea, dysphoria, sweating, restlessness, panic, headache, nightmares, tinnitus and urinary in-

continence [4, 11], while severe emergency situations are very rare [15, 20].

Complications seem to be associated with a long treatment time, high nitrous oxide concentration or rapid changes in the concentration levels of nitrous oxide [19, 20]. As most dentists in the German study employed concentrations well below 50 %, adjusted the individual level slowly via titration and had sedation time of less than 60 min, the chances for unwanted side effects are minimal. This was confirmed by 84 % of the cases without any and euphoria being the most prevalent side effect (5 %). Other complications such as nausea, vomiting, sweating or restlessness were slightly higher than in the equivalent French study [12], but with 2–3 % each rare and of minor severity. No serious complication was noticed and all procedures could be successfully performed, although the dentists might have a slight reporting bias. Still, other studies also report a success rate of 90 % [12].

The elevated rate of side effects could, possibly, be associated with nitrous oxide being a relatively new technique in Germany and some practitioners might still be on a learning curve due to the short time of experience. In addition, the rather infrequent use by some dentists might not be helpful to reach the level of an experienced user who can achieve lower rates of side effects [5, 13]. More standardized training according to the European and German recommendations might be helpful.

In the present study, minimal sedation with nitrous oxide exhibited in German dental practices rarely resulted in mild side effects. Due to the relaxation and the reduced gag reflex, but intact awareness and protective reflexes a high safety level exists in accordance with other studies and reviews [11, 12, 20].

4.5 Patients' and dentists' satisfaction

The satisfaction level of the patients and the dentists were extremely high, exceeding 90 % which mirrors other studies [2, 23]. Thus, they often opted to perform the next treatment also with a nitrous oxide sedation. Es-

pecially for anxiety patients this is an important result, but also for strenuous surgical procedures the high level of satisfaction is very interesting [11]. Especially for the group of patients with anxiety that was preferably treated in this study, it can reduce the problem for this subsequent treatment [3].

5. Conclusions

Within the limitations of this study, it can be concluded that German dentists exhibit a positive attitude towards minimal sedation with nitrous oxide. The vast majority of the responding general dentists knew about nitrous oxide from journals, while undergraduate education in the universities did not produce significant experience with nitrous oxide sedation. Still, a considerable number of the responding general dentists (21 %) would be interested in a future use. Interestingly, responding general dentists do not refer special patients to a sedation treatment to another dentist, in contrast to the regular referrals for general anesthesia (71 %).

The vast majority of responding dentists who had purchased the equipment were satisfied or highly satisfied (97 %). Minimal sedation with nitrous oxide was mostly employed for surgical procedures in adults with dental phobia or anxiety.

The success rate of using nitrous oxide was remarkable, both for the sedation and the subsequent treatment according to the reported treatment in the last patient. Even with the risk of a reporting bias, this is still in line with other studies where about 90 % successful treatments could be achieved. As in other studies, very few side effects were reported reaching from euphoria (5 %) to nausea, vomiting or sweating with 3 % or less. No severe side effects or interruptions of the sedation or dental treatment were recorded.

Overall, this study confirms that nitrous oxide is an easy and predictable way to achieve minimal sedation in order to improve dental treatment. Thus, it could be taken into account before a referral to general anesthesia. In accord with the new European and German recommendations, there is a potential that nitrous oxide could be

more widely used in Germany as it is already in other countries.

Acknowledgements

We would like to thank Biewer Medical, TLS med-sedation GmbH and Baldus Medizintechnik for their friendly support of this study.

Conflict of interest:

The authors state that they have no conflict of interest as defined by the guidelines of the International Committee of Medical Journal Editors.

References

- American Academy of Pediatric Dentistry: Guideline for monitoring and management of pediatric patients before, during, and after sedation for diagnostic and therapeutic procedures: Update 2016. *Pediatr Dent* 2016; 38: 77–106
- Arcari S, Ferro R: Preschool children and relative analgesia: satisfaction grading through a verbal questionnaire. *Eur J Paediatr Dent* 2008; 9: 18–22
- Arch LM, Humphris GM, Lee GT: Children choosing between general anaesthesia or inhalation sedation for dental extractions: the effect on dental anxiety. *Int J Paediatr Dent* 2001; 11: 41–48
- Berge TI: Acceptance and side effects of nitrous oxide oxygen sedation for oral surgical procedures. *Acta Odontol Scand* 1999; 57: 201–206
- Collado V, Nicolas E, Faulks D, Hennequin M: A review of the safety of 50 % nitrous oxide/oxygen in conscious sedation. *Expert Opin Drug Saf* 2007; 6: 559–571
- Costa Paes ER, Braz MG, Lima JT et al.: DNA damage and antioxidant status in medical residents occupationally exposed to waste anesthetic gases. *Acta Cir Bras* 2014; 29: 280–286
- Dale O, Brown BR, Jr.: Clinical pharmacokinetics of the inhalational anaesthetics. *Clin Pharmacokinet* 1987; 12: 145–167
- Donaldson D, Meehan JG: The hazards of chronic exposure to nitrous oxide: an update. *Br Dent J* 1995; 178: 95–100
- Faulks D, Hennequin M, Albecker-Grappe S et al.: Sedation with 50 % nitrous oxide/oxygen for outpatient dental treatment in individuals with intellectual disability. *Dev Med Child Neurol* 2007; 49: 621–625
- Freeman R, Carson P: Relative analgesia and general dental practitioners: attitudes and intentions to provide conscious sedation for paediatric dental extractions. *Int J Paediatr Dent* 2003; 13: 320–326
- Hallonsten A-L, Jensen B, Raadal M, Veerkamp J, Hosey MT, Poulsen S: EAPD Guidelines on Sedation in Paediatric Dentistry. 2003
- Hennequin M, Collado V, Faulks D, Koscielny S, Onody P, Nicolas E: A clinical trial of efficacy and safety of inhalation sedation with a 50 % nitrous oxide/oxygen premix (Kalinox) in general practice. *Clin Oral Investig* 2012; 16: 633–642
- Hennequin M, Maniere MC, Albecker-Grappe S et al.: A prospective multicentric trial for effectiveness and tolerance of a N2O/O2 premix used as a sedative drug. *J Clin Psychopharmacol* 2004; 24: 552–554
- Institut der Deutschen Zahnärzte: Einstellungen und Bewertungen der Bevölkerung zur zahnärztlichen Versorgung in Deutschland – Ergebnisse einer bundesweiten Umfrage 2011 – IDZ, 2012
- Kupietzky A, Tal E, Shapira J, Ram D: Fasting state and episodes of vomiting in children receiving nitrous oxide for dental treatment. *Pediatr Dent* 2008; 30: 414–419
- Levering NJ, Welie JV: Current status of nitrous oxide as a behavior management practice routine in pediatric dentistry. *J Dent Child (Chic)* 2011; 78: 24–30
- Locker D: Response and nonresponse bias in oral health surveys. *J Public Health Dent* 2000; 60: 72–81
- Luhmann J, Kennedy R: Nitrous oxide in the pediatric emergency department. *Clinical Pediatric Emergency Medicine* 2000; 1: 285–289
- Onody P, Gil P, Hennequin M: Safety of inhalation of a 50 % nitrous oxide/oxygen premix: a prospective survey of 35828 administrations. *Drug Saf* 2006; 29: 633–640
- Oulis C, Hosey M, Martens L, Hammer D, Martínez J, Raya A: Anwendung der inhalativen Lachgassedierung in der Zahnmedizin. Council of European Dentists, 2012
- Philippi-Höhne C, Daubländler M, Becke K, Reinhold P, Splieth C, Beck G: Gemeinsame Stellungnahme: Einsatz von Lachgas zur minimalen Sedierung von Kindern in der Zahnheilkunde. *Anästhesiologie* 2013; 54: 323–326
- Schmitt EL, Baum VC: Nitrous oxide in pediatric anesthesia: friend or foe? *Curr Opin Anaesthesiol* 2008; 21: 356–359
- Wilson KE, Welbury RR, Girdler NM: Comparison of transmucosal midazolam with inhalation sedation for dental extractions in children. A randomized, cross-over, clinical trial. *Acta Anaesthesiol Scand* 2007; 51: 1062–1067
- Yasny JS, White J: Environmental implications of anesthetic gases. *Anesth Prog* 2012; 59: 154–158
- Zier JL, Doescher JS: Seizures temporally associated with nitrous oxide administration for pediatric procedural sedation. *J Child Neurol* 2010; 25: 1517–1520



(Photo: private)

PROF. DR. CHRISTIAN SPLIETH
 Dep. of Preventive &
 Pediatric Dentistry, University of
 Greifswald, Fleischmannstr. 42,
 17487 Greifswald, Germany
splieth@uni-greifswald.de



(Photo: private)

IBRHAEM HATOUT M.SC.
 Pediatric Dentistry, Practice Dr. Derin,
 Boulaouin Dentists, Zeil 65,
 60313 Frankfurt am Main,
 Germany
ibraheemhatout@gmail.com

Mohammad Alkilzy, Christian H. Splieth

Self-assembling peptides for caries prevention and treatment of initial carious lesions, a review

Abstract: The shift from reparative to regenerative dentistry reflects the current trend in medicine and also mirrors the new understanding of caries as a chronic disease. Self-assembling peptide P11-4 showed promising results in the regenerative biomimetic remineralization of initial carious lesions. This approach may present safe and acceptable preventive and minimal invasive treatment for initial caries in children and adolescents. Further studies it is suggested to investigate this novel approach in treatment of molar incisor hypomineralization and cavitated carious lesions.

Keywords: P11-4; self-assembling peptide; caries prevention; minimal invasive treatment; pediatric dentistry; biomimetic remineralization; enamel regeneration; initial caries; Curodont Repair

Introduction

Dental caries is a chronic, infectious, progressive disease, starting with initial loss of tooth minerals and leading to total tooth destruction over time. Caries occurs when an imbalance between re- and de-mineralization takes place at the site of loss of minerals in hard dental tissue [23]. Therefore, the classic “treatment” of cavities by drilling and filling constitutes repair of the damage, but does not treat the disease itself. “Real” caries treatment would consist of shifting the equilibrium to re-mineralization, for instance by improving the daily oral hygiene regime, healthy diet and fluoride application. The new understanding of caries kinetics and monitoring the de-/re-mineralization equilibrium can indicate measures for correcting the mineralization balance [10]. In the early stages of caries, prior to the cavitation of the enamel surface, many non- and minimally invasive treatments have been suggested to avoid

further tooth destruction and subsequently restorations. The primary aim of non-invasive treatments is to inactivate or arrest the caries. This can be achieved by diet control and plaque removal which allows the carious lesions to remineralize naturally through saliva [9]. The presence of fluorides clearly enhances remineralization and prevents further demineralization [19, 22]. Unfortunately, most preventive approaches rely on changes in the patient's behaviour, but this is not always an easy job especially in children and adolescences. A possible alternative is sealing caries risk surfaces mechanically [2], but sealants are prone to microleakage and subsequent caries in the long run [13] (Fig. 1).

An alternative approach to the current strategies for managing initial non-cavitated carious lesions is the recently introduced self-assembling peptide P11-4 [1] for regenerating demineralized tooth tissue. This peptide forms a 3D-matrix within demineral-

ized carious lesions, which enables *novo* hydroxyapatite crystal formation facilitating the regeneration of the lost enamel structure [10, 15] (Fig. 2). The peptide has shown encouraging results as a scaffold for enamel regeneration [26]. This paper presents the current scientific evidence and clinical implementations for the self-assembling peptide P11-4 in a modern caries management.

Biomimetics with self-assembling peptides

The self-assembling peptide P11-4 is clinically available as Curodont Repair and it has the chemical structure: Ace-Gln-Gln-Arg-Phe-Glu-Trp-Glu-Phe-Glu-Gln-Gln-NH₂. It is synthetic and manufactured under cGMP and contains no human- or animal-derived components. Biocompatibility studies (according to ISO 10993 or equivalent) have shown that P11-4 did not raise any cytotoxic effects or any immunological response [7, 12, 18]. P11-4 has been

Conditions and indications for minimal invasive caries treatment with SAP	Limitations and contra-indications for minimal invasive caries treatment with SAP
Active initial lesions without cavitation (Fig. 4)	Carious lesion with cavitation
Lack in the patient's compliance with toothbrushing and dental hygiene	Good patient's compliance to dental hygiene
Moderate caries risk and activity	Patients with low caries risk
Age groups with elevated caries activity such as adolescences and young adults	Elderly patients with slow caries progression or already arrested lesions
Progression of the lesion in spite of preventive approaches	Patients with allergy to one or more elements of the product

Table 1 Indications and limitations for minimal invasive caries treatment with SAP

proven safe in animals and patients in vivo. No adverse device effects have been reported so far [3].

P11-4 undergoes under specific physicochemical conditions and above a critical concentration a hierarchical self-assembly to form tapes and ribbons within seconds, and fibrils and fibers within the following 24 h [1, 6, 8] (Fig. 3). These resulting self-assembling peptide fibres forming the 3D Self-Assembling Peptide Matrix (SAPM) can grow to a significant length. If the conditions for self-assembly are given, the assembly process cannot be stopped at the intermediates unless no more monomeric peptides are available. Confocal microscopy and mass spectroscopy showed that monomeric P11-4 diffuses through the pores of demineralized enamel, where fibre formation is triggered and the 3D matrix is formed [16]. Furthermore, C-labeled P11-4 indicated that about 35 % of P11-4

remained within artificial carious lesions [16] being available for de novo hydroxyapatite crystal formation. Two studies [10, 15] used the microtomography (microCT) analysis of remineralized specimens and found a remineralization of up to 90 % of the original enamel density.

A series of in-vitro studies insured the high affinity of the P11-4 matrix for Ca^{2+} ions and its action as a nucleator for de novo hydroxyapatite formation [6, 16, 17, 25]. Furthermore, the P11-4 fibers bind to the already existing Ca^{2+} ions of the hydroxyapatite lattice of the tooth enamel [6], enabling stable bridge binding of the new regenerated enamel to the tooth hard tissue. A study of Kind et al. [16] investigated the diffusion of P11-4 into a carious lesion by time resolved confocal microscopy pictures. The results showed that the P11-4 diffuses beyond the volume of the carious

lesion into the enamel layer below as was defined as the carious lesion on a microradiograph. After the formation of fibres is complete the formed fibers seem to occupy the observed lesion.

Clinical implementation of self-assembling peptide

Feasibility of clinical application, safety and clinical effect of P11-4 were first examined in an un-controlled safety trial treating arrested carious lesions on buccal surfaces in 15 adults [6]. As no adverse events were recorded by the use of the product and the blinded evaluation of the lesions showed a significant improvement of lesions judged by colour, size and perceived progression, further clinical studies were feasible. Table 1 lists some clinical indications and limitations for minimal invasive caries treatment with self-assembling peptides (SAP).

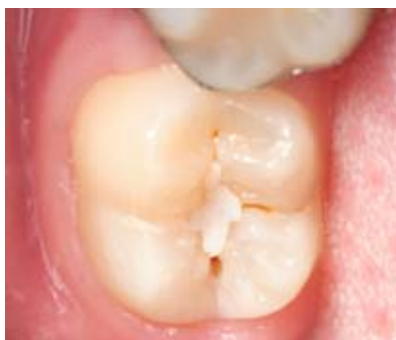

Figure 1 Fissure sealants are prone to microleakage and subsequent caries in the long run and require continuous follow-ups and corrections when indicated.

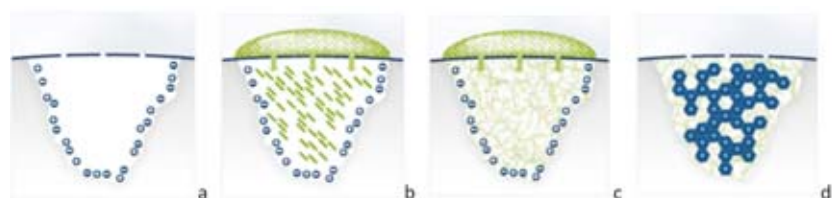


Figure 2a–d Illustration of the treatment of a carious lesion by the self-assembling peptide P11-4. **(a)** Initial carious lesion. **(b)** A drop of monomeric self-assembling peptide P11-4 is applied on the lesion surface; the monomers diffuse into the lesion. **(c)** P11-4 assembles within the carious lesion, forming a 3D scaffold. **(d)** De novo hydroxyapatite crystals form around the self-assembling peptide scaffold.

(Fig. 2 and 3: With friendly permission of credentis ag)

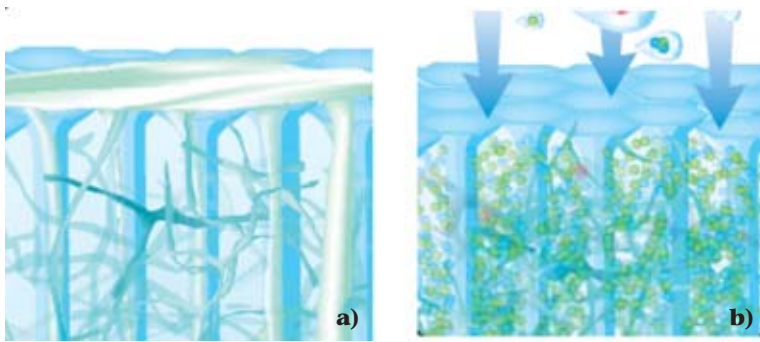


Figure 3a and b P11-4 forms within an early carious lesion an organic 3D-matrix (a), the matrix is highly affine to Ca^{2+} and PO_4^{2-} ions thereby enabling de novo formation of dental hard tissue by biomimetic mineralisation (b).

Self-assembling peptide for non- and minimal invasive treatment of occlusal initial caries

Occlusal surfaces of erupting permanent molars are highly prone to caries. Because of the infra-occlusal position of these teeth during the eruption, an effective toothbrushing is difficult. Even sealing of these teeth presents almost difficulties because of the gingiva covering the occlusal surfaces in partially erupted teeth (Fig. 4). Therefore, a randomized controlled single-blind study was conducted by Alkilzy et al. [3, 4] on children with visible active early caries on erupting permanent molars to investigate the safety and clinical efficacy of P11-4 for treatment of initial caries. Subjects were randomized to either the test group (P11-4 + fluoride varnish) or control group (fluoride varnish alone). Caries was assessed at baseline and at 3- and 6-month post treatment per laser fluorescence, a visual analog scale, the International

Caries Detection and Assessment System (ICDAS), and the Nyvad caries activity criteria [21]. Safety and clinical feasibility of the treatment approaches were also assessed. The P11-4 (Curodont Repair) was applied according to the instruction of the manufacturer (Fig. 5). Compared with the control group, the test group showed clinically and statistically significant improvement in all outcomes at 3- and 6-month follow-ups. The laser fluorescence readings (odds ratio = 3.5, $P = 0.015$) and visual analog scale scores (odds ratio = 7.9, $P < 0.0001$) were significantly lower for the test group, and they showed regression in ICDAS scores (odds ratio = 5.1, $P = 0.018$) and conversion from active to inactive lesions according to Nyvad criteria (odds ratio = 12.2, $P < 0.0001$, Fig. 6). Results suggest that Curodont Repair may present a simple, safe and effective non-invasive treatment for early occlusal carious lesions on erupting teeth in conjunction with

topical fluoride. Figure 3 shows a treatment of an initial carious lesion in the occlusal surface of first permanent molar during eruption using Curodont Repair.

Self-assembling peptide for caries prevention in patients with orthodontic brackets

Jablonski-Momeni et al. [14] investigated in a randomised, cross-over in situ trial the ability of 1,000 ppm self-assembling peptide P11-4 (Curodont Protect) to remineralize artificial initial caries lesions compared to the use of 22,600 ppm fluoride varnish. Laser fluorescence values (LF) and Micro-CT analysis was used to assess mineral changes within the specimens. The test group with P11-4 showed significantly more remineralization than the negative ($p = 0.01$) and positive control with fluoride ($p = 0.003$). The authors concluded that P11-4 showed prevention of caries and remineralization of enamel around orthodontic brackets.

The manufacturer of Curodont Protect claims that once the product is applied on the surface of the tooth the fibres can bind to the tooth via the Ca^{2+} -binding sites to the aprismatic HA crystal on the surface of the tooth. As the surface of the tooth – which undergoes constant re-, demineralisation – is not prismatic in structure the long axis of the HA crystal is available for binding, and the natural zeta-potential of the enamel surface seems to facilitate the binding. As a result, the 3D matrix will bind onto the tooth surface with multiple binding sites.

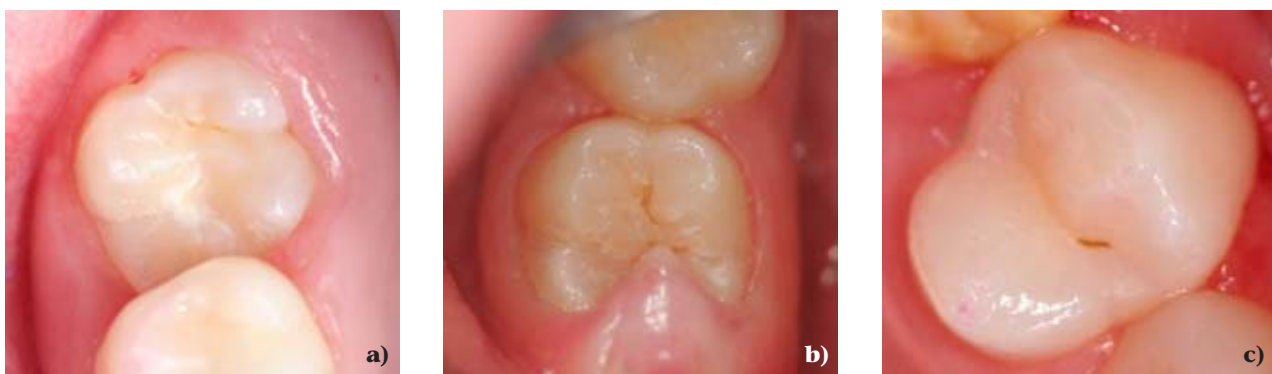

Figure 4 a-c (a and b) Active initial carious lesions in permanent molars during erupting where fissure sealing is very difficult to not possible. **(c)** Non-cavitated initial carious lesion on premolar. In these cases, the minimal invasive treatment with SAP P11-4 is good indicated.

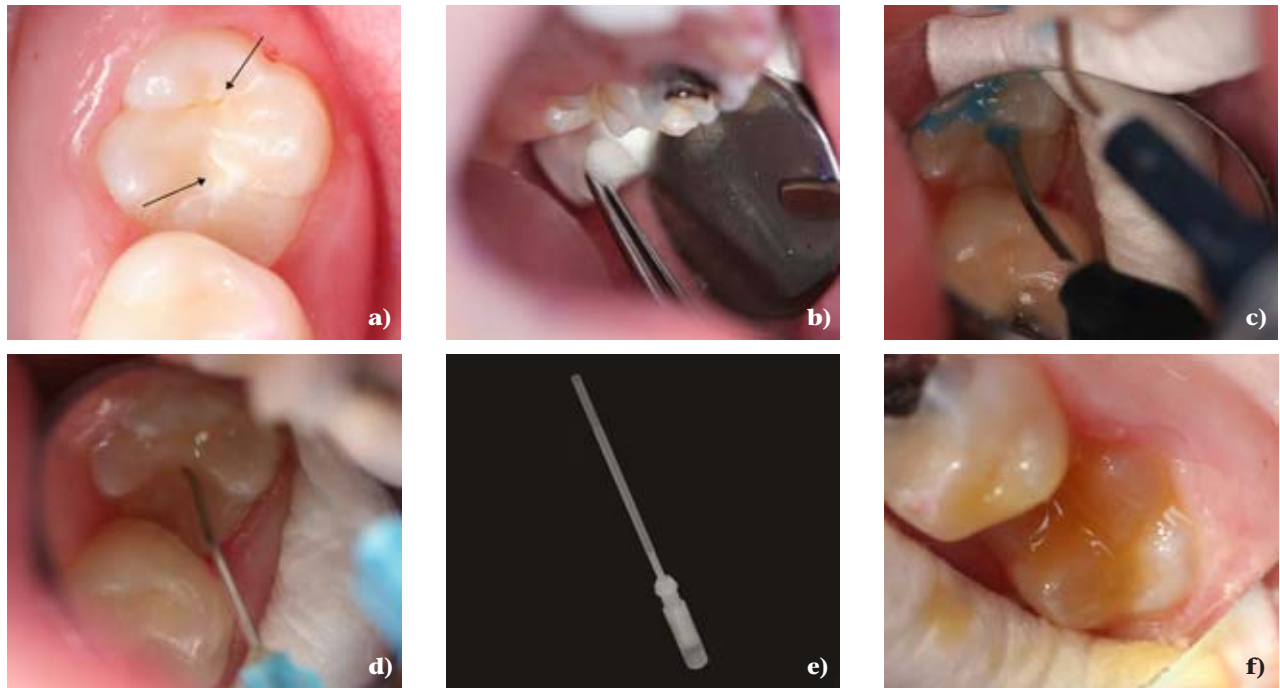


Figure 5a–f Clinical application of P11-4 (Curodont Repair). Initial active carious lesions in first permanent molar at eruption (a), elimination of organic debris with 3 % NaClO (b), etching with 35 % phosphoric acid (c), application of P11-4 and waiting 3–5 min for diffusion into the lesion and matrix formation (d), the recent applicator of P11-4 Curodont Repair (e), application of fluoride varnish (f).

Self-assembling peptide for treatment of buccal caries and white spots

Bröseler et al. [5] compared in a prospective, randomized, split-mouth, clinical trial the efficacy of the self-assembling peptide P11-4 to fluoride varnish in the treatment of early buccal carious lesions. Subjects with at least 2 clinically affected teeth were treated at day one D0 and day 90 D90 with P11-4 (test) or fluoride varnish (control). At day 180, fluoride varnish was applied on

all study lesions. Standardized photographs were taken at D0, D30, D90, D180 and D360 and the decrease in size between test and control groups was blindly morphometrically assessed. The results showed a significant difference between test and control groups, indicating a decrease in test lesions and stabilization of control lesions size ($p = 0.001$). The authors concluded that the size of early carious lesions treated with P11-4 was significantly reduced and this size reduction was

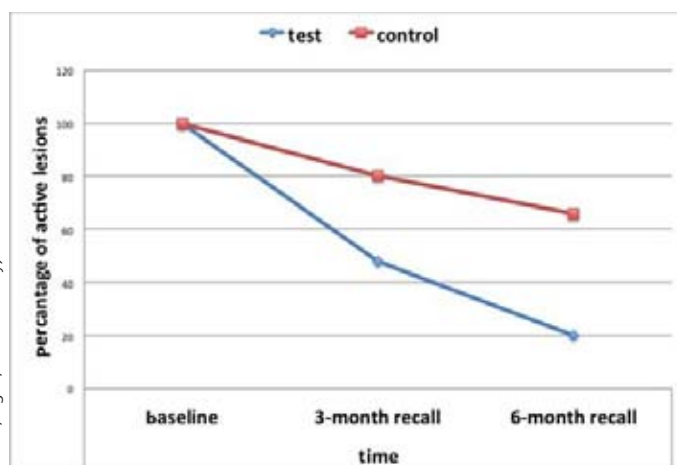
superior to that of fluoride varnish treatment.

Self-assembling peptide for treatment of proximal caries

A study by Schlee et al. [24] investigated the clinical performance of self-assembling peptide P11-4 on non-cavitated initial proximal carious lesions 12 months after treatment. Twenty-six patients with 35 carious lesions were included in a practice-based case series. The x-rays of the proximal lesions at baseline and at day 360 were evaluated pairwise in a randomized and blinded manner with respect to the time point. The one-year results showed a predominant shift toward regression of the initial lesions, with 20 of 28 lesions showing total or partial regression, 4 unchanged, and 4 progressing. The authors suggested that the initial proximal carious lesions can regress after treatment with P11-4, but additional factors might influence the overall treatment outcome.

Summary and suggestions

The shift from reparative to regenerative dentistry reflects the current trend in medicine and also mirrors the new understanding of caries as a



(Tab. 1, Fig. 1, 4–6: M. Alkilzy)

Figure 6 Significant reduction in caries activity of the lesions treated with SAP in comparison to control lesions at 3- and 6-month recalls [3].

chronic disease. Self-assembling peptide P11-4 showed promising results in the regenerative biomimetic remineralization of initial carious lesions. This approach may present safe and acceptable preventive and minimal invasive treatment for initial caries in children and adolescents. However, studies with longer observation periods are needed to confirm the consistent effect of P11-4. Further studies are suggested to investigate this approach in treatment of molar incisor hypomineralization and cavitated carious lesions.

Conflict of interest:

The authors state that they have no conflict of interest as defined by the guidelines of the International Committee of Medical Journal Editors.

References

- Aggeli A, Fytas G, Vlassopoulos D, McLeish TC, Mawer PJ, Boden N: Structure and dynamics of self-assembling beta-sheet peptide tapes by dynamic light scattering. *Biomacromolecules* 2001; 2: 378–388
- Ahovuo-Saloranta A, Forss H, Walsh et al.: Sealants for preventing dental decay in the permanent teeth. *Cochrane Database Syst Rev* 2013; March 28;(3):CD001830. doi: 10.1002/14651858.CD001830.pub4.
- Alkilzy M, Tarabaih A, Santamaria RM, Splieth CH: Self-assembling peptide P11-4 and fluoride for regenerating enamel. *J Dent Res* 2018; 97: 148–154
- Alkilzy M, Santamaria R. M, Schmoeckel J, Splieth CH: Treatment of carious lesions using self-assembling peptides. *Adv Dent Res* 2018; 29: 42–47
- Bröseler F, Tietmann C, Bommer C, Drechsel T, Heinzl-Gutenbrunner M, Jepsen S: Randomised clinical trial investigating self-assembling peptide P11-4 in the treatment of early caries. *Clin Oral Investig* 2019 Apr 29. doi: 10.1007/s00784-019-02901-4
- Brunton PA, Davies RP, Burke JL et al.: Treatment of early caries lesions using biomimetic self-assembling peptides – a clinical safety trial. *Br Dent J* 2013; 215: E6
- Burke, JL: In situ engineering of skeletal tissues using self-assembled biomimetic scaffolds, in Leeds Dental Institute. The University of Leeds, Leeds 2011, p. 1–277
- Davies RP, Aggeli A, Beevers AJ et al.: Self-assembling β -sheet tape forming peptides. *Supramolecular Chemistry* 2006; 18: 435–443
- de Almeida Pdel V, Grégio AM, Machado MA, de Lima AA, Azevedo LR: Saliva composition and functions: a comprehensive review. *J Contemp Dent Pract* 2008; 9: 72–80
- Deyhle H, Dziadowiec I, Kind L, Thalmann P, Schulz G, Müller B: Mineralization of early stage carious lesions in vitro – a quantitative approach. *Dent J* 2015; 3: 111–122
- Editorial. *Nature medicine* 2014; 20: 795
- Felton S: Self assembling b-sheet peptide networks as smart scaffolds for tissue engineering, in chemistry. University of Leeds, Leeds 2005, p. 184
- Heyduck C, Meller C, Schwahn C, Splieth CH: Effectiveness of sealants in adolescents with high and low caries experience. *Caries Res* 2006; 40: 375–381
- Jablonski-Momeni A, Korbmacher-Steiner H, Heinzl-Gutenbrunner M, Jablonski B, Jaquet W, Bottenberg P: Randomised in situ clinical trial investigating self-assembling peptide matrix P11-4 in the prevention of artificial caries lesions. *Sci Rep* 2019; 9: 269. doi: 10.1038/s41598-018-36536-4
- Kang J, Davies RP, Brookes SJ, Kirkham J: Multi-level modelling to further understanding of micro-CT data. In proceedings, enamel 9 conference in Harrogate, University of Leeds, Leeds 2016, Abstract 68
- Kind L, Stevanovic S, Wuttig S et al.: Biomimetic remineralization of carious lesions by self-assembling peptide. *J Dent Res* 2017; 96: 790–797
- Kirkham J, Firth A, Vernals D et al.: Self-assembling peptide scaffolds promote enamel remineralization. *J Dent Res* 2007; 86: 426–30
- Kyle S, Aggeli A, Ingham E, McPhereson MJ: Recombinant self-assembling peptides as biomaterials for tissue engineering. *Biomaterials* 2010; 31: 9395–9405
- Marinho, VC, Worthington HV, Walsh T, Clarkson JE: Fluoride varnishes for preventing dental caries in children and adolescents. *Cochrane Database Syst Rev* 2013 Juli 11;(7):CD002279. doi: 10.1002/14651858.CD002279.pub2
- Marthaler TM: Changes in dental caries. *Caries Res* 2004; 38: 173–181
- Nyvad B, Machiulskiene V, Bælum V: The Nyvad criteria for assessment of caries lesion activity. In: Stookey GK (editor): *Clinical models workshop: remin-demin, precavitation, caries: proceedings of the 7th Indiana Conference, Indianapolis, Indiana, USA. Indiana University School of Dentistry* 2005, p. 99–116
- Petersson LG, Twetman S, Pakhomov GN: The efficiency of semiannual silane fluoride varnish applications: a two-year clinical study in preschool children. *J Public Health Dent* 1998; 58: 57–60
- Pitts NB, Zero DT, Marsh PD et al.: Dental caries. *Nat Rev Dis Primers* 2017; May 25; (3):17030. doi: 10.1038/nrdp.2017.30
- Schlee M, Schad T, Koch JH, Cattin PC, Rathe F: Clinical performance of self-assembling peptide P11-4 in the treatment of initial proximal carious lesions: A practice-based case series. *J Investig Clin Dent* 2018; 9: e12286
- Sousa J, Carvalho RG, Barbosa-Martins LF, Tersariol IL, Nascimento FD, Puppin-Rontani RM: Peptide P11-4 acts as a nucleator of hydroxyapatite crystals formation. *J Dent Res* 2017; 96(Spec. Iss. A): 3297
- Thomson BM, Hardaker L, Davies RPW et al.: P11–15 (NNRFWEFENN): a second generation biocompatible, self-assembling peptide with potential to promote enamel remineralization. *Caries Res* 2014; 48: 384–450 (Abs. Nr. 47)



(Photo: private)

PD DR. MOHAMMAD ALKILZY
 Dep. of Preventive &
 Pediatric Dentistry, University of
 Greifswald, Fleischmannstr. 42,
 17487 Greifswald, Germany
 alkilzym@uni-greifswald.de



(Photo: private)

PROF. DR. CHRISTIAN SPLIETH
 Dep. of Preventive &
 Pediatric Dentistry, University of
 Greifswald, Fleischmannstr. 42,
 17487 Greifswald, Germany
 splieth@uni-greifswald.de

DZZ International
German Dental Journal International

Publishing Institution

International Journal of the German Society of Dentistry and Oral Medicine/Deutsche Gesellschaft für Zahn-, Mund- und Kieferheilkunde e. V. (Zentralverein, gegr. 1859), Liesegangstr. 17a, 40211 Düsseldorf, Phone: +49 2 11 / 61 01 98 – 0, Fax: +49 2 11 / 61 01 98 – 11

Affiliations

German Society of Periodontology (DG PARO)
 German Society for Prosthetic Dentistry and Biomaterials
 German Association for Conservative Dentistry
 German Society of Craniomandibular Function and Disorders in the DGZMK
 German Society of Paediatric Dentistry
 German Academy of Oral and Maxillofacial Surgery
 German Association of Dento-Maxillo-Facial Radiology (GSDOM)
 German Academy of Dental Ergonomics
 Group of Basic Science in Dentistry

Editors

Prof. Dr. Guido Heydecke
 Editor in Chief | DZZ International
 Chairman Department of Prosthetic Dentistry
 University Medical Center Hamburg-Eppendorf
 Martinistraße 52 | 20246 Hamburg
 Phone +49 (0) 40 7410 – 53261
 Fax +49 (0) 40 7410 – 54096

Prof. Dr. Werner Geurtsen
 Editor | DZZ International
 Chairman, Department of Conservative Dentistry, Periodontology and Preventive Dentistry
 Hannover Medical School
 Carl-Neuberg-Str. 1 | 30625 Hannover
 Phone +49 (0) 511 – 5324816
 Fax +49 (0) 511 – 5324811

Associate Editors

Prof. Nico H.J. Creugers, D.D.S., PH.D., Nijmegen/NL
 Prof. Dr. Henrik Dommisch, Berlin/GER

Prof. Dr. Dr. Marco Rainer Kesting, Erlangen/GER
 Prof. Dr. Torsten Mundt, Greifswald/GER
 Priv.-Doz. Dr. Falk Schwendicke, Berlin/GER
 Univ.-Prof. Dr. med. dent. Michael Wolf, M.Sc., Aachen/GER

Publisher

Deutscher Ärzteverlag GmbH
 Dieselstr. 2, 50859 Köln;
 Postfach 40 02 65, 50832 Köln
 Phone: +49 2234 7011-0; Fax: +49 2234 7011-6508
 www.aerzteverlag.de

Executive Board

Jürgen Führer

Director Business Division Medicine and Dentistry

Katrin Groos

Product Management

Carmen Ohlendorf, Phone: +49 02234 7011-357;
 Fax: +49 2234 7011-6357; ohlendorf@aerzteverlag.de

Editorial Office

Irmingard Dey, Phone: +49 2234 7011-242;
 Fax: +49 2234 7011-6242; dey@aerzteverlag.de
 Ute Blechschmidt, Phone: +49 2234 7011-377;
 Fax: +49 2234 7011-6377; blechschmidt@aerzteverlag.de

Frequency

6 times a year

Layout

Linda Gehlen

Account

Deutsche Apotheker- und Ärztebank, Köln,
 Kto. 010 1107410 (BLZ 370 606 15),
 IBAN: DE 2830 0606 0101 0110 7410,
 BIC: DAAEEDDD,
 Postbank Köln 192 50–506 (BLZ 370 100 50),
 IBAN: DE 8337 0100 5000 1925 0506,
 BIC: PBNKDEFF

2. Volume
 ISSN 2627-3489

Copyright and Right of Publication

Diese Publikation ist urheberrechtlich geschützt und alle Rechte sind vorbehalten. Diese Publikation darf daher außerhalb der Grenzen des Urheberrechts ohne vorherige, ausdrückliche, schriftliche Genehmigung des Verlages weder vervielfältigt noch übersetzt oder transferiert werden, sei es im Ganzen, in Teilen oder irgendeiner anderen Form. Die Wiedergabe von Warenbezeichnungen, Handelsnamen und sonstigen Kennzeichen in dieser Publikation berechtigt nicht zu der Annahme, dass diese frei benutzt werden dürfen. Zumeist handelt es sich dabei um Marken und sonstige geschützte Kennzeichen, auch wenn sie nicht als solche bezeichnet sind.

Disclaimer

Die in dieser Publikation dargestellten Inhalte dienen ausschließlich der allgemeinen Information und stellen weder Empfehlungen noch Handlungsanleitungen dar. Sie dürfen daher keinesfalls ungeprüft zur Grundlage eigenständiger Behandlungen oder medizinischer Eingriffe gemacht werden. Der Benutzer ist ausdrücklich aufgefordert, selbst die in dieser Publikation dargestellten Inhalte zu prüfen, um sich in eigener Verantwortung zu versichern, dass diese vollständig sind sowie dem aktuellen Erkenntnisstand entsprechen und im Zweifel einen Spezialisten zu konsultieren. Verfasser und Verlag übernehmen keinerlei Verantwortung oder Gewährleistung für die Vollständigkeit, Richtigkeit und Aktualität der in dieser Publikation dargestellten Informationen. Haftungsansprüche, die sich auf Schäden materieller oder ideeller Art beziehen, die durch die Nutzung oder Nichtnutzung der in dieser Publikation dargestellten Inhalte oder Teilen davon verursacht werden, sind ausgeschlossen, sofern kein nachweislich vorsätzliches oder grob fahrlässiges Verschulden von Verfasser und/oder Verlag vorliegt.

© Copyright by Deutscher Ärzteverlag GmbH, Köln