

Diagnostic Testing Using Pterygomaxillary Notches and Retromolar Pads on Casts to Check Horizontal Jaw Relation

Xi Xi ZHANG¹, Jian Zhang LIU², Wen ZOU³, Mei WANG²

Objective: To verify horizontal jaw relations using anatomical marks on a cast and evaluate the efficiency and accuracy of the test on checking the horizontal relation.

Methods: A total of 200 patients with a loss of posterior occlusion were recruited. After casts were made and the horizontal jaw relation was recorded, the pterygomaxillary notch and retromolar pad were identified bilaterally on the maxillary and mandibular casts. On each cast, a vertical line was drawn to bisect the anatomical landmarks and the distance between the two vertical lines was measured. Using the result of the wax try-in appointment and the corresponding measurements, a diagnostic test was conducted. A receiver operating curve was created and the maximum horizontal distance between bisecting points that still obtained correct jaw relations was determined to be a criterion. The accuracy of the test to verify horizontal jaw relations was evaluated.

Results: The area under the curve of the receiver operating curve was 0.833 ($P < 0.05$). With a maximum Youden index, the d value threshold was 1.0 mm. Using 1.0 mm as a criterion to check the horizontal relation, the sensitivity of the test was 0.76 and the specificity was 0.93. The kappa value for different researchers was calculated to be 0.79 ($P < 0.05$). The intra-examiner 1 reliability gave a kappa value of 0.76 ($P < 0.05$), and intraexaminer 2 gave a value of 0.81 ($P < 0.05$).

Conclusion: The test for verifying the accuracy of horizontal jaw relations is reliable. If horizontal distance is measured as greater than 1.0 mm at the jaw relation record appointment, the recorded horizontal jaw relationship may be wrong and need to be reexamined.

Key words: cast, diagnostic test, horizontal relationship, pterygomaxillary notch, retromolar pad

Chin J Dent Res 2021;24(1):61–66; doi: 10.3290/j.cjdr.b1105885

During the fabrication of complete dentures, it is critical to determine the horizontal jaw relation accurately¹. Many factors can affect the recording of correct jaw

relations during treatment, including lack of mandibular coordination². Incorrect horizontal jaw relations can induce several problems, such as soreness, ill-fitting final dentures, and possibly an inability to masticate or speak. In clinical settings, remounting casts tend to be used to check the horizontal jaw relation; however, cast remounting is time-consuming and, if done improperly, requires another relation record appointment with the patient. Thus, a test was created to check the horizontal jaw relation by measuring consistent anatomical landmarks in the oral cavity and then determining its accuracy. The test aims to help to determine if the horizontal jaw relation records are accurate immediately after being obtained prior to wax try-in.

The human oral cavity is typically symmetrical and has several anatomical structures that remain unchanged even in the event of tooth loss^{2,3}. Two examples of this constancy are the mandibular retromolar pad and ptery-

- 1 Peking University School and Hospital of Stomatology, National Engineering Laboratory for Digital and Material Technology of Stomatology, National Clinical Research Center for Oral Diseases, Beijing Key Laboratory of Digital Stomatology, Beijing, P.R. China.
- 2 Department of Prosthodontics, Peking University School and Hospital of Stomatology, Beijing, P.R. China.
- 3 Denture Processing Center, Peking University Hospital of Stomatology, Beijing, P.R. China.

Corresponding author: Dr Jian Zhang LIU, Department of Prosthodontics, Peking University School and Hospital of Stomatology, 22# Zhong-guancun South Avenue, HaiDian District, Beijing 100081, P.R. China. Tel: 86-10-82195393; Fax: 86-10-62173402. Email: liujianzhangdr@163.com

This study was supported by the New Clinical Technology Programme of Peking University Hospital and Stomatology with the grant PKUSSNCT-18G02.

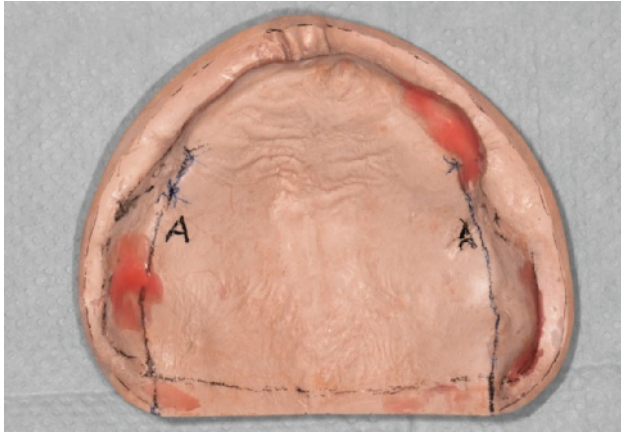


Fig 1 Line A traced on the maxillary cast.

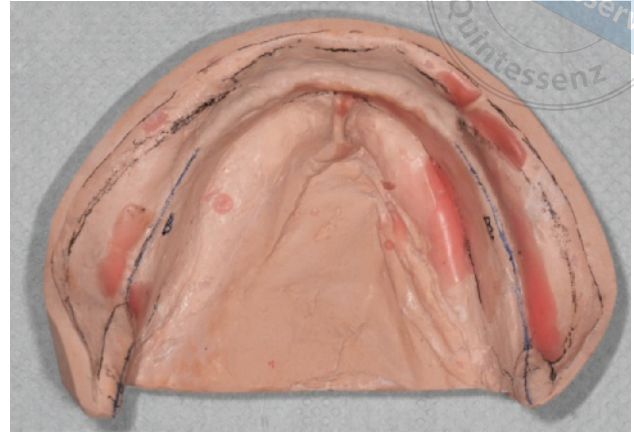


Fig 2 Line B traced on the mandibular cast.

gomaxillary notch. When the correct horizontal jaw relation is established, the pterygomandibular ligaments are symmetrical². The centre of the retromolar pad and the pterygomaxillary notch are two anatomical markers that are simple to identify in patients and tend to be symmetrical in the oral cavity. These landmarks have been adopted in jaw relation appointments to fabricate complete dentures and have seen success in clinics. This study assessed the use of the relationship between the retromolar pad and the pterygomaxillary notch to check the horizontal jaw relation immediately after recording.

Materials and methods

Subjects

A total of 200 patients were recruited from the Peking University School and Hospital of Stomatology (83 men and 117 women, mean age 70.28 ± 9.21 years old) from June 2015 to July 2016.

The inclusion criteria were as follows:

- patients whose molars and premolars had no stable occlusion, including complete and partially edentulous;
- patients seeking removable denture treatment.

The exclusion criteria were as follows:

- patients with severe disease who could not tolerate the jaw relation process;
- patients who desired implant-retained prostheses;
- patients whose retromolar pad or pterygomaxillary notch location was ambiguous.

The clinical trial was approved by the Institutional Ethical Board. Informed consent was obtained for all patients

prior to starting the procedures (ethical batch number: 2015-06-22-02).

Study procedure

A functional impression was taken using secondary impression techniques. Impression compound (NK, Shanghai Rongxiang Dental Material, Jiangxi, China) and alginate impression material (Kulzer, Hanau, Germany) were used to take the primary impression. The final impression was made using an individual impression tray (Lightplast Base Plate, Dreve, Unna, Germany) and alginate impression material. Master casts were fabricated using beading and boxing and poured with dental stone (Kulzer).

Thirty dental practitioners recorded horizontal jaw relations using their preferred method and documented their process. The dental practitioners had been trained in the methods they used. One used gothic arch tracing and recorded 15 jaw relations, 19 used swallowing methods and obtained 144 jaw relations, and 10 used natural chewing methods and recorded 41 jaw relations. Vertical jaw relations were determined by individual patient facial dimensions and verified with phonetics and facial expression.

Before checking the horizontal jaw relations, casts must be trimmed uniformly. The base of the cast must be parallel with the occlusal plane, and the thickness of the base should be greater than 1.0 cm. The lateral planes were orientated vertical to the cast base.

Lines were traced onto the casts to mark anatomical landmarks. The centre of the pterygomaxillary notch was identified bilaterally on the maxillary cast and these points were connected with a single line extend-

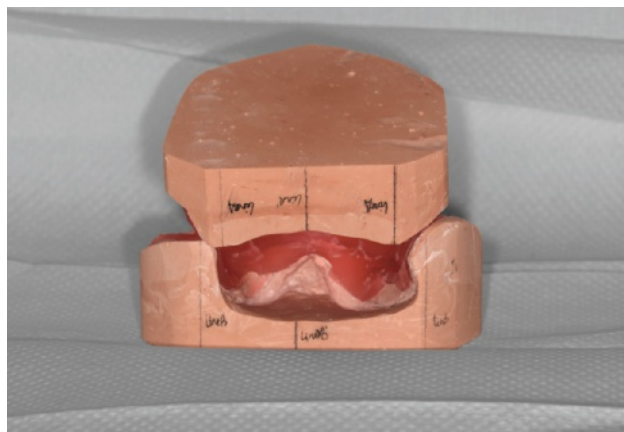

Fig 3 Drawing the middle line of lines A and B (lines A' and B', respectively).

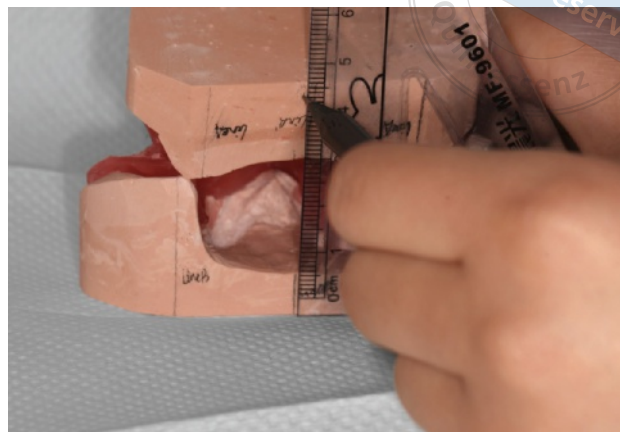


Fig 4 Lengthening line B' on the maxillary cast.

ing to the edge of the posterior lateral plane (Fig 1, line A). This process was then repeated on the mandibular cast using the superior point of the centre of the retro-molar pad (Fig 2, line B). From the two points on the bilateral edges of the maxillary cast, two vertical lines (Fig 3, line A) were drawn on the posterior lateral wall to the underside of the maxillary cast. Then, a second vertical line (Fig 3, line A') was traced vertically from the midpoint between the bilateral line A on the posterior wall vertical to the underside of the maxillary cast. Then, a second vertical line (Fig 3, line B') was traced in a similar fashion on the mandibular cast. Maxillary and mandibular casts were placed in position using the clinically obtained horizontal jaw record with fabricated denture bases and wax rims. Then, line B' was lengthened to the maxillary cast with a triangular ruler and the horizontal distance (d) was measured from line A' to line B' (Fig 4) with a Vernier calliper (MNT-150, MNT, China) (Fig 5).

Thirty casts and records were randomly selected from the original 200 patients. All casts were traced and measured separately by two different researchers and by the same researcher twice.

Artificial teeth were arranged in proper occlusion and a wax try-in was completed. The vertical dimension established during the original jaw relation appointment was assumed to be correct. Centric occlusion was verified by intercuspation of all denture teeth when rims were placed in the mouth. The patient was instructed to close their mouth and was observed as the mandible was pulled back into centric relation for the very first contact of the teeth with no deflection or reversing; this was recorded as a successful result^{4,5}. A failure was recorded if contact was made prematurely to returning

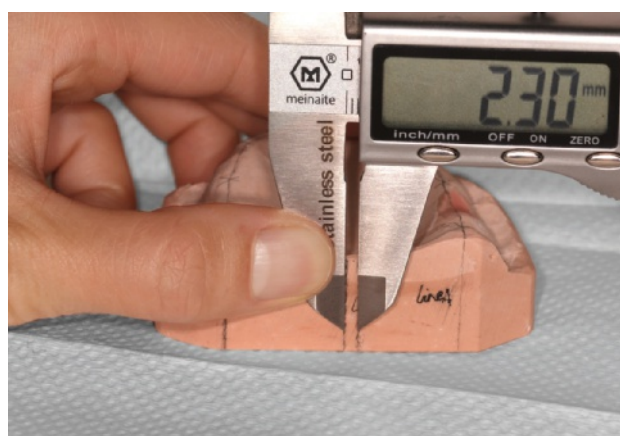

Fig 5 Measuring distance between line A' and line B'.

to centric relation. Failure indicated that the original horizontal relation record was wrong and needed to be rerecorded for the patient.

Sex, age, horizontal jaw relation methods, d value and results of the diagnostic test were recorded. To protect patient data, names were recorded using serial numbers and sex was recorded as 1 for male and 2 for female. Methods of determining the horizontal jaw relation were recorded as 1 for the gothic arch tracing method, 2 for swallowing methods, and 3 for natural chewing methods.

Data processing

SPSS (version 23.0, IBM, Armonk, NY, USA) was used for data processing. The level of significance was set at 0.05. The effect of sex, age and different researchers with their preferred jaw relation recording methods on the wax

try-in result were calculated using a chi-square test. A receiver operating curve (ROC) was then created to test the efficiency of d values as a reflection of the accuracy of the original clinical horizontal record and determined the threshold of d values that could be used to check the horizontal record by calculating the Youden index. The sensitivity and specificity of this threshold distance were calculated to check the accuracy of the clinical horizontal jaw relation records. The kappa values for interexaminer and intraexaminer reliability were calculated.

Results

Homogeneity of variance analyses

There were no differences in wax try-in result between groups based on age ($P = 0.121$) or sex ($P = 0.614$), as confirmed by homogeneity of variance analyses.

Usage of different methods to obtain jaw relation records

The results of applying different methods to determine jaw relation are presented in Table 1. Records were obtained successfully in 100.0% of cases when gothic arch methods were utilised, 76.9% of the time using swallowing methods, and 82.8% of the time using natural chewing methods. There were no significant differences ($P = 0.166$) between the methods used.

Efficiency of the test to check the accuracy of clinical horizontal jaw relation records and the d value threshold to verify horizontal relations

The recorded d values showed a deviation from the midline and were used to test the accuracy of the recorded horizontal jaw relations. The ROC was drawn to evaluate the competency of the test with the area under the curve (AUC) calculated at 0.833 ($P < 0.05$). After calculating and finding the maximum Youden index, a d value of 1.0 mm was the proper threshold value and the Youden index was 0.69. In other words, 1.0 mm was a criterion to check the horizontal jaw relation. When d values were higher than 1.0 mm, the results were recorded as positive, whereas when they were lower than or equal to 1.0 mm, the results were recorded as negative. A comparison of the wax try-in results (success or failure) and d value results (negative or positive) for coordinating casts is presented in Table 2. The sensitivity of d values for evaluating the wax try-in result was 0.76 and the specificity was 0.93.

Internal consistency among different researchers

The kappa value for interexaminer reliability was 0.79 ($P < 0.05$). The kappa value for intraexaminer 1 was 0.76 ($P < 0.05$), and 0.81 for intraexaminer 2 ($P < 0.05$).

Discussion

In clinical practice, many dental practitioners find it difficult to determine jaw relation once posterior vertical stops have been lost. Incorrect recording of jaw relation can result in prosthesis rejection, causing frustration for patients and clinicians⁶. Several methods can be employed to determine horizontal jaw relation⁷⁻⁹, but these require patient cooperation and consistency in jaw movements to obtain a centric relation. Furthermore, these methods are subject to the dental practitioner's experience with removable prosthodontic procedures. Jaw relation was frequently incorrectly recorded in student clinics, increasing the risk of ill-fitting dentures after processing. In this study, the incidence of incorrect horizontal jaw relations in all patients was 16%. Greater success was achieved using the gothic arch tracing method; however, the difference between all the methods used to record the horizontal jaw relation in this study was not statistically significant. The gothic arch tracing method requires more training to master and recorded different degrees of accuracy in different studies^{1,10-12}. The method involving use of the retromolar pad and pterygomaxillary notch to check the horizontal jaw relation can help spot errors in advance, increasing efficiency in the clinic and simplifying the wax try-in appointment.

In dentate patients, most oral structures are bilateral and in similar locations within the arch. When a centric relation is obtained, the position of the condyles is symmetrical and concentric, independent of any tooth contact^{13,14}. The masticatory muscles and ligaments support the position of the condyles bilaterally, including the pterygomandibular ligament. The retromolar pad and pterygomaxillary notch are landmarks that are always bilaterally present on the mandible and maxilla, respectively, and are rarely affected by tooth loss². Because there is generally little deviation in bilateral anatomical points, a point that horizontally bisects the pterygomaxillary notch and retromolar pad on the cast should be aligned if a vertical line is drawn to connect them. Thus, both of these landmarks were traced bilaterally on maxillary and mandibular casts of edentulous patients and the horizontal distance of the bisecting points was measured when the casts were articulated. If the horizontal measurement was large, the mandible

Table 1 Results of different methods used to determine jaw relation.

Result	Gothic arch methods	Swallowing methods	Natural chewing methods
Success, number of cases	15	117	35
Failure, number of cases	0	27	6

Table 2 Relationship between the wax try-in appointment and d values. When the d value was higher than 1.0 mm, the results were positive; when it was lower than or equal to 1.0 mm, the results were negative. When the outcome of the wax try-in was correct, the result was successful; when it was incorrect, the result was a failure.

Result	Positive	Negative
Success	12	155
Failure	25	8

might not be correctly aligned with the maxilla, resulting in premature tooth contact during the wax try-in.

An ROC was created to examine the effect of d values compared to the results of the wax try-in appointment. The AUC was 0.833 ($P < 0.05$), suggesting that d values were effective for verifying horizontal jaw records. The Youden Index was then calculated from the ROC to find the range of d values that could best be used to check the accuracy of recorded horizontal mandibular positions. The maximum d value was determined to be 1.0 mm; cast measurements greater than this limit were more likely to be incorrect and require new clinical jaw relation records to be taken. Using 1.0 mm as the threshold for success, the sensitivity and specificity of our test for predicting a successful wax try-in appointment were calculated. The sensitivity was 0.76 and the specificity was 0.93. When the result of the test was positive, the possibility of failure of the wax try-in was very high, making it necessary to determine the horizontal jaw relation again. If the jaw relation was found to be incorrect prior to arrangement of the teeth, this would reduce the overall treatment time and human cost. The sensitivity was not very high. If a false positive result was recorded, the relation would need to be recorded again, but this would not increase the visit time. If the result was positive twice, it might be considered as a false positive result.

A false positive result could appear in certain conditions. The test was based on the symmetrical position of the anatomical marks on the cast. If the patients' alveolar crest and centre of the pterygomaxillary notch and retromolar pad was highly deflective, a false positive result might be recorded. A false negative result might also arise. As the d value showed the right and left position of the horizontal relation, if the mandible was only protruded with no deflection, the result would be a false negative. Mandibular protrusion can occur in patients who have lost their posterior teeth and who

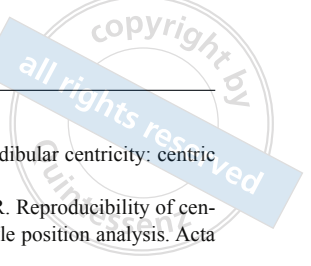
have chewed only with their anterior teeth for a long time. The method was therefore not suitable for all patients, and this was a limitation of the test.

In the test, it was important to trim the cast prior to measuring. The d value was used to evaluate positive or negative results. The distance between lines A' and B' was the midline of the bilateral lines A and B. As lines A and B were vertical to the base on the side of the cast, if the base of the cast was not parallel with the occlusal plane, it was difficult for lines A' and B' to bisect the maxillary and mandibular casts, and as a result the d values were not accurate. It was preferable to mount the cast on an articulator, if one was available, to make the cast plane more stable when measuring.

Digital technology is becoming increasingly popular, and it may be widely used in complete denture treatment in the future¹⁵. However, it is essential to check the jaw relation prior to tooth arrangement. Theoretically speaking, this method can also be incorporated into the digital fabrication of complete dentures. As digital technology has started to render accurate complete-arch scans and digital articulators can be used, computer programs could measure anatomical landmarks with greater accuracy. Jaw relations could be verified automatically prior to fabrication and thereby decrease processing errors. However, studies of methods used to check the horizontal jaw relation in digital denture design are currently lacking.

Conclusion

The test using pterygomaxillary notches and retromolar pads on casts to check horizontal jaw relation is reliable. If horizontal distance is measured as greater than 1.0 mm at the jaw relation record appointment, the recorded horizontal jaw relationship may be wrong and need to be reexamined.



Acknowledgements

We thank the Department of Restorative Dentistry at Peking University Hospital of Stomatology for their support in recruiting patients to participate in this study.

Conflicts of interest

The authors declare no conflicts of interest related to this study.

Author contribution

Dr Xi Xi ZHANG performed the experiment, the data analyses and wrote the manuscript; Dr Jian Zhang LIU contributed to the conception of the study and revised the manuscript; Drs Wen ZOU and Mei WANG helped to perform the experiment.

(Received Feb 29, 2020; accepted Jun 22, 2020)

References

1. Bansal S, Palaskar JN. Critical evaluation of methods to record centric jaw relation. *J Indian Prosthodont Soc* 2009;9:120–126.
2. James DA, George Z. The dentures' polished surfaces, recording jaw relations, and their transfer to an articulator. In: Zarb GA, Hobkirk JA, Eckert SE, Jacob RF (eds). *Prosthodontic Treatment for Edentulous Patients: Complete Dentures and Implant-supported Prosthodontics*, ed 13. St Louis: Mosby, 2012:190–192.
3. Becker CM, Kaiser DA, Schwalm C. Mandibular centricity: centric relation. *J Prosthet Dent* 2000;83:158–160.
4. Galeković NH, Fugošić V, Braut V, Čelić R. Reproducibility of centric relation techniques by means of condyle position analysis. *Acta Stomatol Croat* 2017;51:13–21.
5. The Glossary of Prosthodontic Terms: Ninth Edition. *J Prosthet Dent* 2017;117:e1–e105.
6. Celenza FV. The theory and clinical management of centric positions: I. Centric occlusion. *Int J Periodontics Restorative Dent* 1984;4:8–26.
7. Keshvad A, Winstanley RB. An appraisal of the literature on centric relation. Part I. *J Oral Rehabil* 2000;27:823–833.
8. Badel T, Ćimić S, Munitić M, Zadavec D, Kes VB, Šimunković SK. Clinical view of the temporomandibular joint disorder. *Acta Clin Croat* 2014;53:462–470.
9. Swenson AL, Oesterle LJ, Shellhart WC, Newman SM, Minick G. Condylar positions generated by five centric relation recording techniques. *Oral Biology Dent* 2014;2:1–8.
10. el-Aramany MA, George WA, Scott RH. Evaluation of the needle point tracing as a method for determining centric relation. *J Prosthet Dent* 1965;15:1043–1054.
11. Thakur M, Jain V, Parkash H, Kumar P. A comparative evaluation of static and functional methods for recording centric relation and condylar guidance: a clinical study. *J Indian Prosthodont Soc* 2012;12:175–181.
12. Keshvad A, Winstanley RB. Comparison of the replicability of routinely used centric relation registration techniques. *J Prosthodont* 2003;12:90–101.
13. Kandasamy S, Boeddinghaus R, Kruger E. Condylar position assessed by magnetic resonance imaging after various bite position registrations. *Am J Orthod Dentofacial Orthop* 2013;144:512–517.
14. Noble WH. Anteroposterior position of “Myo-Monitor centric”. *J Prosthet Dent* 1975;33:398–402.
15. Sun YC, Jin EL, Zhao T, Wang Y, Ye HQ, Zhou YS. Progress in research and application of the edentulous custom trays [in Chinese]. *Zhonghua Kou Qiang Yi Xue Za Zhi* 2016;51:698–701.