

# Polyetheretherketone Framework for Implant-supported Full-arch Fixed Dental Prostheses in a Periodontitis Patient with a 6-year Follow-up: a Case Report

Jing WANG<sup>1,#</sup>, Jun Ting GU<sup>1#</sup>, Meng MENG<sup>1</sup>, Chen Yu WANG<sup>1</sup>, Ji Hua CHEN<sup>1</sup>, Li Na NIU<sup>1</sup>

*Dental implants are widely used in the rehabilitation of patients with edentulous jaws caused by periodontitis. The success of implants is closely related to their framework material and patients' periodontal health. Polyetheretherketone (PEEK) is a kind of high polymer material that has broad prospects as the framework for full-arch dental prostheses, but long-term follow-up data are lacking. The present clinical report demonstrates the use of a PEEK framework for the construction of an implant-supported full-arch fixed dental prosthesis for a patient diagnosed with periodontitis. With the guidance of biological width, a provisional retained restoration was achieved to create the emergence profile, resulting in a 3D printed PEEK framework with good aesthetics and biological functions.*

**Key words:** gingival modification, high polymer framework, implant-supported fixed prosthesis, staged extraction

*Chin J Dent Res 2022;25(2):149–158; doi: 10.3290/j.cjdr.b3086345*

Periodontitis is a chronic infectious disease of the oral cavity and is the principal cause of tooth loss in the elderly<sup>1</sup>. Dental implants are an alternative to bridges or removable partial dentures in the rehabilitation of patients with periodontal disease; however, periodontitis is considered high risk for peri-implantitis<sup>2</sup>, which may result in treatment failure. It has been well reported that

the periodontal status adjacent to implants is an important factor that affects long-term implant outcomes<sup>3</sup>. Accordingly, implant treatment can only be successful in patients with periodontitis after they undergo periodontal therapy and achieve a stable periodontal status. In patients with periodontitis who have undergone periodontal treatment and are in their maintenance phase, the rate of clinical success of immediate implant placement and immediate provisional restoration is as high as 98.3%<sup>4</sup>.

Peri-implant gingival morphology is closely related to the aesthetics and biological function of implant restoration. Similar to the biological width (~2 mm) around natural teeth, the width (~3 mm) from the top of the peri-implant mucosa to the first point of bone-implant contact is also referred to as biological width around implants. This width is formed to resist external stimulation and provide a stable soft and hard tissue relationship around implants<sup>5</sup>. Gingival modification to form biological width in implant is therefore essential for implant prostheses, and is still a major challenge. Nowadays, digital technology can effectively analyse the relationship between the soft and hard tissues of the implant, which will be the future trend towards

1 National Clinical Research Centre for Oral Diseases & State Key Laboratory of Military Stomatology & Shaanxi Key Laboratory of Stomatology, Department of Prosthodontics, School of Stomatology, The Fourth Military Medical University, Xi'an, Shaanxi, P.R. China.  
# These authors contributed equally to this work.

**Corresponding authors:** Dr Ji Hua CHEN and Dr Li Na NIU, Department of Prosthodontics, School of Stomatology, The Fourth Military Medical University, 145th West Changle Road, Xi'an 710032, Shaanxi, P.R. China. Tel: 86-29-84776657; 86-29-84776468. Email: jhchen@fmmu.edu.cn; niulina831013@126.com

This study was supported in part by grants 61701520 and 81970971 from the National Nature Science Foundation of China, grant 2019M653969 from the China Postdoctoral Science Foundation, grant 2020TD-033 from the Shaanxi Key Scientific and Technological Innovation Team and by the Youth Innovation Team of Shaanxi Universities.

gingival shaping in the complete implant-supported fixed denture<sup>6</sup>.

Traditionally, implant-supported full-arch fixed dentures are manufactured with metal alloy frameworks; acrylic resin or porcelain teeth are then laid over the casted framework<sup>7</sup>. Such frameworks are mostly fabricated from cobalt-chromium alloy. Although the alloy has sufficient strength to withstand occlusal forces, it is not resistant to corrosion<sup>8</sup>. Cobalt-chromium frameworks have subsequently been replaced by titanium and zirconia frameworks that provide favourable biocompatibility, exceptional wear resistance and excellent corrosion resistance<sup>8-10</sup>. Unfortunately, titanium and zirconia frameworks have shown high stiffness<sup>11,12</sup>, which may lead to conduction of occlusal loading. The force around implants is greatly increased when the implant is connected with a rigid framework. The stress concentration is considered a risk factor for prosthesis failure and peri-implant bone loss. Due to the drawbacks of the aforementioned materials, a new generation of material is required for the preparation of implant-supported prosthetic frameworks.

Polyetheretherketone (PEEK) is a high temperature thermoplastic, semi-crystalline polymer with a high melting temperature<sup>12,13</sup>, which is widely suitable for CAD/CAM fabrication of various dental prostheses<sup>14</sup>. It has good biocompatibility and favourable resistance to wear and fatigue. In addition, PEEK can be easily chemically modified. This enables simple adjustment of its mechanical properties in accordance with requirements<sup>12</sup>. BioHPP (Bredent, Senden, Germany) is a PEEK-based, ceramic-reinforced high-performance polymer. It exhibits excellent polishing properties and wear resistance, with low plaque affinity<sup>15</sup>, and is therefore a good choice for the preparation of denture frameworks in patients with periodontitis.

The use of PEEK polymer material in dentistry has yet to gain momentum. In particular, the literature is sparse on long-term clinical studies of the use of PEEK in clinical dental practice. This case report presents a 6-year follow up of a patient with periodontitis who received restoration with an implant-supported full-arch fixed dental prosthesis fabricated with a PEEK framework.

### Case report

A 61-year-old, non-smoking man was referred to our department, with the chief complaint of mobility in his mandibular teeth. The patient had been suffering from loose teeth and masticatory dysfunction for 5 years, with teeth lost in both the anterior mandible and maxilla.

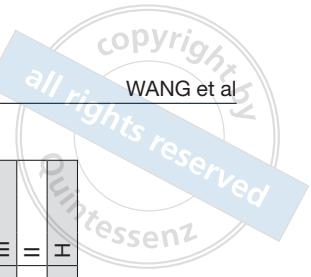
The intraoral examination identified generalised, severe plaque accumulation and heavy calculus deposits. Periodontal pocket depth ranged from 4 to 7 mm on probing. In the maxilla, the left central incisor had been lost and the right central and left lateral incisors exhibited class I mobility (i.e., < 1 mm horizontal movement) according to Miller's classification. In the mandible, the right central incisor had been lost; all the remaining teeth were mobile with class III mobility (i.e., > 2 mm horizontal or vertical mobility), with the exception of the left and right premolars, which exhibited class II mobility (> 1 mm horizontal movement) (Table 1, Fig 1a).

The radiographic examination showed severely resorbed alveolar bone due to periodontitis, with horizontal bone resorption to the middle of the roots in the maxilla. Bone resorption was more extensive in the mandible, with bone loss up to two-thirds of the root lengths. The mandibular right second molar, left canine and left first and second molars suffered from asymptomatic apical periodontitis with periapical radiolucencies (Fig 1b). The patient had a thick gingival biotype. There were 10 to 12 mm of available inter-ridge restorative space in the edentulous region for prosthesis construction (i.e., Class III vertical restorative space)<sup>16</sup>.

Several prosthodontic treatment plans were presented to the patient, including a removable denture, an implant-retained overdenture and an implant-supported fixed prosthesis. After understanding the advantages and disadvantages associated with each plan, the patient opted for an implant-supported fixed prosthesis in the mandible and a fixed partial denture in the maxilla.

The initial therapy involved controlling the periodontitis with periodontal treatment. The latter included oral hygiene instruction, scaling and root planning, according to the European Federation of Periodontology Clinical Practice Guidelines<sup>17</sup>. The maxillary teeth were restored as planned after periodontal treatment; however, all the mandibular teeth showed a poor prognosis after treatment. Herein, the mandible was planned to be restored with implant-supported full-arch fixed dental prostheses, after adequate communication with the patient.

CBCT (Orthophos XG 3D; Dentsply Sirona, Charlotte, NC, USA) was performed with a radiological diagnostic prosthesis, according to the dual-scan procedure outlined in the scanning protocol<sup>18</sup>. The obtained DICOM file was matched with data acquired from an intraoral scanner (D2000 3D Scanner, 3Shape, Copenhagen, Denmark). The implant template was designed using implant planning software (GuideMia Technologies, Los Alamitos, CA, USA) and fabri-



cated using a 3D printer (ProJet MJP 3600 Dental, 3D Systems, Rock Hill, SC, USA) with surgical guide resin (VisiJet MP200, VisiJet M3 Stoneplast, SD Systems (New York, NY, USA).

All the mandibular teeth were extracted 1 month prior to implant surgery, except for the canines and second molars. After delivery of local anaesthesia, an implant guide supported by the teeth and mucosa was used for preparation of the implantation fossae. The mandibular canines were then extracted. An incision was made on the mandibular alveolar crest by raising a full-thickness flap. Six 3.3 mm diameter bone-level implants (Straumann, Basel, Switzerland) were placed. Insertion torque of 35 Ncm was placed on the prosthetic screws (Fig 2).

An implant-level impression was made immediately after implant placement. The multiunit impression copings were splinted together using stainless-steel bars and auto-polymerising acrylic resin (GC Pattern Resin, GC, Tokyo, Japan). Immediate impressions were taken using an addition silicone impression material (Virtual Heavy Body, Ivoclar Vivadent, Schaan, Lichenstein). The interocclusal centric relationship was registered using a conventional occlusal wax rim. The mandibular second molars were extracted after the record was taken. The accuracy of implants was checked using CBCT (Fig 3). An interim restoration, consisting of individual artificial teeth and heat-polymerised acrylic resin (Trevalon, Dentsply Sirona), was designed and fabricated using CAD/CAM (GuideMia Technologies) (Fig 4). The ridge of the pontic was designed to be laid 2.3 mm above the alveolar crest, and the rest of the pontic was designed following the morphology of the alveolar bone. The interim restoration was delivered immediately after the surgical operation to restore masticatory function and aesthetics during the recovery period.

Prior to construction of the definitive restoration, the morphology of the pontic site and mucosa around implants of the interim restoration were modified according to the oral soft tissue 3 and 6 months after implant surgery. After that, information on gingival morphology was collected by scanning the final version of the modified interim restoration (D2000 3D Scanner, 3Shape). This information was duplicated to the permanent prosthesis. A definitive impression was taken with addition silicone impression material (Virtual Heavy Body and Virtual Light Body, Ivoclar Vivadent) using splinted open-tray impression copings and the final interocclusal relationship was recorded. The definitive prosthesis consisted of a fixed implant-supported prosthesis with individual artificial resin

**Table 1** Pretreatment periodontal chart.

Prognosis	Q	Q	F	F	F	F	Q	Q	Q	F	F	F	F	Q	Q	Q
Plaque	II	I	I	I	I	I	I	I	I	I	I	I	I	I	I	I
Mobility	I	-	-	-	-	-	-	-	-	-	-	-	-	-	-	-
BOP	+	+	-	-	-	-	+	+	+	+	+	+	+	+	+	+
BS	5	3	6	5	3	3	2	3	3	2	3	3	2	3	3	3
PS	5	3	4	5	3	3	4	3	2	2	2	2	2	2	3	4
Tooth number	17	16	15	14	13	12	11	21	22	23	24	25	26	27	28	29
LS	47	46	45	44	43	42	41	31	32	33	34	35	36	37	38	39
PPD, mm	6	3	7	4	3	3	2	5	4	3	4	3	4	3	4	5
BOP	5	5	6	4	4	3	3	4	3	3	4	3	4	3	4	5
Mobility	+	+	+	+	+	+	+	+	+	++	+	+	+	+	+	+
Plaque	III	III	III	III	III	III	III	III	III	III	III	III	III	III	III	III
Prognosis	II	I	I	I	I	I	I	I	I	I	I	I	I	I	I	I
Prognosis	H	H	P	P	H	H	H	H	H	H	P	P	H	H	H	H

BOP, bleeding on probing; BS, buccal side; F, fair; H, hopeless; LS, lingual side; P, poor; PPD, periodontal probing depth; PS, palatal side; Q: questionable.

I or II for plaque indicates the Plaque Index, and for mobility it indicates the degree of tooth mobility.

+ means that BOP is positive and - means it is negative.

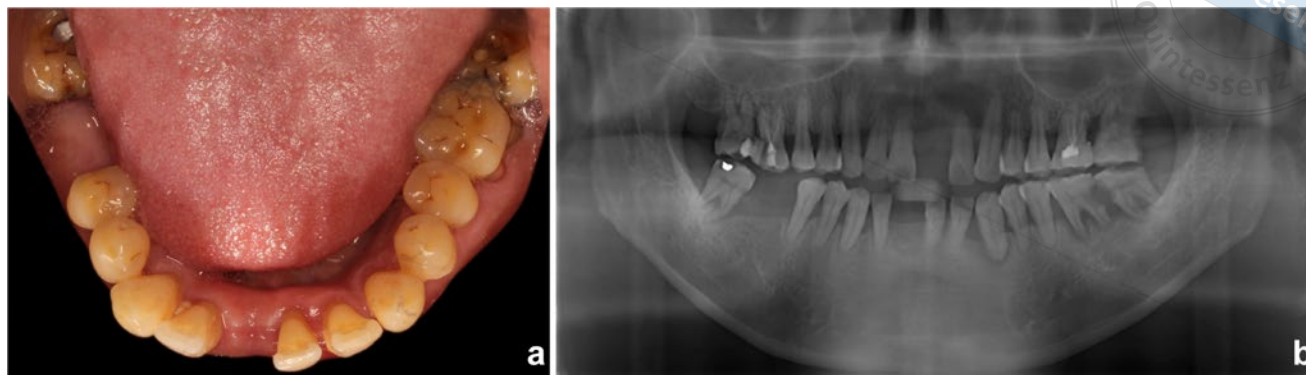


Fig 1 Pretreatment photographs: (a) intraoral view of the mandible and (b) panoramic radiograph of the initial dental status.

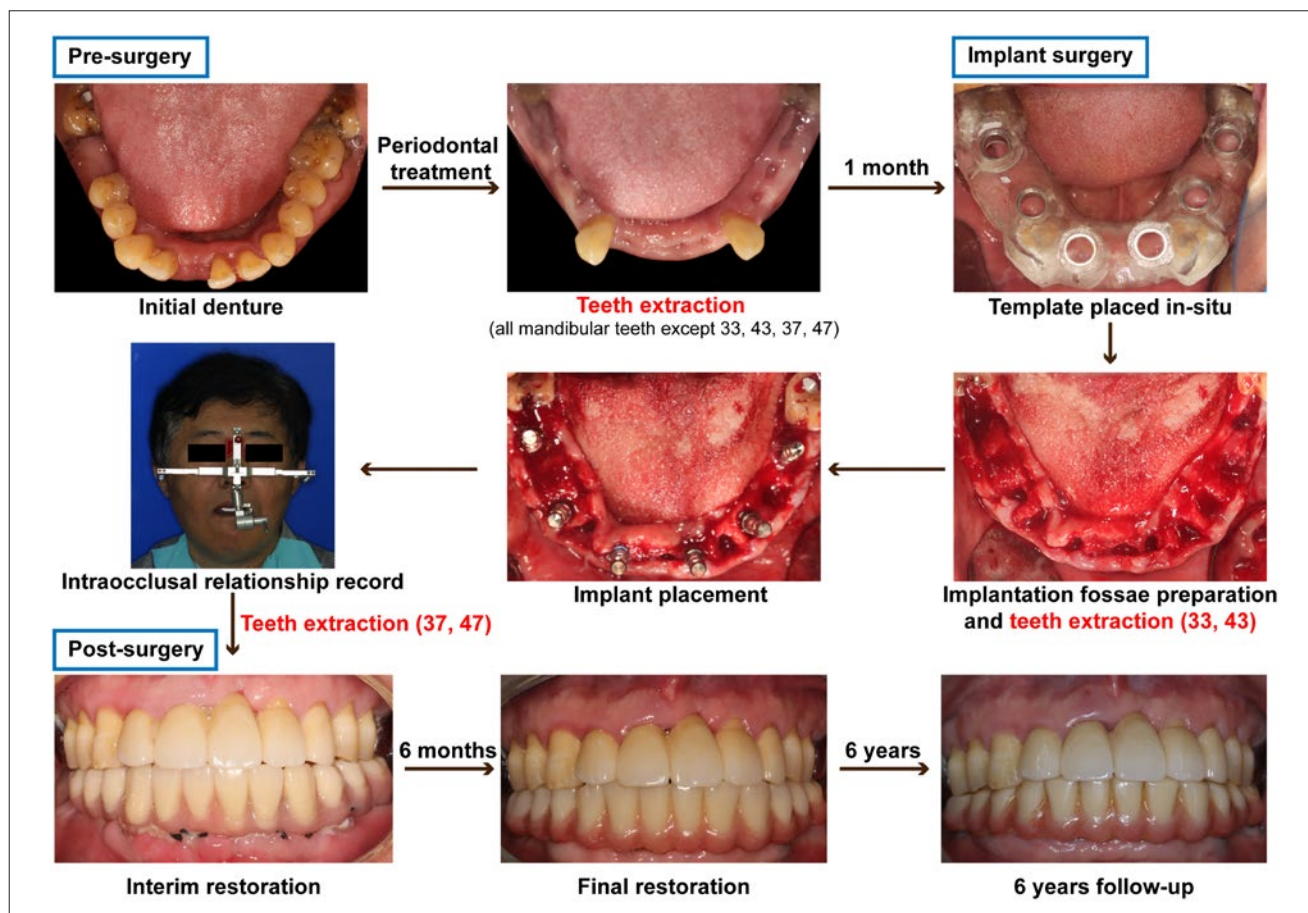
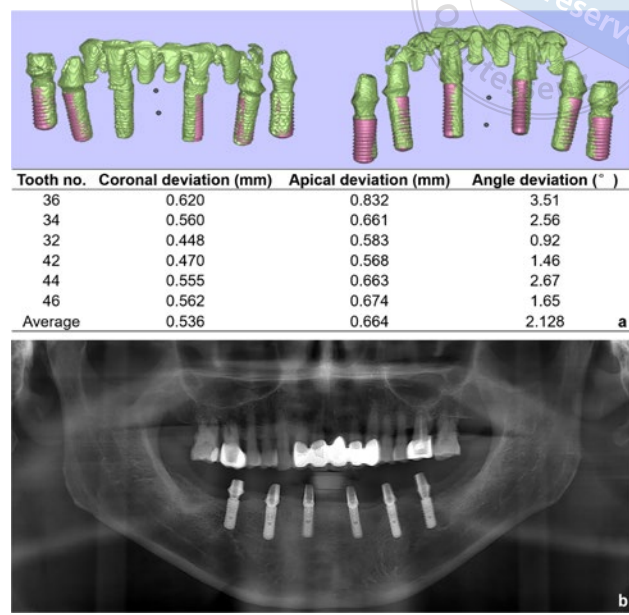


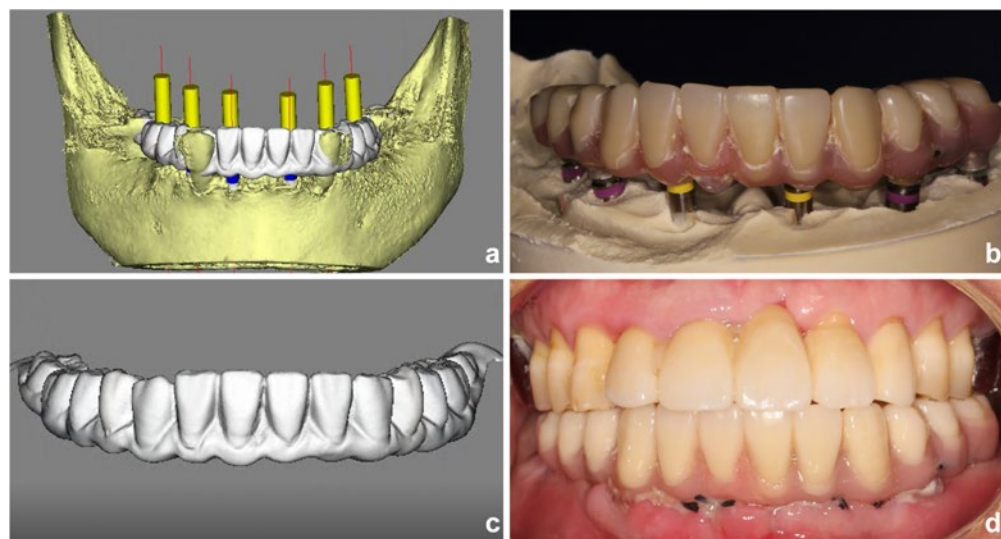
Fig 2 Treatment procedure.

teeth (neo.lign, Bredent), and polymethyl methacrylate (PMMA) veneers (neo.lign) laid over a PEEK framework (breCAM.BioHPP, Bredent) (Fig 5). The adhesive procedures were as follows. First, the PEEK framework was conditioned as per the instructions. It was airborne-particle abraded at a pressure of 2 to 3 MPa using 110 μm aluminium oxide wetted with primer (visio.link,

Bredent) followed by light-curing, then covered by a lamella of the opaquer (Opaquer combo.lign, Bredent), polymerised in the light-curing unit. Meanwhile, the PMMA veneer was also airborne-particle abraded and primer conditioned using the same protocol with the PEEK framework. After that, the veneer was cemented to the framework using the tooth shade cement (combo.



**Fig 3** (a) Deviation of implant placement from the design and (b) panoramic radiograph after final implantation.



**Fig 4** (a to c) CAD/CAM of the interim prostheses, (d) panoramic intraoral view after restoration of the interim prostheses.

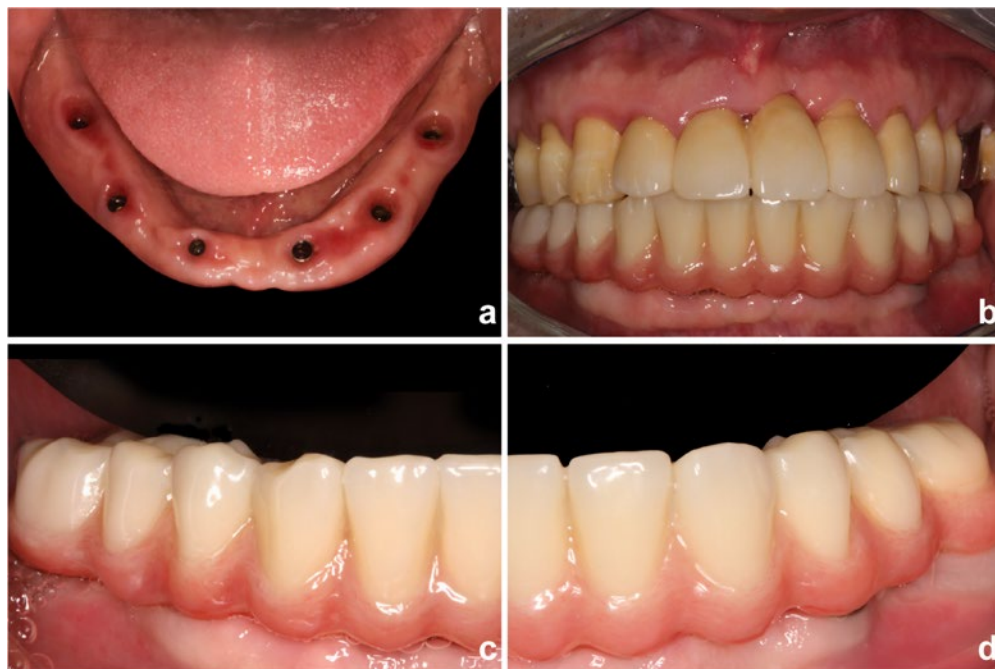
lign, Bredent) and subsequently polymerised using the light-curing unit.

After the entire implant procedure, an occlusal splint was made to protect the prostheses. Over the 6-year follow-up, the patient's periodontal condition remained stable with no signs of inflammation or bleeding. The mandibular implants were firm and stable, with negligible bone resorption (Table 2 and Fig 6). There was no swelling or recession of the adjacent gingivae. The patient indicated that his chewing efficacy was significantly improved after insertion of the prosthesis and was satisfied with the aesthetic results; however, veneer collapse was found on the posterior area of the mandibular prostheses. According

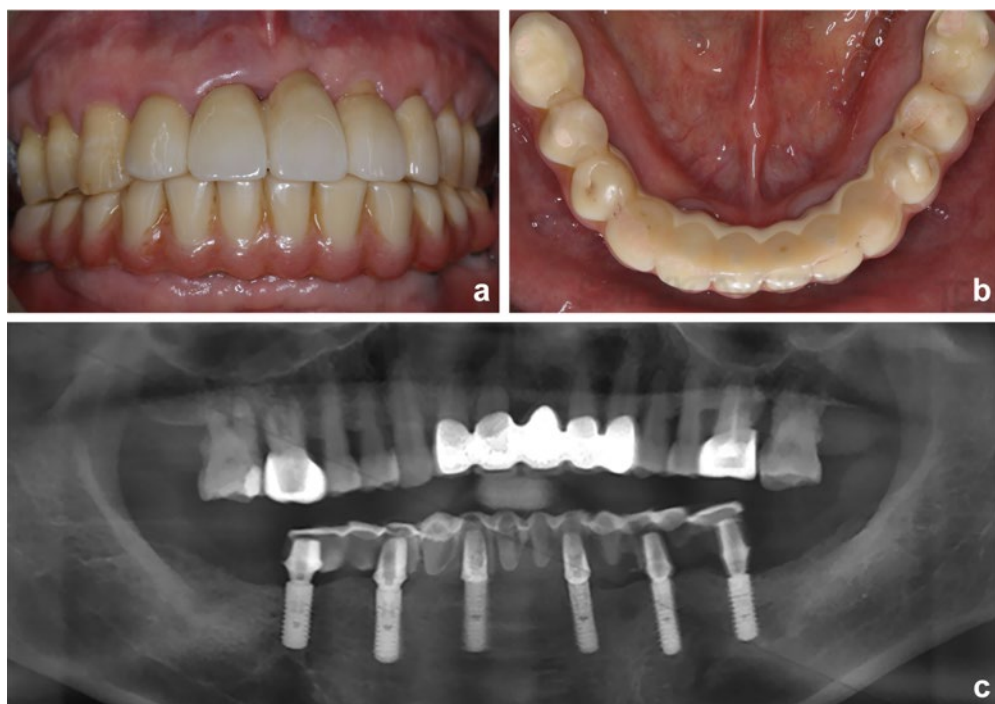
to our clinical experience, the veneer damage in the left posterior region of the prostheses was considered to have worn off, while in the right region it was thought to have chipped off. Even though veneer collapse occurred, the implant could still be considered a 6-year success, based on the commonly accepted criteria of implant success<sup>19</sup>.

### Discussion

Periodontitis causes attachment loss and alveolar bone destruction, ultimately resulting in tooth loss. Patients with periodontitis usually have poor oral hygiene and extensive plaque accumulation and are prone to peri-



**Fig 5** (a) Occlusal, frontal and lateral views on the day of delivery showing healthy peri-implant mucosal conditions and (b to d) the final reconstruction in situ.



**Fig 6** Posttreatment photographs from the 6-year follow-up: (a) intraoral panoramic view, (b) occlusal view of the prosthesis and (c) panoramic radiograph.

implantitis<sup>2</sup>. Multiple investigations have illustrated that poor periodontal status adjacent to implants results in implant treatment failure<sup>3,20</sup>. Preoperative periodontal treatment is therefore necessary to achieve a healthy periodontal condition prior to implant surgery. According to the European Federation of Periodontology Clinical Practice Guidelines<sup>17</sup>, the treatment continued with

bleeding on probing < 10%, shallow probing depths of  $\leq 4$  mm and no 4-mm pockets with bleeding on probing. Such a periodontal condition is considered a prerequisite for implant placement. Besides, the patient should be subjected to a stringent periodontal maintenance scheme over the entire implant treatment procedure to achieve a favourable long-term outcome<sup>17</sup>.



become an essential tool in prosthesis design<sup>6</sup>. In the present case, a provisional restoration with a margin located 2.3 mm above the alveolar bone was designed and fabricated by CAD/CAM according to the patient's computed tomography data. We combined the digital impression and provisional restoration, forming a suitable biological width around the implants.

As a new generation of implant material, PEEK has the following advantages. First, it is white in colour and eliminates the greyish hue of metal frameworks to produce a more aesthetic outcome<sup>29</sup>. The material is comparable to bone in terms of mechanical and physical properties<sup>12</sup>. Hence, the PEEK framework here was combined with the high-strength resin teeth, aiming to reduce the stress concentration caused by natural maxillary teeth to reduce relative complications. It is also resistant to wear and has a high survival rate<sup>13</sup>. Because PEEK is insoluble in water, a PEEK framework does not have a metallic taste. For these reasons, a PEEK-based prosthetic framework has a high level of patient acceptance<sup>29</sup>. In addition, PEEK is highly biocompatible and causes fewer inflammation effects and less plaque accumulation<sup>15</sup>.

There are still some limitations concerning the applications of PEEK. First, PEEK blanks are a greyish-brown or pearl-white opaque colour and are unsuitable for monolithic aesthetic dental restorations, especially in the anterior region<sup>13</sup>. Thus, veneering is required, but bonding to veneering composite resin materials remains a challenge because of the complex chemical structure of PEEK. Besides, in contrast to titanium, PEEK has very limited inherent osteoconductive properties<sup>30</sup>. Although unmodified PEEK is considered as a bio-inert material, there is no conclusive evidence of the osteoconductive effects of PEEK *in vivo* and *in vitro*. Moreover, prostheses with a PEEK framework are still at risk of mechanical complications.

In the present case, the veneer collapse happened in the posterior region after a 6-year follow-up. Veneer fracture is the most common mechanical complication for prostheses with a PEEK framework, which emphasises the imperfect bonding between the framework and PMMA veneer<sup>11</sup>. As PEEK is characterised by an inert surface, surface pretreatment is crucial for successful bonding with the veneer<sup>31,32</sup>. It was reported that the shear bond strength between pure PEEK substrate (without surface pretreatment) and PMMA veneer was only 0.7 to 18.2 MPa, and that after surface pretreatment, the shear bond strength between the veneer and PEEK can be increased to about 30 MPa or more<sup>33</sup>. The surface pretreatments include airborne-particle abrasion, silica coating and laser, among which airborne-particle abra-

sion was proven to provide superior pretreatment of PEEK<sup>34</sup>. Besides, the bond strength is also related to the adhesive system. The prosthesis using the visio.link adhesive system, which contains methyl methacrylate and 2-propenoic acid reaction products with pentaerythritol and diphenyl (2,4,6-trimethylbenzoyl)-phosphine oxide<sup>35</sup>, was proven to show a favourable survival rate<sup>36</sup>. Thus, in the present case, the PEEK surface was airborne-particle abraded and treated with a visio.link prime and an opaquer catalyst (Bredent) to improve bonding between the methacrylate veneer and the PEEK framework. In addition, an implant protective occlusion splint was applied to protect the prostheses by reducing the tension from the occlusal force on it<sup>37</sup>. The occlusal splint could help move stress forward towards the bone structure to protect the prostheses and maintain implants for the long term<sup>38</sup>. The patient did not wear the occlusal splint as advised, and veneer collapse still happened. Thus, further studies are required to eliminate the occurrence of veneer collapse.

Microcracks are another commonly occurred mechanical complication encountered with the PEEK framework<sup>11</sup>, which might be related to the fatigue behaviour of PEEK<sup>33</sup>. To address this drawback, some reinforced materials were introduced to improve the fatigue performance of PEEK. Appropriate design and standardised manufacturing might also be conducive to preventing cracks, including enough inter-ridge space, proper thickness of frameworks, and so on<sup>11</sup>. Thus, further studies should emphasise the relationship between the design of the PEEK framework and its integrity.

The limitations of the present study include the fact that this was a case report with only one patient, and that it was conducted 6 years ago. At that time, the relevant technology was not sufficiently developed. The 3D printing of PEEK frameworks was not developed enough, which may have led to deficiencies in framework production, and the multiunit abutment (Screw Retained Abutment; Straumann) was not available in China 6 years ago. As such, we could only choose implant-level impression, which may have caused unsatisfactory precision. Further research should focus on long-term studies with a bigger sample size to fully confirm the validity of the PEEK framework applied in patients with periodontitis.

## Conclusion

In the present case, a patient with chronic periodontitis received a PEEK framework containing an implant-supported full-arch fixed prosthesis after appropriate periodontal treatment. At the 6-year follow-up, the patient



was satisfied with the prosthesis and there was no recurrence of periodontitis or peri-implantitis. Within the limitations of this study, full-arch prostheses with PEEK framework can represent a good alternative treatment choice for patients with periodontitis. To further evaluate the clinical effectiveness of this treatment option, studies with a larger sample size and over a longer period are required.

### Conflicts of interest

The authors declare no conflicts of interest related to this study.

### Author contribution

Dr Jing WANG contributed to the surgery, data collection and concept; Dr Jun Ting GU contributed to the original draft preparation and data interpretation; Drs Meng MENG and Chen Yu WANG contributed to the surgery and data analysis; Dr Ji Hua CHEN and Dr Li Na NIU contributed to the manuscript revision, funding acquisition and project administration.

(Received Jun 11, 2021; accepted Dec 02, 2021)

### References

1. Nilsson H, Sanmartin Berglund J, Renvert S. Longitudinal evaluation of periodontitis and tooth loss among older adults. *J Clin Periodontol* 2019;46:1041–1049.
2. Ferreira SD, Martins CC, Amaral SA, et al. Periodontitis as a risk factor for peri-implantitis: Systematic review and meta-analysis of observational studies. *J Dent* 2018;79:1–10.
3. Sung CE, Chiang CY, Chiu HC, Shieh YS, Lin FG, Fu E. Periodontal status of tooth adjacent to implant with peri-implantitis. *J Dent* 2018;70:104–109.
4. Sicilia-Felechosa A, Pereira-Fernández A, García-Lareu J, Bernardo-González J, Sicilia-Blanco P, Cuesta-Fernández I. Flapless immediate implant placement and provisionalization in periodontal patients: A retrospective consecutive case-series study of single-tooth sites with dehiscence-type osseous defects. *Clin Oral Implants Res* 2020;31:229–238.
5. Berglundh T, Lindhe J, Ericsson I, Marinello CP, Liljenberg B, Thomsen P. The soft tissue barrier at implants and teeth. *Clin Oral Implants Res* 1991;2:81–90.
6. Monaco C, Evangelisti E, Scotti R, Mignani G, Zucchelli G. A fully digital approach to replicate peri-implant soft tissue contours and emergence profile in the esthetic zone. *Clin Oral Implants Res* 2016;27:1511–1514.
7. Bagegni A, Abou-Ayash S, Rucker G, Algarny A, Att W. The influence of prosthetic material on implant and prosthetic survival of implant-supported fixed complete dentures: A systematic review and meta-analysis. *J Prosthodont Res* 2019;63:251–265.
8. Jiang X, Yao Y, Tang W, et al. Design of dental implants at materials level: An overview. *J Biomed Mater Res A* 2020;108:1634–1661.
9. Schulze C, Weinmann M, Schweigel C, Keßler O, Bader R. Mechanical properties of a newly additive manufactured implant material based on Ti-42Nb. *Materials (Basel)* 2018;11:124.
10. Pozzi A, Holst S, Fabbri G, Tallarico M. Clinical reliability of CAD/CAM cross-arch zirconia bridges on immediately loaded implants placed with computer-assisted/template-guided surgery: A retrospective study with a follow-up between 3 and 5 years. *Clin Implant Dent Relat Res* 2015;17(suppl 1):e86–e96.
11. Wang J, Wu P, Liu HL, et al. Polyetheretherketone versus titanium CAD-CAM framework for implant-supported fixed complete dentures: A retrospective study with up to 5-year follow-up [epub ahead of print 30 September 2021]. *J Prosthodont Res* doi: 10.2186/jpr.JPR\_D\_20\_00142.
12. Knaus J, Schaffarczyk D, Cölfen H. On the future design of bio-inspired polyetheretherketone dental implants. *Macromol Biosci* 2020;20:e1900239.
13. Najeeb S, Zafar MS, Khurshid Z, Siddiqui F. Applications of polyetheretherketone (PEEK) in oral implantology and prosthodontics. *J Prosthodont Res* 2016;60:12–19.
14. Papathanasiou I, Kamposiora P, Papavasiliou G, Ferrari M. The use of PEEK in digital prosthodontics: A narrative review. *BMC Oral Health* 2020;20:217.
15. Bathala L, Majeti V, Rachuri N, Singh N, Gedela S. The role of polyether ether ketone (peek) in dentistry – A review. *J Med Life* 2019;12:5–9.
16. Ahuja S, Cagna DR. Classification and management of restorative space in edentulous implant overdenture patients. *J Prosthet Dent* 2011;105:332–337.
17. Sanz M, Herrera D, Kerschull M, et al. Treatment of stage I-III periodontitis – The EFP S3 level clinical practice guideline. *J Clin Periodontol* 2020;47(suppl 22):4–60.
18. D'haese J, Van De Velde T, Elaut L, De Bruyn H. A prospective study on the accuracy of mucosally supported stereolithographic surgical guides in fully edentulous maxillae. *Clin Implant Dent Relat Res* 2012;14:293–303.
19. Papaspyridakos P, Chen CJ, Singh M, Weber HP, Gallucci GO. Success criteria in implant dentistry: A systematic review. *J Dent Res* 2012;91:242–248.
20. Do TA, Le HS, Shen YW, Huang HL, Fuh LJ. Risk factors related to late failure of dental implant-A systematic review of recent studies. *Int J Environ Res Public Health* 2020;17:3931.
21. Lanza A, Scognamiglio F, Femiano F, Lanza M. Immediate, early, and conventional implant placement in a patient with history of periodontitis. *Case Rep Dent* 2015;2015:217895.
22. Hämmerle CH, Chen ST, Wilson TG Jr. Consensus statements and recommended clinical procedures regarding the placement of implants in extraction sockets. *Int J Oral Maxillofac Implants* 2004;19(suppl):26–28.
23. Palmer R. Evidence for survival of implants placed into infected sites is limited. *J Evid Based Dent Pract* 2012;12(3, suppl):187–188.
24. Abdunabi A, Morris M, Nader SA, Souza RF. Impact of immediately loaded implant-supported maxillary full-arch dental prostheses: A systematic review. *J Appl Oral Sci* 2019;27:e20180600.
25. Eckert SE, Hueler G, Sandler N, Elkattah R, McNeil DC. Immediately loaded fixed full-arch implant-retained prosthesis: Clinical analysis when using a moderate insertion torque. *Int J Oral Maxillofac Implants* 2019;34:737–744.
26. Alfadda SA, Chvartszaid D, Tulbah HI, Finer Y. Immediate versus conventional loading of mandibular implant-supported fixed prostheses in edentulous patients: 10-year report of a randomised controlled trial. *Int J Oral Implantol (Berl)* 2019;12:431–446.
27. Gallardo YNR, da Silva-Olivio IR, Gonzaga L, Sesma N, Martin W. A systematic review of clinical outcomes on patients rehabilitated with complete-arch fixed implant-supported prostheses according to the time of loading. *J Prosthodont* 2019;28:958–968.

28. Pozzi A, Tallarico M, Moy PK. The implant biologic pontic designed interface: Description of the technique and cone-beam computed tomography evaluation. *Clin Implant Dent Relat Res* 2015;17(suppl 2): e711–e720.
29. Zoidis P. The all-on-4 modified polyetheretherketone treatment approach: A clinical report. *J Prosthet Dent* 2018;119:516–521.
30. Rabiei A, Sandukas S. Processing and evaluation of bioactive coatings on polymeric implants. *J Biomed Mater Res A* 2013;101:2621–2629.
31. Miyagaki A, Kamaya Y, Matsumoto T, et al. Surface modification of poly(ether ether ketone) through Friedel-Crafts reaction for high adhesion strength. *Langmuir* 2019;35:9761–9768.
32. Gama LT, Duque TM, Özcan M, Philippi AG, Mezzomo LAM, Gonçalves TMSV. Adhesion to high-performance polymers applied in dentistry: A systematic review. *Dent Mater* 2020;36:e93–e108.
33. Ji S, Sun C, Zhao J, Liang F. Comparison and analysis on mechanical property and machinability about polyetheretherketone and carbon-fibers reinforced polyetheretherketone. *Materials (Basel)* 2015;8:4118–4130.
34. Caglar I, Ates SM, Yesil Duymus Z. An in vitro evaluation of the effect of various adhesives and surface treatments on bond strength of resin cement to polyetheretherketone. *J Prosthodont* 2019;28:e342–e349.
35. visio.lign – The esthetic and functional system by bredent group. bond.lign – Primer/Bonder. <https://www.visiolign.com/bond-lign>. Accessed 30 April 2022.
36. Stawarczyk B, Taufall S, Roos M, Schmidlin PR, Lümekemann N. Bonding of composite resins to PEEK: The influence of adhesive systems and air-abrasion parameters. *Clin Oral Investig* 2018;22:763–771.
37. Teixeira FM, de Assis Claro CA, Neves AC, de Mello Rode S, da Silva-Concilio LR. Influence of loading and use of occlusal splint in implant-supported fixed prostheses. *J Craniofac Surg* 2012;23: e477–e480.
38. Dos Santos Marsico V, Lehmann RB, de Assis Claro CA, et al. Three-dimensional finite element analysis of occlusal splint and implant connection on stress distribution in implant-supported fixed dental prosthesis and peri-implant bone. *Mater Sci Eng C Mater Biol Appl* 2017;80:141–148.