

Endodontic Anatomy of Human Mandibular Canines: Three Case Reports

Davide MANCINO^{1,2}, Naji KHAROUF¹

Mandibular canines are usually considered to be single-canal teeth. However, more than one canal and, more rarely, two roots may also occur. Three clinical cases are reported in order to illustrate endodontic anatomical variants in the human mandibular canine. All procedures were performed in conformity with the current state-of-the-art practices in endodontics, which included effective local anaesthesia, rigorous clinical and radiographic pre-access analysis, appropriate tooth restoration to ensure watertight rubber dam installation and surgical microscopic manipulations for precision. The first case involved a mandibular canine with only one root but two canals, including a lateral canal. The second case was a retreatment of a mandibular canine with two roots, two canals and a broken stainless steel K-File in the buccal canal. The third case involved a mandibular canine that revealed a rare root canal configuration (1-3-1): a Sert and Bayirli's type XVII canal. To avoid missing the presence of any root canals in endodontic treatment, clinicians should have a thorough knowledge of the anatomic variants of the root canal system and should take the necessary time to perform a rigorous pre-access analysis. The systematic use of a surgical microscope and ultrasonic endodontic tips facilitates and standardises access cavity preparation and canal localisation.

Key words: endodontic anatomy, mandibular canine, pre-access analysis
Chin J Dent Res 2019;22(2):139–143; doi: 10.3290/j.cjdr.a42518

The essential prerogative for a successful endodontic treatment is the clinician's sound knowledge of the endodontic anatomy with its frequent variations and complexities. If an endodontic treatment is unsuccessful due to the failure in the treatment of a few millimeters of pulp tissue, it is easy to understand how the failure involving a whole canal system can negatively influence the outcome of the entire therapy. The internal anatomy of root canals is rarely as simple as the external morphology of teeth, and human mandibular canines are no exception¹⁻⁴. Even though they are usually considered to be single-rooted teeth with a single root canal, man-

dibular canines may sometimes have two canals and, more rarely, two roots. These anatomical variations are confirmed in the literature. The incidence of two canals in one root ranges from 6.1% to 24%. More precisely, according to the classification by Vertucci⁷, the incidence of type I ranges from 78.8% to 92.2%, type II from 2% to 14%, type III from 2% to 13.7% and type IV from 0% to 14%. The incidence of two canals in two roots ranges from 0% to 5%^{1,5-14}. In addition, lateral ramifications of the root canal system may frequently occur, increasing the probability of untreated spaces being left after the root canal therapy¹¹.

The three clinical cases reported in this article describe the endodontic treatment of three mandibular canines with uncommon anatomy: a mandibular canine with only one root but two canals, including a lateral canal; a retreatment of a mandibular canine with two roots, two canals and a broken stainless steel K-File in the buccal canal; and a mandibular canine that revealed a rare root canal configuration (1-3-1): a Sert and Bayirli's type XVII canal⁵.

1 Université de Strasbourg, Inserm UMR1121 Biomatériaux, et Bioingénierie, FMST, F-67000 Strasbourg, France.

2 Les Hôpitaux Universitaires de Strasbourg, F-67000 Strasbourg, France.

Corresponding author: Dr Davide MANCINO, 3 rue de l'Yser, 90000 Belfort, France; Tel: 0033(0) 370047388; Fax: 0033(0) 370047388; Email: ilpancia@cegetel.net

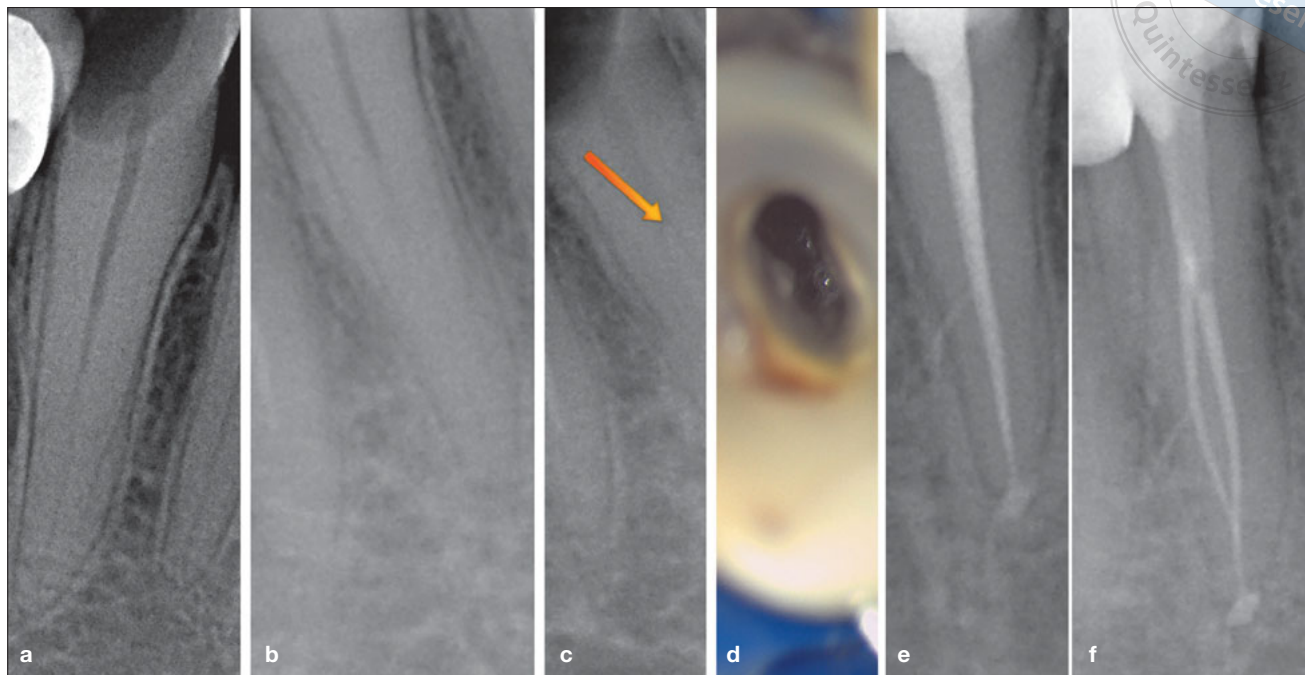


Fig 1 (a) Preoperative orthoradial radiograph showing one root and one canal. (b) Angulated radiograph showing the disappearance of the root canal pulp space, indicating a bifurcation. (c) Arrow highlighting the point of bifurcation. (d) Intraoperative photograph of the pulp chamber. (e) Postoperative orthoradial radiograph. (f) Postoperative angulated radiograph.

Case reports

Case 1

A 78-year-old Caucasian female was referred to the Clinic of Endodontics, Dental School, University of Strasbourg. Her medical history was unremarkable with no findings that could contribute to treatment problems. She presented with severe pain in the right mandible. The mandibular canine responded to pulp testing procedures. All procedures were carried out in conformity with current state-of-the-art practices in endodontics, including effective local anaesthesia, rigorous clinical and radiographic pre-access analysis, appropriate tooth restoration to ensure watertight rubber dam installation and manipulations with a surgical microscope (Leica M320) for precision.

For this mandibular canine, three preoperative radiographs with different angulations were taken. The periapical radiographic examination with an orthoradial projection showed the presence of only one root and one root canal (Fig 1a). However, the angulated radiographs revealed the presence of a second root canal (Fig 1b and c). The cementoamel junction (CEJ) was identified by using a periodontal probe. This allowed the practitioner a three-dimensional

(3D) view of the pulp canal system before the start of treatment¹¹.

After rubber dam placement, the endodontic access cavity preparation was started with a #012 cylindrical diamond drill and enlarged with a Start-X 1 (Dentsply Sirona) ultrasonic tip. The lingual and buccal root canal orifices were localised and enlarged with the same tip (Fig 1d). Then, keeping the pulp chamber constantly flooded with 6% sodium hypochlorite, root canal shaping was performed using a modern step-down technique without initial manual scouting, as follows: 1) Initial preflaring until 2/3 of the estimated radiographic working length (WL) with an in-and-out movement; 2) Apical scouting; 3) Glide path; 4) Shaping. The initial mechanical preflaring was performed at first with a ProGlider (PG) (Dentsply Sirona) to above the first root canal curvature with an in-and-out movement using an endodontic engine (300 rpm/5 Ncm). Thanks to the initial preflaring, using a #10 stainless steel K-file (Dentsply Sirona), the canal was easily scouted up to WL + 0.5 mm. Length determination was taken using an electronic apex locator (Root ZX; J. Morita Co., Kyoto, Japan). A mechanical glide path with the PG at WL was performed.

Root canal shaping was performed by preparing the buccal canal to WL with ProTaper Next X1 (PTX1)

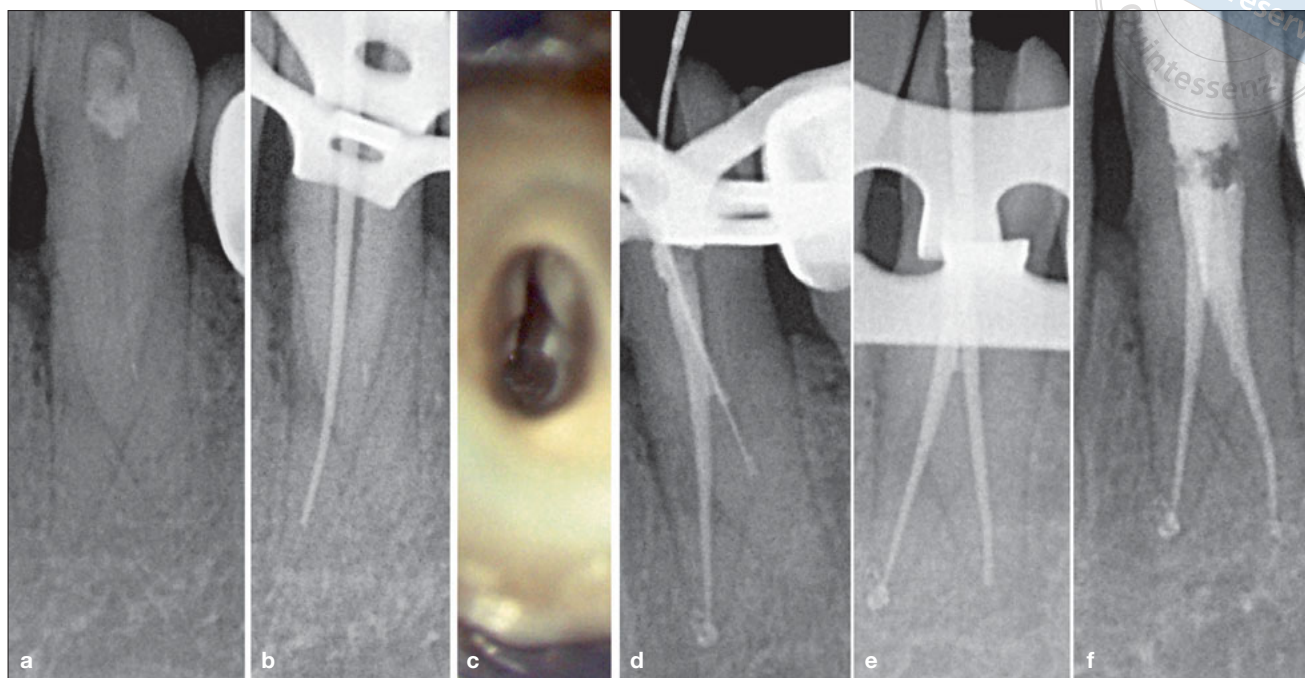


Fig 2 (a) Preoperative orthoradial radiograph showing two roots, two canals and a broken stainless steel #10 K-File in the buccal root. (b) WL using plastic carriers as verifiers in the lingual root canal. (c) Perioperative photograph of the pulp chamber. (d) Lingual canal filled; in the buccal canal the #10 K-File cannot bypass the separated instrument. (e) WL using plastic carriers as verifiers in the buccal root canal. (f) Postoperative orthoradial radiograph.

(Dentsply Sirona), ProTaper Next X2 (PTX2) (Dentsply Sirona), operating at 300 rpm and at a torque of 5 N/cm, 2.5-mm short of the WL and Profile (PF) 25/04 (Dentsply Sirona), 300 rpm/3 Ncm until the WL. To avoid an apical zip, the lingual canal was shaped until the point where it merged with the buccal canal using PTX1 and PF 25/04.

After the shaping procedure, in order to assure a 3D cleaning of the root canal system, an aqueous 17% solution of EDTA was flooded into the pulp chamber using EndoActivator (Dentsply Sirona) for 120 s, then rinsing took place with physiological saline, followed by a 6% solution of NaOCl for 120 s.

The canal was dried using sterile paper points. After applying a drop of AH Plus root canal sealer (Dentsply Sirona) with a coated paper point in the entrance of the canal, both canals were filled with Thermafil 25 (Dentsply Sirona) (Fig 1e). The final radiographs showed two well-obtured canals and the lateral canal of this single-rooted canine: a Vertucci Type III root canal configuration⁷ (Fig 1f).

Case 2

A 52-year-old Caucasian female was referred to the Clinic of Endodontics, Dental School, University of

Strasbourg for retreatment of tooth 33. Her medical history was unremarkable. She presented with severe pain in the left mandible. The periapical radiographic examination revealed the presence of two roots and a broken stainless steel K-File in the buccal canal (Fig 2a). The endodontic treatment was performed in two sessions.

During the first session, correct pulp chamber access was carried out. After the location of the lingual canal and the orifices of the buccal canal with a Start-X 1, the lingual canal was treated first using the same technique as for Case 1, except for the use of PTX2 to WL after PTX1 (Fig 2b and c). The buccal canal was treated in the second session. In order to improve access to the canal, an instrument from the ProTaper Universal system (ProTaper SX; Dentsply Sirona) was used at 300 rpm/5 Ncm. After an attempt at bypassing the broken K-File had failed, the file was removed using ProUltra Endo Tip #7 (Dentsply Sirona) (Fig 2d and e). The manual scouting was performed using a #10 stainless steel K-File, then the preflaring with a PG, and finally the shaping with PTX1 and PTX2. The postoperative radiographs showed two well-obtured canals, filled using the Thermafil system (Fig 2f).

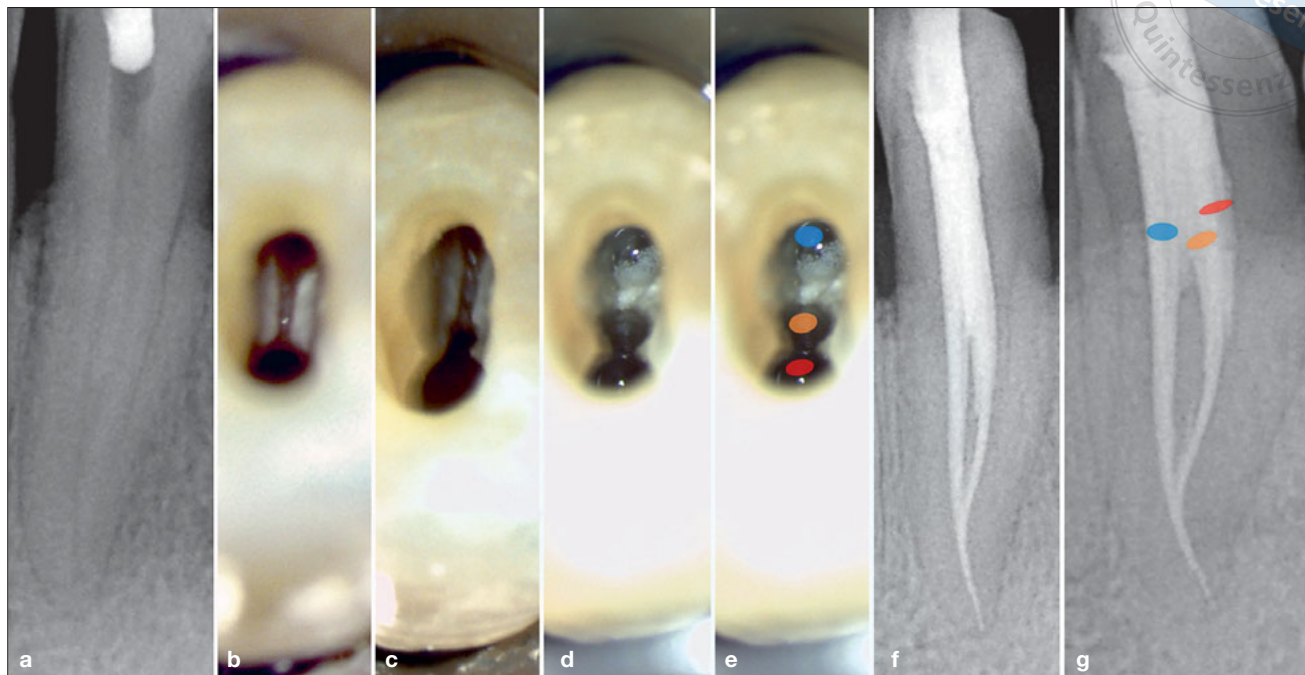


Fig 3 (a) Preoperative radiograph showing an unusual root canal configuration. (b) Perioperative photograph of the pulp chamber showing two canal orifices: buccal and lingual. (c) Perioperative photograph of the pulp chamber showing the presence of a third canal: the middle canal. (d) Perioperative photograph of the pulp chamber after root canal shaping. (e) The red, orange and blue ovals highlight the buccal, middle and lingual canal, respectively. (f) Postoperative orthoradial radiograph. (g) Postoperative angulated radiograph highlighting the unusual anatomy of this single-rooted mandibular canine (1-3-1).

Case 3

A 61-year-old Caucasian male was referred to the Clinic of Endodontics, Dental School, University of Strasbourg for treatment of tooth 33. His medical history was unremarkable. The preoperative radiograph revealed the presence of a complex endodontic anatomy (Fig 3a).

The endodontic treatment was performed in a single session. Using an operating microscope, the lingual and buccal root canal orifices were found with Start-X 1. With help of an endodontic probe and Start-X 3, a third canal orifice and a middle canal were located (Fig 3b to e). The canals were treated with the same technique as in Case 1, with the steps being performed in the following order: initial mechanical preflaring, apical scouting, glide path and shaping using PTX1 until WL, PTX2 2.5-mm short of the WL and a PF 25/04 to the WL.

More precisely, after 2 mm, the buccal canal and the middle canal merged in one principal buccal canal. This latter merged, in turn, with a lingual canal 2 mm from the apex. In order to avoid an apical zip and hazardous stress for the endodontic instruments (particularly dangerous at the level of the second canal curvature), we decided to shape the lingual canal until the WL and then the buccal canal until the merged point. The

cleaning and filling steps were managed in the same way as for Case 1. The final radiographs showed three well-obtreated canals of this single-rooted mandibular canine (Fig 3f and g).

Discussion

A clinician's knowledge of the endodontic anatomy with its frequent variations and complexities is essential for a successful endodontic treatment.

Mandibular canines are usually considered to be single-rooted teeth with a single root canal. However, two canals and, more rarely, two roots may also occur. According to data from *ex vivo* studies, in 24% of cases mandibular canines may have two canals and one root and in 5% of cases they may have two canals and two roots^{1,12-14}. To prevent any missed anatomy in a mandibular canine (which, as mentioned previously, is actually considered to be a single-rooted tooth), a minimum of two preoperative radiographs should be taken systematically because a periapical radiograph is only a two-dimensional image and can be limited in assessing the number of canals¹⁰. The clinician should not underestimate the importance of radiographs because the rigorous analysis provided by orthoradial and angu-

lated radiographs could offer an important first warning of an unusual anatomy. Mandibular canines with two roots are not difficult to identify, but it is more difficult to recognise two canals in a single-rooted canine^{10,15}. In order to obtain a preoperative 3D view of the pulp canal system, the location of the CEJ is determined before starting the access opening procedure. This is done using a periodontal probe. Moreover, in the intraoperative phase, the systematic use of a surgical microscope, coupled with the use of endodontic ultrasonic tips, allows for the facilitation and standardisation of the access cavity preparation and the location of the canals. Consequently, the use of cone beam computed tomography (CBCT) both for the initial treatment of a mandibular canine and in part for a retreatment is not justified. In our opinion, the use of CBCT is justified in the intraoperative phase only in the case of retreatment when the clinician has tried in vain by any other means to locate a calcified missed canal in order to avoid a possible perforation.

Conclusions

The failure to find an entire canal system may negatively influence the outcome of an endodontic treatment. To prevent missing any canals, clinicians should have a thorough knowledge of the anatomic variants of the canal system of every single tooth. When planning the endodontic treatment in its entirety, the preoperative radiographs and pre-access analysis are of major importance, including the location of the CEJ. Furthermore, systematic use should be made of a surgical microscope to meticulously inspect the chamber floor, and endodontic ultrasonic tips are required to ensure a correct pulp chamber access. All these are essential factors to ensure a positive outcome of an endodontic therapy.

Acknowledgements

The authors thank Mrs Valentina MACALUSO for her help with this work.

Conflicts of interest

The authors reported no conflicts of interest related to this study.

Author contribution

Dr Davide MANCINO designed the study and prepared the manuscript; Dr Najj KHAROUF revised and analysed the manuscript.

(Received May 16, 2018; accepted Sep 20, 2018)

References

1. Pécora JD, Sousa Neto MD, Saquy PC. Internal anatomy, direction and number of roots and size of human mandibular canines. *Braz Dent J* 1993;4:53–57.
2. D'Arcangelo C, Varvara G, De Fazio P. Root canal treatment in mandibular canines with two roots: a report of two cases. *Int Endod J* 2001;34:331–334.
3. Versiani MA, Pécora JD, Sousa-Neto MD. The anatomy of two-rooted mandibular canines determined using micro-computed tomography. *Int Endod J* 2011;44:682–687.
4. Victorino FR, Bernardes RA, Baldi JV, et al. Bilateral mandibular canines with two roots and two separate canals: case report. *Braz Dent J* 2009;20:84–86.
5. Sert S, Bayirli GS. Evaluation of the root canal configurations of the mandibular and maxillary permanent teeth by gender in the Turkish population. *J Endod* 2004;30:391–398.
6. Hess W. Anatomy of the root canals of the teeth of the permanent dentition. New York: William Wood and Co., 1925.
7. Vertucci FJ. Root canal anatomy of the human permanent teeth. *Oral Surg Oral Med Oral Pathol* 1984;58:589–599.
8. Bakianian Vaziri P, Kasraee S, Abdolsamadi HR, et al. Root Canal Configuration of One-rooted Mandibular Canine in an Iranian Population: An In Vitro Study. *J Dent Res Dent Clin Dent Prospects* 2008;2:28–32.
9. Calışkan MK, Pehlivan Y, Sepetçioğlu F, Türkün M, Tuncer SS. Root canal morphology of human permanent teeth in a Turkish population. *J Endod* 1995;21:200–204.
10. Cantatore G, Berutti E, Castellucci A. Missed anatomy: frequency and clinical impact. *Endod Topics* 2009;15:3–31.
11. Krasner P, Rankow HJ. Anatomy of the pulp-chamber floor. *J Endod* 2004;30:5–16.
12. Vertucci FJ. Root canal morphology and its relationship to endodontic procedures. *Endodontic Topics* 2005;10:3–29.
13. Pineda F, Kuttler Y. Mesiodistal and buccolingual roentgenographic investigation of 7,275 root canals. *Oral Surg Oral Med Oral Pathol* 1972;33:101–110.
14. Sharma R, Pécora JD, Lumley PJ, Walmsley AD. The external and internal anatomy of human mandibular canine teeth with two roots. *Endod Dent Traumatol* 1998;14:88–92.
15. Green D. Double canal in single roots. *Oral Surg Oral Med Oral Pathol* 1973;35:689–696.