

**Editorial****Natural History of a Surgical Technique:  
20 Years of Envelope Coronally Advanced Flap**

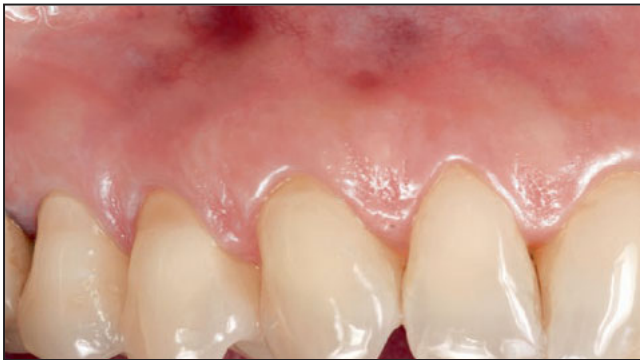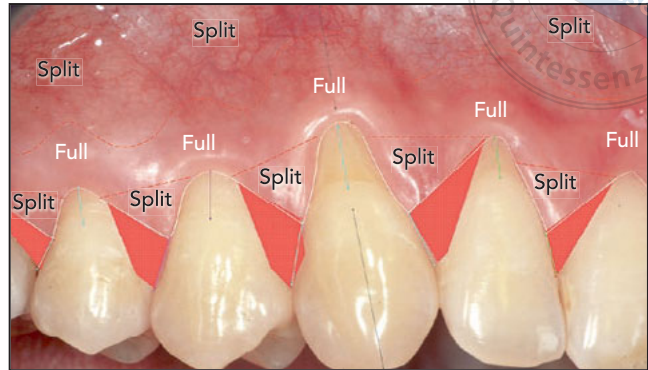
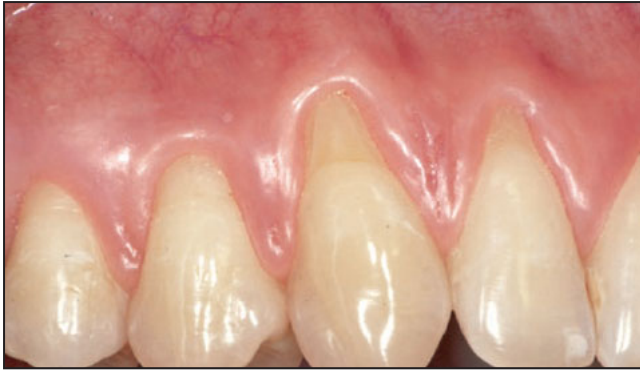Brilliant ideas inspire the creation of scientific evidence. In our field, an idea is a clinical/surgical intuition that comes from the experience of one or more professionals. At first, this idea should be published and diffused as a pilot study, proof of principle, or case series, and subsequently, it must be scientifically validated through randomized controlled studies. This is exactly what happened to the envelope coronally advanced flap (CAF) technique (Fig 1). First described by Zucchelli and De Sanctis in 2000 in a case series,<sup>1</sup> it has been tested in more than 100 studies and cited in 403 papers to date, proving its efficacy and repeatability. But what makes this transition from an innovative idea to a gold-standard procedure possible? Why are there so many surgical procedures that last only a few years, the so-called “meteors,” while others become scientific milestones? This mainly depends on the biologic principles upon which the technique is based.

The envelope CAF technique was constructed to focus on achieving the best possible blood supply as well as the highest wound stability, both key elements in wound healing. The envelope CAF design consists of a number of oblique submarginal incisions in the papillae area. The peculiar displace-

ment of the papilla tips was born to overcome an issue observed with previous techniques, in which the surgical papillae would cover the enamel instead of the interproximal vascular beds at the end of the surgery. The absence of vertical releasing incisions improves the tropism of the entire flap, avoiding damage to the lateral distribution of the vascular supply while eliminating the risk of scar formation. The concept of flap-thickness modulation, the split-full-split idea, was introduced to exploit the different characteristics of each thickness<sup>2</sup> anastomosis with the deepithelialized anatomical papillae. The full-thickness elevation of the mid-portion maintains the entire soft tissue thickness as well as the highly vascularized periosteum in the flap area, which will be positioned above the avascular exposed root surface. And finally, the minimal, deep, split-thickness incision in an apical direction detaches the alveolar mucosa from the periosteum, and the superficial incision removes muscle insertions from the inner aspect of the alveolar mucosa; both are crucial steps to eliminate flap tension and obtain coronal displacement. Passivity of the flap is an issue of paramount importance, as using pulling and compressive sutures to overcome residual flap tension may damage the vascular supply by re-

ducing vessel patency and impairing neovascularization. The absence of flap tension also contributes to its stability in the desired final position and reduces the risk of early flap shrinkage.<sup>3</sup> Flap closure is accomplished with a limited number of sling sutures, only one for each papilla, providing a tight buccal adaptation of the flap above the convexity of the crowns without the risk of blood seeping from the gingival margin, thus improving clot stability.

The solid biologic background behind every single step of the technique explains why there has been no need to make substantial changes over the years. Increased awareness of the necessity<sup>4</sup> to aid flap stability by the site-specific addition of connective tissue graft has been the main innovation in the last years.<sup>5</sup> Obviously, surgical instruments and suture materials have become more refined and magnification systems have improved; this has allowed the technique to become ever more precise. However, the legacy of the envelope CAF is its evolution from being a treatment for gingival recession to becoming a treatment philosophy. Coronal advancement is an ascertained concept to counteract the flap's tendency to shrink during the early phases of wound healing. Thus, the envelope CAF concept is now applied in



**Fig 1** The 20-year follow-up of the clinical case originally published. Note the stability of the soft tissue coverage and the increase in keratinized tissue height. Some noncarious cervical lesions occurred. (Images reprinted with permission from: Zucchelli G, De Sanctis M. Treatment of multiple recession-type defects in patients with esthetic demands. *J Periodontol* 2000;71:1506–1514.)

a variety of surgical procedures that require flap elevation, such as: with periodontal reconstructive surgery to obtain an esthetic improvement along with periodontal regeneration; simultaneously with implant placement to improve soft tissue appearance; and for soft tissue augmentation in edentulous sites.

Behind every scientific milestone, there is always a brilliant idea with strong biologic support. It is proven over time by the scientific community and encloses a “vision” that allows widespread application of the technique in different fields.

*Martina Stefanini, DDS, PhD  
Bologna, Italy*

*Sofia Aroca, MDS, DDS, PhD  
Paris, France*

*Myron Nevins, DDS  
Boston, Massachusetts, USA*

## References

1. Zucchelli G, De Sanctis M. Treatment of multiple recession-type defects in patients with esthetic demands. *J Periodontol* 2000;71:1506–1514.
2. Clementini M, Discepoli N, Danesi C, de Sanctis M. Biologically guided flap stability: The role of flap thickness including periosteum retention on the performance of the coronally advanced flap—A double-blind randomized clinical trial. *J Clin Periodontol* 2018;45:1238–1246.
3. Cortellini P, Pini Prato G. Coronally advanced flap and combination therapy for root coverage. Clinical strategies based on scientific evidence and clinical experience. *Periodontol* 2000 2012;59:158–184.
4. Zucchelli G, De Sanctis M. Long-term outcome following treatment of multiple Miller Class I and II recession defects in esthetic areas of the mouth. *J Periodontol* 2005;76:2286–2292.
5. Stefanini M, Zucchelli G, Marzadori M, de Sanctis M. Coronally advanced flap with site-specific application of connective tissue graft for the treatment of multiple adjacent gingival recessions: A 3-year follow-up case series. *Int J Periodontics Restorative Dent* 2018;38:25–33.