

## Indication of self-drilling screws in craniomaxillofacial surgery

**Language:** English

**Authors:** Ralf Schön, Nils-Claudius Gellrich, Ralf Gutwald, Alexander Schramm, Rainer Schmelzeisen  
University Hospital Freiburg, Dept. Oral & Maxillofacial Surgery, Germany (Director: Prof. Dr. Dr. R. Schmelzeisen)

**Date/Event/Venue:**

19.05.99-22.05.99

4<sup>th</sup> European Skull Base Society Congress and 3<sup>rd</sup> Kongreß der Dt. Gesell. f. Schädelbasischir.  
Nürnberg, Germany

### Introduction

With the development of osteosyntheses systems, different types of plates and screws have been designed which have tended to become smaller and easier to handle. The AO / ASIF 1.5 and 2.0 self-drilling screw (Synthes) with thread-forming properties is similar in design to a simple wood screw (Fig.1, 2)

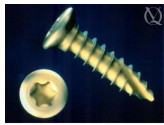

Fig. 1: Conically shaped self-drilling screw with flute design at the tip for the transportation of bone debris.



Fig. 2: Screw head - star drive- results in exact central position and high retention between screw and the selfholding screw driver.

### Objective

We evaluated different indications in the craniomaxillofacial area for the clinical use of this new type of screw. The indications varied from osteosyntheses after frontal orbital advancement with and without fixation of distraction devices, fractures of the midface and naso-orbito-ethmoidal complex. In addition we used the self-drilling screws for the fixation of the canthal ligament and bone grafts in reconstructive procedures as well as for the fixation of distraction devices and miniplate osteosynthesis in the mandible (Fig. 3-7).

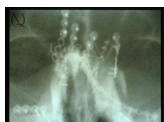


Fig. 3: Secondary orbital reconstruction. Self-drilling screws for miniplate osteosynthesis at the nasoethomoidal complex and for the fixation of medial canthal ligament.

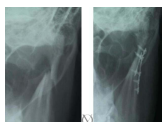


Fig. 4 a, b: Osteosynthesis of subcondylar fracture. X-rays preoperative and 6 months after surgery.

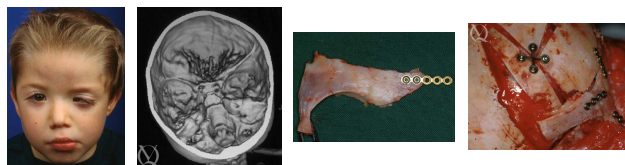


Fig.5 a-d: Surgical correction of a plagiocephaly deformity. Preoperative and intraoperative view after surgical correction and internal fixation using self-drilling screws.

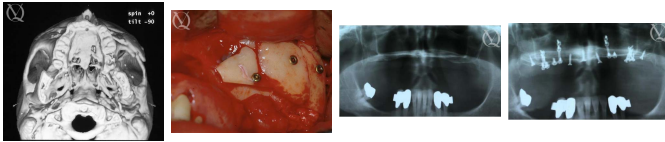


Fig. 6a,b: Fixation of calvarian split onlay bone grafts using self-drilling screws. Preoperative CT scan and intraoperative view.

Fig.7 a, b: Fixation of iliac crest bone graft for maxillary augmentation. Pre- and postoperative X-ray.

## Material and Methods

The handling and fixation properties of the self-drilling screw were judged upon ease of insertion and retention. Torque measurements and regional differences such as bone thickness and quality were evaluated.

## Results

Clinical experience with 334 screws in 28 patients after craniomaxillofacial procedures showed good results. Ease of insertion without previous drilling and less use of instruments reduced the operating time. Insertion torque was increased compared to self-tapping screws. In dense cortical bone of 3-4 mm in thickness the insertion torque was high. Screw fractures occurred, when the screws were inserted forcefully in the periorbital area and in the lower aspect of the mandible. Torque measurements 6 months after insertion of the screws at the time of screw removal demonstrated good anchorage of the self-drilling screws similar to the self-tapping screws at same location (Tab.1). Miniplate osteosynthesis and the fixation of cortical and cortico-cancellous bone grafts using self-drilling screws proved to be reliable (Fig. 3-5).

<b>Frontal</b>	<b>0.10 Nm</b>
<b>Periorbital</b>	<b>0.12 Nm</b>
<b>Paranasal/Zygoma</b>	<b>0.07 Nm</b>
<b>Maxillary Sinus</b>	<b>0.04 Nm</b>
<b>Mandible</b>	<b>0.12 Nm</b>

Tab.1 Removal Torque: Torque measurements at the time of plate removal of 89 screws demonstrated similar results compared to 2.0 self-tapping screws at same location (Lit.2).

## Discussion and Conclusions

Our results in the craniomaxillofacial region are comparable to in-vitro studies and histomorphological evaluation of the same type of screw in cancellous and cortical bone of 1 mm and 3 mm in thickness (1).

These studies showed increasing insertion torque measurements and pull-out strength of self-drilling screws in bone 3 mm of thickness. A potential destructive effect due to radial compression of the surrounding bone was reported for the thread-forming screws (2).

In contrast to these findings good anchorage of the self-drilling screws at the time of screw removal demonstrated a reliable osteosyntheses in our clinical study with torque measurements comparable to those of self-tapping screws (3).

To evaluate the effect of radial compression at the bone-screw interface on bone healing an animal study is presently in progress. Although in dense cortical bone of 3-4 mm in thickness the use of self-drilling screws may be limited, in our opinion the excellent clinical results in the craniofacial region and the less time consuming insertion of self-drilling screws compared to conventional screws will result in a broad acceptance within craniomaxillofacial surgery.

## Bibliography

1. Löhner J, Gellrich N-C, Wahl D, Büscher P, Pfluger D, Rahn BA: In-Vitro evaluation of self-drilling M-F screws an histomorphological and functional investigation. AO Cranio-Maxillofacial Course 1998, Davos, Switzerland
2. Kuhn A, McTiff T, Cordey J, Baumgart FW, Rahn BA: Bone deformation by thread-cutting and thread-forming cortex screws. Injury 1995, Vol. 26, Suppl. 1, 12-20.
3. Wächter R, Gutwald R, Seper L, Schilli W: Festigkeit der Verankerung unterschiedlich dimensionierter Osteosyntheseschrauben - klinische Drehmomentmessungen. 34. Jahrestagung der Deutschen Gesellschaft für Plastische und Wiederherstellungschirurgie, Kongreßband 1997, Hrsg. Rudolph H, Einhorn-Press.

*This Poster was submitted on 17.05.00 by Dr. Dr. Ralf Schön.*

## Correspondence address:

*Dr. Dr. Ralf Schön*  
 Klinik und Poliklinik für MKG-Chirurgie  
 Univ.-Klinik Freiburg  
 Hugstetter Str. 55  
 D - 79106 Freiburg



INDICATION OF SELF-DRILLING SCREWS IN CRANIOMAXILLOFACIAL SURGERY



R. Schön, N.-C. Gellrich, R. Gutwald, A. Schramm, R. Schmelzeisen

**Introduction:**

With the development of osteosynthesis systems, different types of plates and screws have been designed which have tended to become smaller and easier to handle. The AO / ASIF 1.5 and 2.0 self-drilling screw (Synthes®) with thread-forming properties is similar in design to a simple wood screw (Fig.1, 2) We evaluated different indications in the craniomaxillofacial area for the clinical use of this new type of screw. The indications varied from osteosyntheses after frontal orbital advancement with and without fixation of distraction devices, fractures of the midface and naso-orbito-ethmoidal complex. In addition we used the self-drilling screws for the fixation of the cantal ligament and bone grafts in reconstructive procedures as well as for the fixation of distraction devices and miniplate osteosynthesis in the mandible (Fig. 3-7). The handling and fixation properties of the self-drilling screw were judged upon ease of insertion and retention. Torque measurements and regional differences such as bone thickness and quality were evaluated.




Fig. 1: Conically shaped self-drilling screw with fine threads at the tip for the transportation of bone debris.



Fig. 2: Screw head - star drive: results in exact central position and high retention between screw and the selfdrilling screw driver.




Fig. 3: Secondary orbital reconstruction: Self-drilling screws for miniplate osteosynthesis at the nasoorbitomaxillary complex and for the fixation of medial canthal ligament.

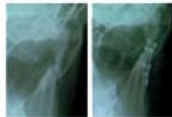


Fig. 4 a, b: Osteosynthesis of subcondylar fracture: X-rays preoperative and 6 months after surgery.

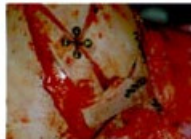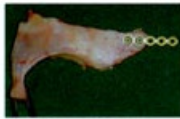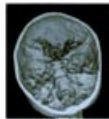


Fig. 5 a-d: Surgical correction of a plagiocephaly deformity: Preoperative and intraoperative view after surgical correction and internal fixation using self-drilling screws.

**Results:**

Clinical experience with 334 screws in 28 patients after craniomaxillofacial procedures showed good results. Ease of insertion without previous drilling and less use of instruments reduced the operating time. Insertion torque was increased compared to self-tapping screws. In dense cortical bone of 3-4 mm in thickness the insertion torque was high. Screw fractures occurred, when the screws were inserted forcefully in the periorbital area and in the lower aspect of the mandible.

Torque measurements 6 months after insertion of the screws at the time of screw removal demonstrated good anchorage of the self-drilling screws similar to the self-tapping screws at same location (Tab.1). Miniplate osteosynthesis and the fixation of cortical and cortico-cancellous bone grafts using self-drilling screws proved to be reliable (Fig. 3-5).

Frontal	0.10 Nm
Periorbital	0.12 Nm
Paranasal/Zygoma	0.07 Nm
Maxillary Sinus	0.04 Nm
Mandible	0.12 Nm

Tab. 1 Removal Torque: Torque measurements at the time of plate removal of 80 screws demonstrated similar results compared to 2-4 self-tapping screws at same location (2,3,22).

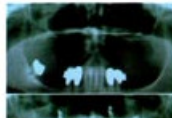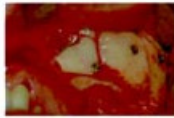
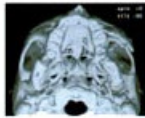


Fig. 6 a, b (left): Fixation of calvarium split only bone grafts using self-drilling screws. Preoperative CT scan and intraoperative view.

Fig. 6 a, b (right): Fixation of iliac crest bone graft for maxillary augmentation. Pre- and postoperative X-ray.

**Discussion:**

Our results in the craniomaxillofacial region are comparable to in-vitro studies and histomorphological evaluation of the same type of screw in cancellous and cortical bone of 1 mm and 3 mm in thickness (1). These studies showed increasing insertion torque measurements and pull-out strength of self-drilling screws in bone 3 mm of thickness. A potential destructive effect due to radial compression of the surrounding bone was reported for the thread-forming screws (2). In contrast to these findings good anchorage of the self-drilling screws at the time of screw removal demonstrated a reliable osteosyntheses in our clinical study with torque measurements comparable to those of self-tapping screws (3). To evaluate the effect of radial compression at the bone-screw interface on bone healing an animal study is presently in progress. Although in dense cortical bone of 3-4 mm in thickness the use of self-drilling screws may be limited, in our opinion the excellent clinical results in the craniofacial region and the less time consuming insertion of self-drilling screws compared to conventional screws will result in a broad acceptance within craniomaxillofacial surgery.

1. Lohr J, Gellrich N-C, Wolf D, Fischer P, Pfluger D, Rahn BA. In-Vitro evaluation of self-drilling M.F. screws an histomorphological and functional investigation. AO Cranio-Maxillofacial Course 1998, Davos, Switzerland.  
 2. Rubin A, Schöffl T, Gordan J, Baumgartner TW, Rubin BA. Bone deformation by thread-forming and thread-forming screws. Injury 1995; Vol. 26, Suppl. 1, S2-20.  
 3. Wächter R, Gutwald R, Sepp L, Schön W. Prägnanz der Verwendung unterschiedlich dimensionierter Osteosyntheseschrauben. 34. Jahrestagung der Deutschen Gesellschaft für Plastische und Wiederherstellungschirurgie, Langgolfstrand 1997, Herg, Bad Nauheim, Hessen-Pfalz.