

Comparative Evaluation of Bone Regeneration Following Surgical Closure of Oro-Antral Perforation With and Without Bone Augmentation Using Cone Beam Computed Tomography - CBCT. Case Report.



6th International CAMLOG Congress, Krakow, Poland, June 9-11, 2016

Poster language: english

Paweł Nieckula, DDS, Piotr Wychowański, MD, DDS, PhD, Bartłomiej Iwańczyk, DDS, Prof. Andrzej Wojtowitz, DDS, PhD

Medical University of Warsaw, Department of Oral Surgery, Nowogrodzka Street 59, 02-006 Warsaw, Poland

Phone number: +48 225021242, E-mail: pawel.nieckula@wum.edu.pl

Key words: oro-antral perforation, oro-antral communication, bone regeneration, buccal flap technique, internal sinus lift, dental implants

Abstract:

Background and aim: The most common etiology of creating the communication between maxillary sinus and oral cavity is upper premolars or molars extraction. The aim of this study was to assess the efficacy of the surgical treatment using bone augmentation of the oro-antral perforation (OAP) following maxillary posterior teeth extraction.

Methods and materials: The study was performed in 1 patient at age 28. The OAP was diagnosed after 16 and 26 tooth extraction. First OAP was sutured closed by buccal flap method, the second one was augmented and sutured closed by the same method. The measure of postoperative defect and bone regeneration progress were conducted basing on CBCT.

Results: Bone thickness after 6 months was 1 mm where 16 tooth was extracted and 11,72 mm on the side, where 26 tooth was extracted.

Conclusions: The buccal flap method does not ensure bone regeneration after OAP. The thickness of the regenerated bone after augmentation was satisfactory for implantology treatment.

Introduction:

The most common etiology of creating the communication between maxillary sinus and oral cavity is upper premolars or molars extraction. Nowadays most patients expect reconstruction of missing tooth using dental implants. A main factor for successful implant therapy is the presence of an adequate quantity and quality of bone. Therefore the crucial factor to assess treatment success after oro-antral perforation (OAP) closure should be the volume of regenerated bone in maxillary alveolar process. The aim of this study was to assess the efficacy of the surgical treatment using bone augmentation of the OAP following maxillary posterior teeth extraction.

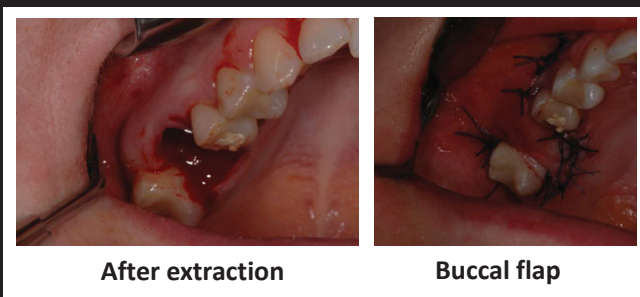
Objectives:

The aim of this study was to assess the efficacy of the surgical treatment using bone augmentation of the OAP following maxillary posterior teeth extraction.

Material and methods:

The study was performed in 1 patient, woman who was in good health, at age 28. As the OAP was diagnosed after 16 tooth extraction, it was sutured closed by buccal flap method. Three months later 26 tooth was extracted and the OAP was also diagnosed. It was augmented using ksenograft material (Geistlich Bio – Oss), collagen membrane (Geistlich Bio – Gide) and sutured closed by the same method. The measure of postoperative defect and bone regeneration progress were conducted basing on CBCT (Kodak 9000 Extra Oral Imaging System, Kodak Dental Imaging Software 6.12.9.0) performed 3 days and 6 months after every surgery.

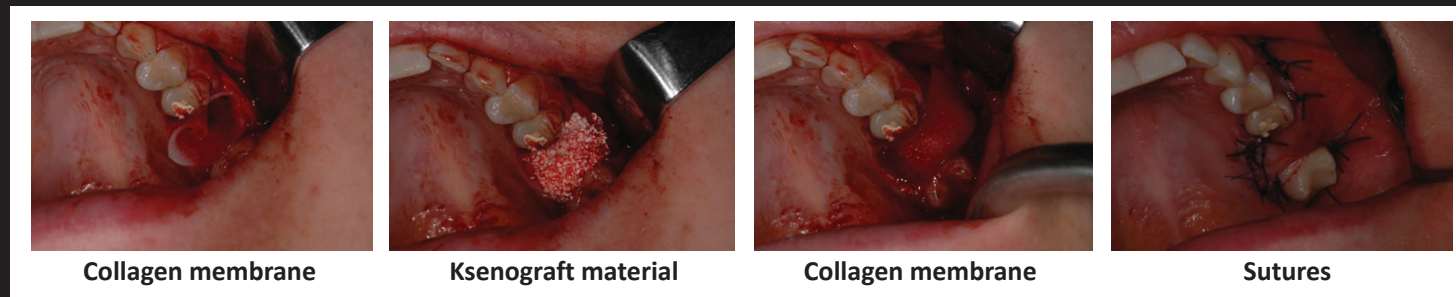
1. Surgical closure of oro-antral perforation without bone augmentation



After extraction

Buccal flap

2. Surgical closure of oro-antral perforation with bone augmentation



Collagen membrane

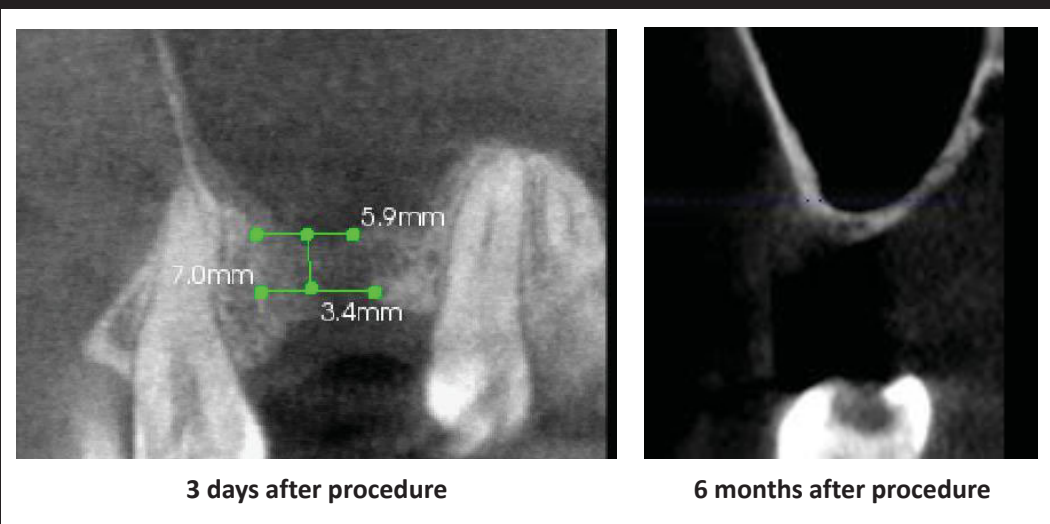
Ksenograft material

Collagen membrane

Sutures

Results:

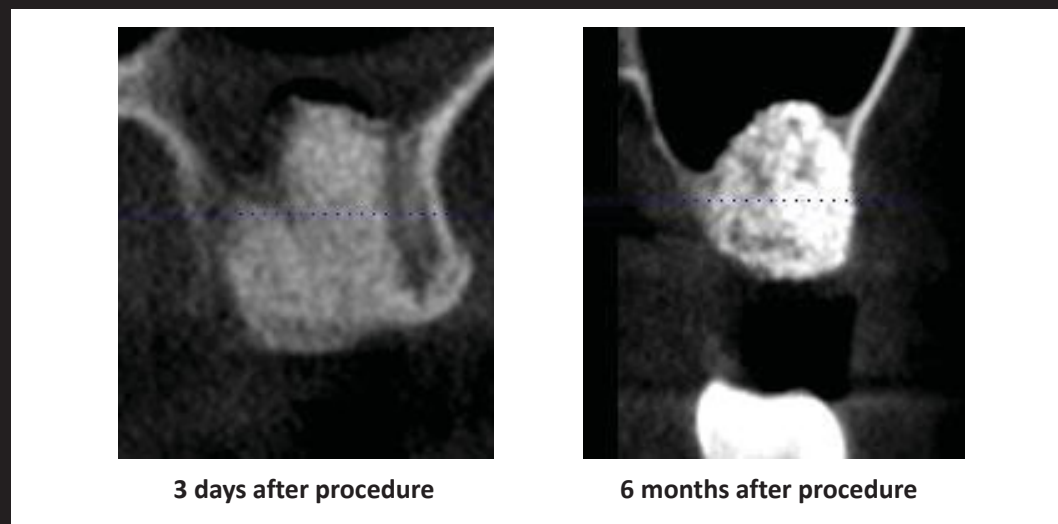
1. Surgical closure of oro-antral perforation without bone augmentation



3 days after procedure

6 months after procedure

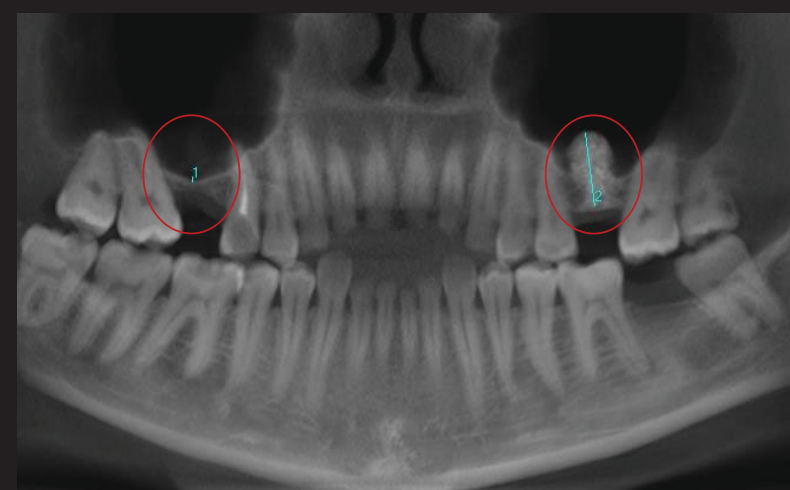
2. Surgical closure of oro-antral perforation with bone augmentation



3 days after procedure

6 months after procedure

Patient had a successful OAP closure and no sinusitis in both sides. Bone thickness after 6 months was 1 mm (1) where 16 tooth was extracted and the bone was not augmented and 11,72 mm (2) on the side, where 26 tooth was extracted and the bone was augmented.



Conclusions:

The buccal flap method does not ensure bone regeneration after OAP, but it is effective for closure. The thickness of the regenerated bone after augmentation was satisfactory for implantology treatment. It shortened the implantology treatment and allowed to avoid external sinus lift procedure.