

Anatomy of the Maxillary Posterior Region with Implications for Implant Therapy

Peter Hunt, Silvy Bergler and Laura Ceccacci
Philadelphia, Pa. USA

Dr Peter Hunt : peter.hunt@DrPeterHunt.com

Introduction

Immediate implant therapy is increasingly common in most parts of the mouth but seems to be quite rare in the molar region, particularly in the maxilla. With the advent of CBCT scans, it is possible to evaluate this region much more precisely and accurately than with previously existing two-dimensional technologies. We wanted to evaluate maxillary molar teeth that required replacement with implants. We wanted to understand why these regions shrink so dramatically when teeth are removed and we wanted to see if this shrinkage could be prevented by placing implants with simultaneous augmentation. We needed to assess the proximity of the sinus and to see if the implant procedure would require sinus augmentation as part of the therapy.

Materials and Methods

Over a period of two years, 53 consecutive patients with failing maxillary molars presented or were referred for implant replacement. This study reviews the CBCT data on each case to determine the thickness of bone present over the roots, the presence of inter-radicular furca bone, the height of bone in the region and the proximity of the sinus in the location where an implant would be placed.

Procedure Considerations

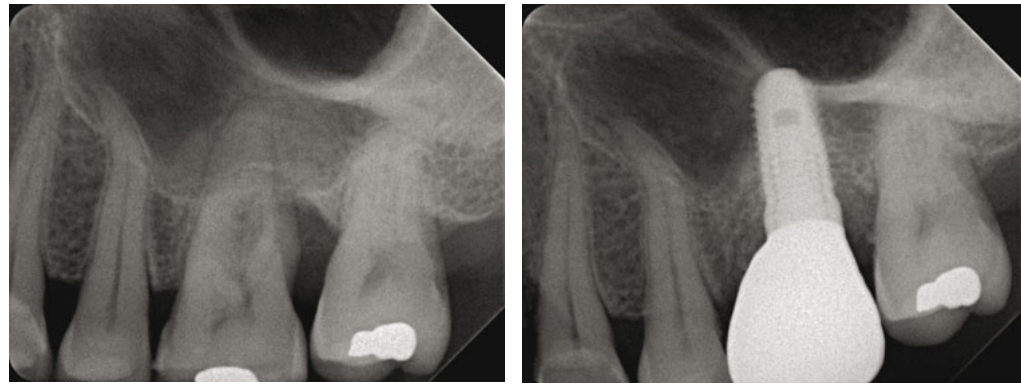
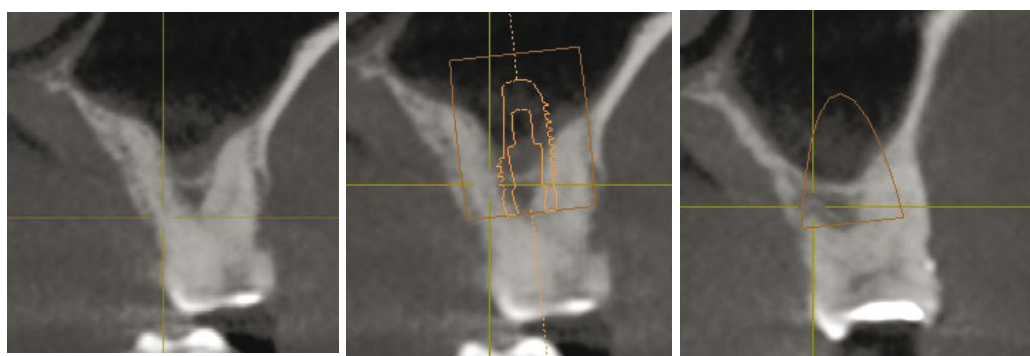
The roots of maxillary molars “flare out” much more than do the roots of mandibular molars so that securing an implant into a particular root socket is generally not indicated. Besides the labial or palatal thickness of bone is often surprisingly thin, so subject to resorption.

Accordingly, these teeth were all removed by first sectioning off the crown and then separating the individual roots. The roots can then be removed individually with less chance to damage the residual bone structure. The prime intention is to preserve the socket walls intact. In most situations, unless there is a socket wall deficiency, flaps were not raised.

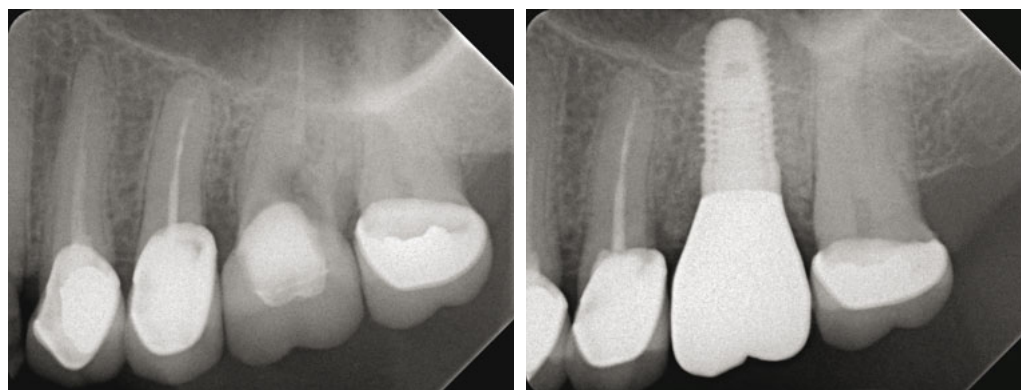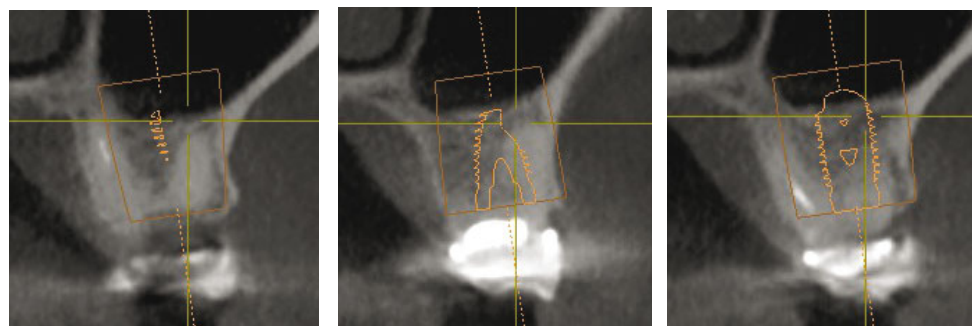
The regions available for Primary Stabilization of an implant are:

1. Within a root socket.
2. Apical to the socket.
3. Through an inter-radicular septum (furcal bone).
4. In the sinus floor, which requires an intentional sinus floor elevation.
5. Combinations of the above.

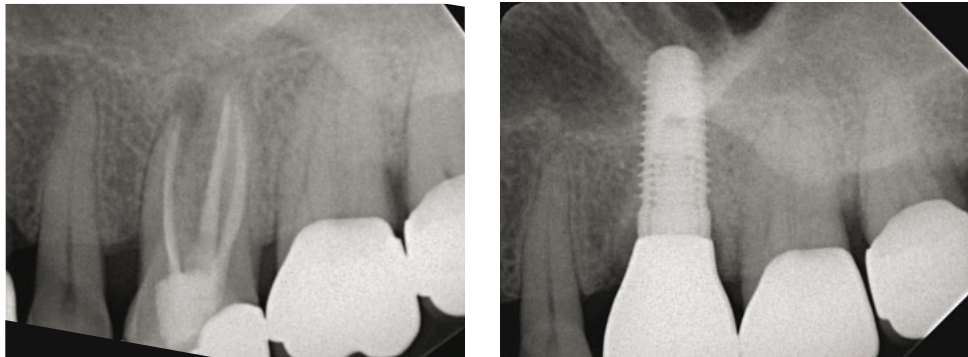
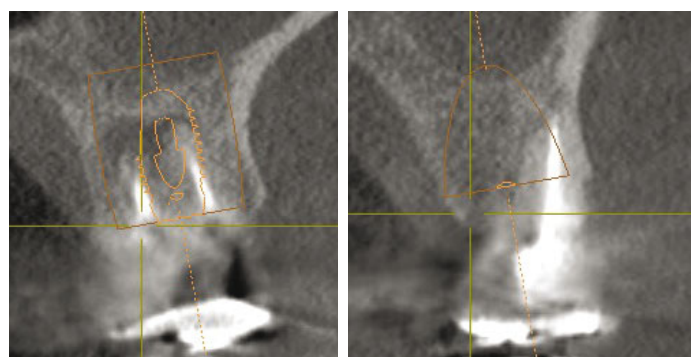
If implants are not able to be primarily stabilized then a **Socket Regeneration** procedure should be performed.



1. A “LOW Height” bone case needing tooth removal for management of a deep, distal furca involvement.



2. A “MEDIUM Height” bone case needing tooth removal for restorative reasons.



3. A “HIGH Height” bone case needing tooth removal for endodontic reasons.

Results

1. The labial and palatal roots of many maxillary molars are covered with a very thin layer of bone which explains why extensive ridge resorption is so common in the maxillary molar region when teeth are removed.
2. The bone layer is also often very thin on the inner surface of the labial and palatal roots, which means that there can be very little bone in the furcation region to house and provide support for an implant.
3. Bone Height in maxillary molars can be classified into three main categories
 - a. **High** : Trifurcation bone extending above the apices of the roots
 - b. **Medium** : Trifurcation bone extending up to the apices of the roots
 - c. **Low** : Trifurcation bone closely following the roots of the tooth
4. While the furca region may be adequate to stabilize an implant, a sinus elevation and augmentation may be needed to gain more implant support.
5. If there is apical infection in a tooth with closely set roots then apical bone alone may not be adequate to stabilize an implant.

Conclusions

Generally, the volume of bone supporting maxillary molars seems to be quite limited. Instead, often only a relatively thin layer of bone covers and supports the roots. In many teeth, this bone layer was partially deficient from fenestration, dehiscence, furcation involvement or apical endodontic lesions. The sinus floor often closely follows the contours of the roots. All these factors increase the potential for rapid ridge collapse when a tooth is removed.

Some bone needs to be available to stabilize an implant **primarily** within the residual bone. This is best in the central portion of the socket. The tri-furcation bone between the roots may be suitable. Alternatively it may be gained by intentional perforation through the sinus floor. This allows for additional implant length because of the sinus lift procedure which follows the perforation. **Secondary** implant stability comes from Socket Regeneration and/or a Sinus Lift.

When immediately replacing a maxillary molar, one needs to be prepared for a socket regeneration, an intentional perforation of the sinus floor and a sinus lift.