

Migration of a Dental Implant into the Maxillary Sinus: Case Report.



Rodrigues P*, Afonso C. **, Caetano A. **, Nathalal D. **, Silva V. **
* Implantology Consultation I.S.C.S.E.M.
** Volunteers Implantology consultation I.S.C.S.E.M.

Case Description

- 74-year old patient, male, caucasian patient was referred to the Implantology and Oral Rehabilitation Consult at I.S.C.S.E.M. university clinic due to loss of osseointegration and migration of a dental implant into the left maxillary sinus.
- Clinical History: controlled asthmatic treated with fluticasone propionate.
- Oral Clinical History: Carrier of a superior full-arch removable dental prosthesis and an inferior partial prosthesis for over 15 years. Previous attempt of oral rehabilitation with dental implants 12 months prior to the appointment at I.S.C.S.E.M. Complaints of bad breath and respiratory obstruction on the left side.
- An Ortopantomography was taken and a Computerized Tomography (CT) using Dentascan technique with 1mm cross-sectioning was prescribed.
- Diagnosis: 1) Bone loss on the dental implant placed in the #22 region. 2) Loss of osseointegration of the dental implant previously placed on the posterior side of the maxilla (left side) and its migration to the left maxillary sinus. 3) Oroantral fistula in the crestal region adjacent to the maxillary sinus, at the migrated implant site.
- For the surgical removal of the implant, an external sinus access was performed.
- A collagen membrane was used to close the access.
- The patient rejects a new attempt to restore the upper arch with the use of dental implants.

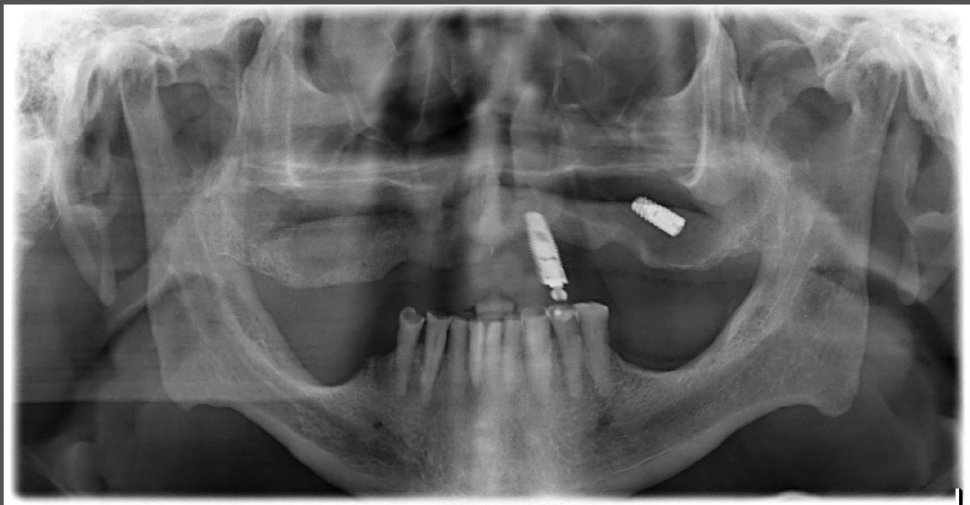

Image 1 - Initial Ortopantomography

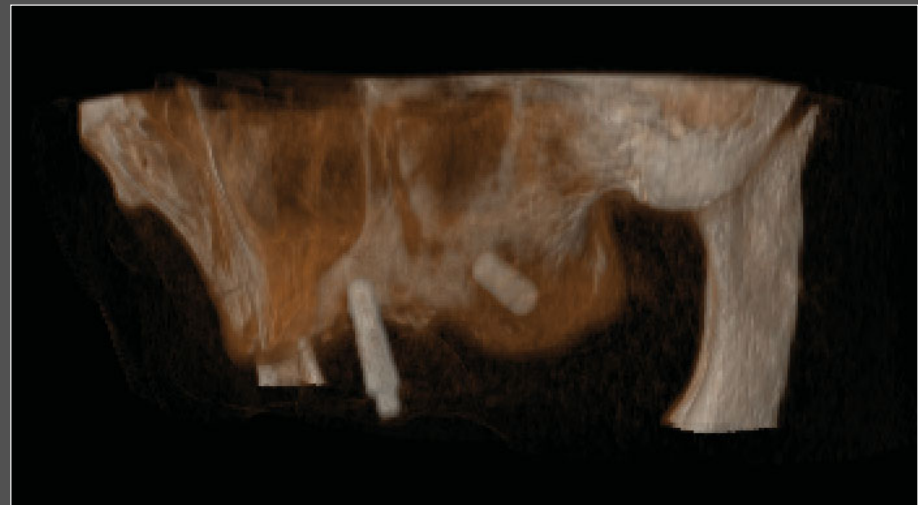


Image 2 - 3D Reconstruction of CT scan

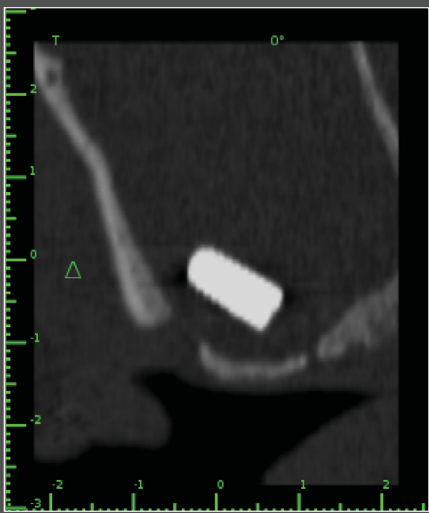

Image 3 - Oroantral Fistula

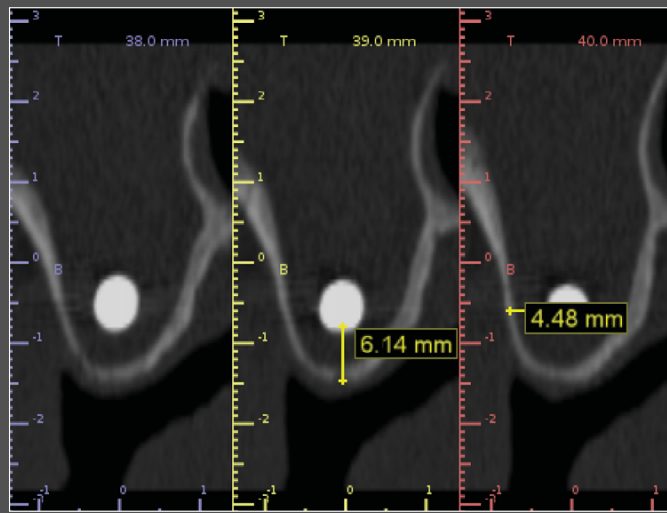


Image 4 - Location of the implant on the CT scan

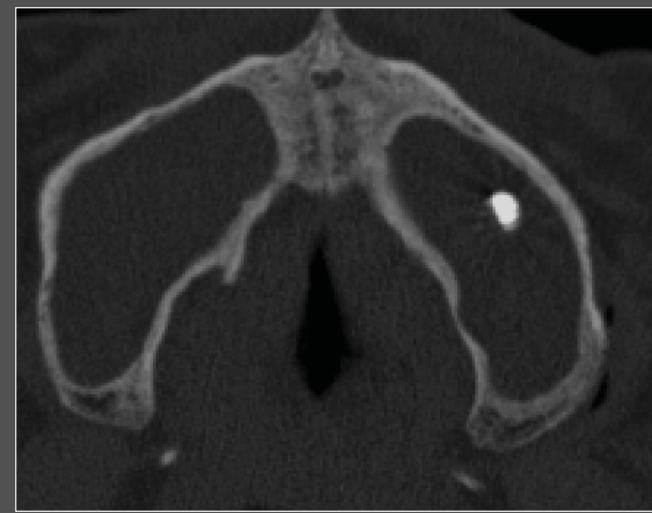

Image 5 - Location of the implant on the CT scan

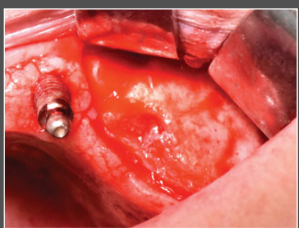


Image 6 - Flap elevation

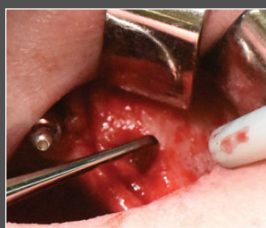


Image 7 - Oroantral Fistula

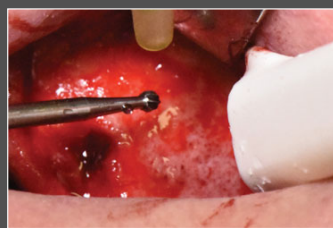


Image 8 - Osteotomy

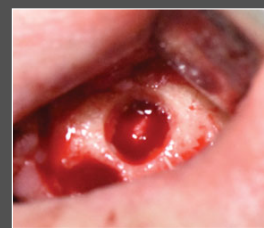

Image 9 - Sinus Window

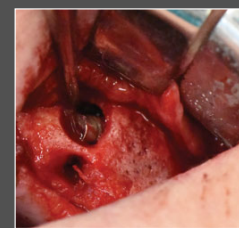


Image 10 - Removal

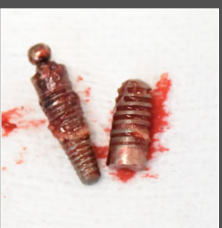


Image 11 - Implants Removed

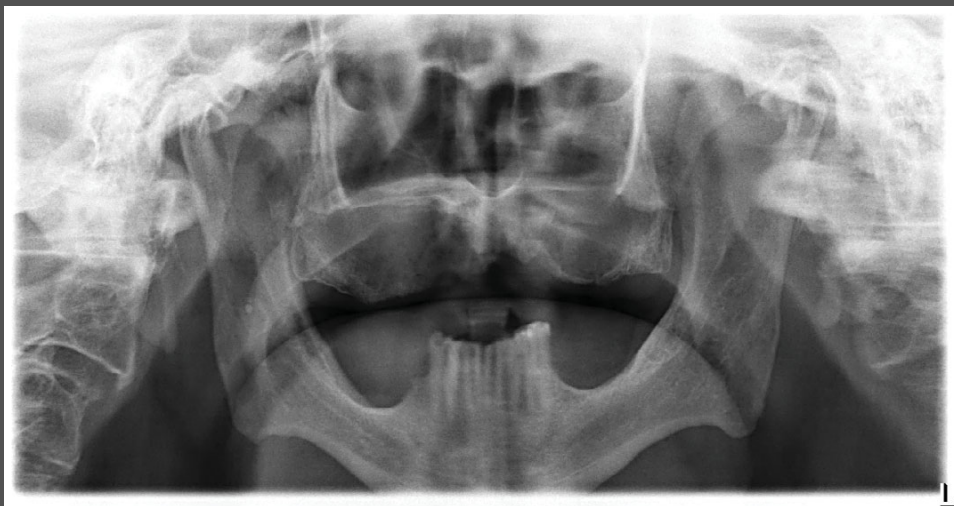


Image 12 - Final Ortopantomography

Discussion

The migration of dental fragments, endodontics material and dental implants into the maxillary sinus is documented (1). The poor density bone of the posterior maxilla may cause loss of osseointegration. Inadequate bone preparation, perforation of the sinus floor and/or Schneiderian membrane, as well as the lack of primary stability of dental implants placed in close range of the sinuses can be considered as possible causes of implant migration into the sinus cavities (2). The non removal of the migrated dental implants may cause its displacement into craniofacial structures, which can provoke further complications due to foreign body reactions, infections and tissue necrosis and collapse if sinus clearance (3, 4, 5).

Conclusion

The migration of dental implants to the maxillary sinus should be managed in cautious and immediate manner. The intra-oral approach (6) could remove the implants successfully resorting to buccal (7) or palatal (8) flaps, but it is not sufficient to treat the closed ostium and the sinus consequences. Therefore, a multidisciplinary approach is indicated (9).