

Baptista Pereira J.<sup>\*☀</sup>, Amorim T.<sup>†</sup> DDS, Melo T.<sup>☀</sup>, Laranjeira J.<sup>\*\*</sup> DDS, Fonseca L.<sup>\*\*</sup> TPD  
<sup>\*</sup> Author <sup>☀</sup> 5<sup>th</sup> year Dentistry Student at Instituto Superior de Ciências da Saúde - Egas Moniz  
<sup>†</sup> Instituto Superior de Ciências da Saúde - Egas Moniz <sup>\*\*</sup> Faculdade de Medicina Dentária Universidade de Lisboa

# REHABILITATION WITH FELDSPATHIC VENEERS AND JACKET

## IN AESTHETIC ZONE: CLINICAL CASE

**PRESENTATION:** Female patient, healthy, smoker, 44 years old, attended the clinic unhappy with the aesthetics of her smile due to the presence of extensive pigmented restorations and an old metal-ceramic crown. A diagnostic wax-up was made to plan and preview the final shape of the teeth. Tooth 22 presented periapical pathology, therefore endodontic treatment was executed. Composite restorations of teeth 11, 12 and 22 were replaced. It was also performed an external bleaching with carbamide peroxide at 10%. In tooth 22 was performed a gingivectomy to level the margin gums with tooth 12. Teeth 11, 12 and 22 were prepared for feldspathic veneers and tooth 21 for a feldspathic jacket. After the final impressions, the provisionals were made with a bis-acril resin. The veneers adhesion was accomplished through a resin cement, using a rubber dam isolation.

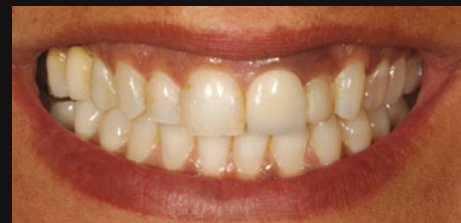
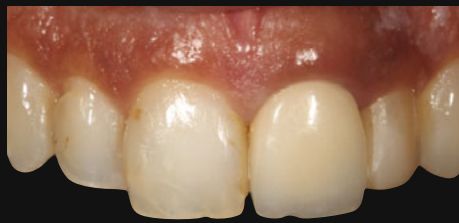
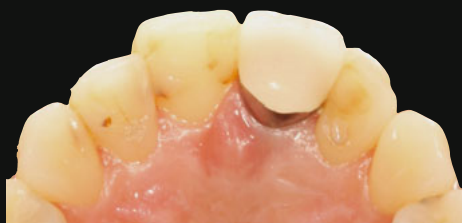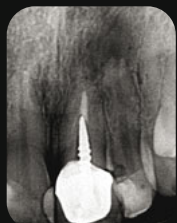Fig. 1 - Initial x-ray

Fig. 2 - Initial occlusal photography

Fig. 3 - Initial close-up

Fig. 4 - Initial smile photography

**DISCUSSION:** Ceramic veneers are indicated in the rehabilitation of the second sextant when it is aesthetically compromised. Through a minimally invasive preparation, veneers allow us to change the color and shape of the teeth. On tooth 21, in order to reach smile harmony, the metal-ceramic crown was replaced by a ceramic one. The pre-existing preparation was only rectified because there was no need for endodontic retreatment. Ceramic is a material with excellent optical properties, it has a similar appearance to the natural tooth. It also allows rehabilitation with a maximum preservation of dental structures, due to a high adhesive strength. In addition to these factors, ceramic ensures the longevity of the treatment, making it the ideal material for this rehabilitation.

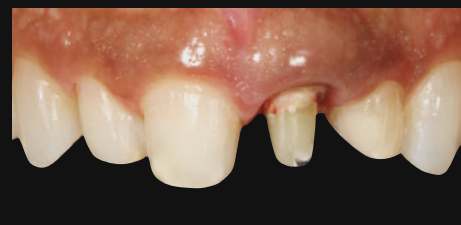
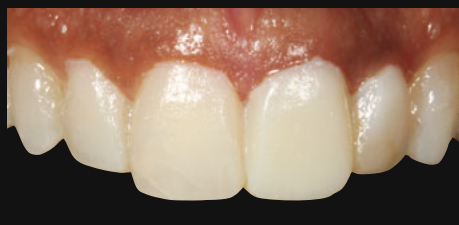
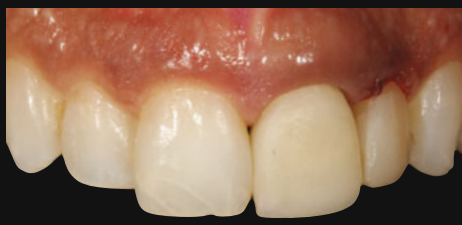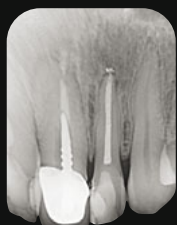Fig. 5 - X-ray after endodontic treatment

Fig. 6 - 21 provisional and 22 gingivectomy

Fig. 7 - Mock-up

Fig. 8 - Final preparation

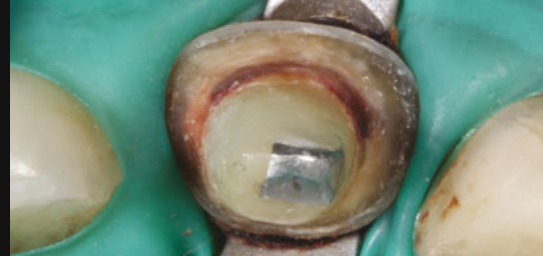
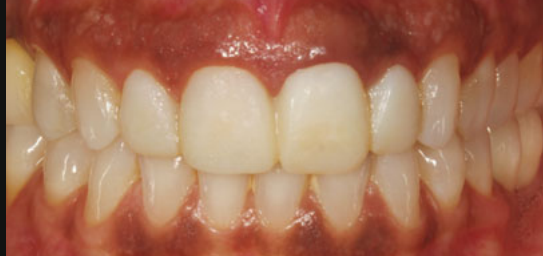
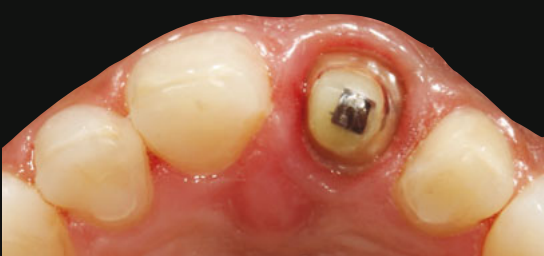Fig. 9 - Final preparation

Fig. 10 - Provisional veneers and crown

Fig. 11 - Rubber dam isolation

**CONCLUSION:** Oral rehabilitation using fixed adhesive prosthesis combined with all the advantages that ceramic provides us, proved to be the appropriate therapeutic option to meet the patient expectations.

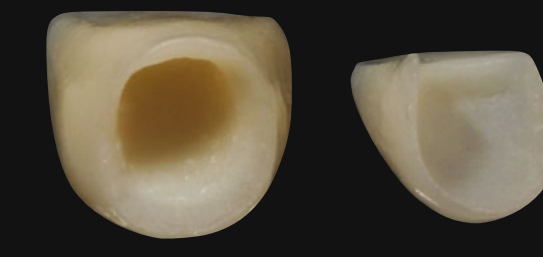
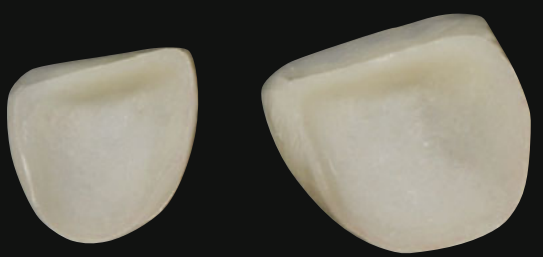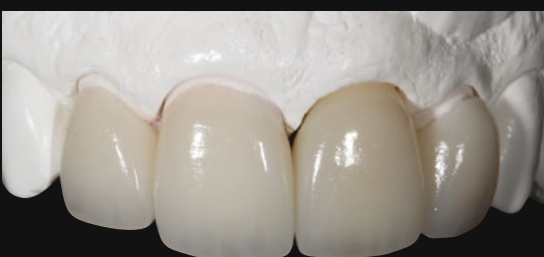


Fig. 12 - Veneers and jacket on model

Fig. 13 - Veneers e jacket

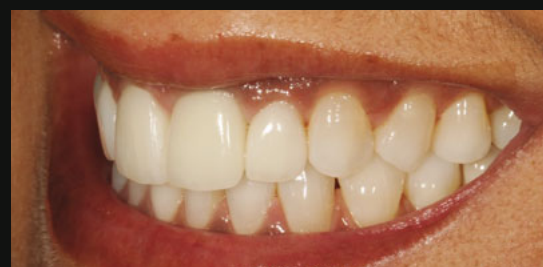
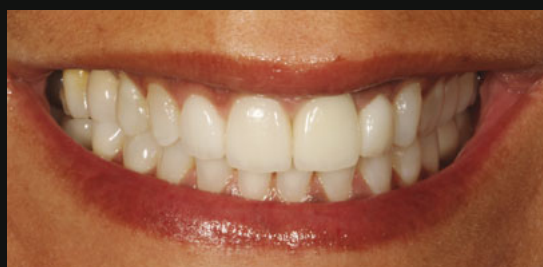
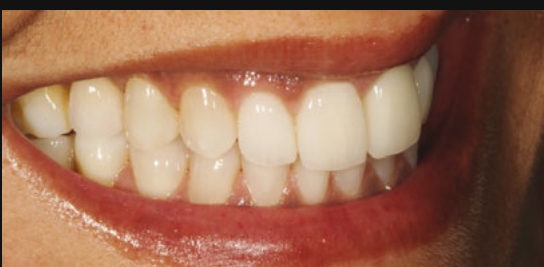Fig. 14 - Final smile photography

Fig. 15 - 11, 21 and 22 veneers and 21 jacket

Fig. 16 - Final smile photography

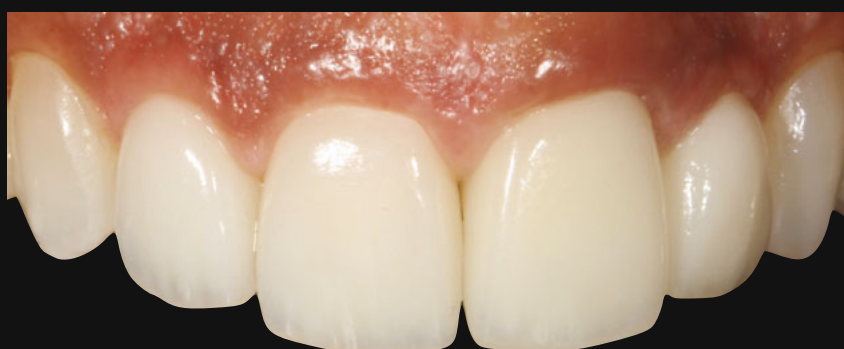

Fig. 17 - Final close-up