

Amorim T.^{*†} DDS, Amorim A.[†] DDS, Nunes da Silva V.[†] DDS, Pereira J.[†], Fonseca L.^{**} TPD

* Autor † Instituto Superior de Ciências da Saúde - Egas Moniz ** Faculdade de Medicina Dentária Universidade de Lisboa

COMBINATION OF DIRECT AND INDIRECT RESTORATIONS

IN THE AESTHETIC ZONE: CLINICAL CASE

CASE DESCRIPTION: male, healthy, aged 23, attended the clinic unhappy with the aesthetics of his smile. The patient had large composite resin restorations on the teeth 11, 12, 21 and 22, with excess and bad aesthetics. The teeth 11, 21 and 22 had endodontic treatment without periapical pathology. A diagnostic wax-up was carried out to preview the final form of the restoration. The restorations of endodontic treated teeth were replaced with new restorations. Bleaching was performed with carbamide peroxide at 10%. The teeth 11, 21 and 22 were prepared to feldspathic veneers. After the final impression the provisionals were carried out with bis-acryl resin. Veneers were bonded with heated composite at 55° with rubber dam, and a direct restoration in composite was carried out on the tooth 12.

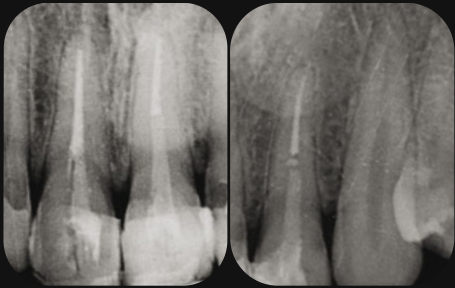


Fig. 1 - Initial periapical x-ray

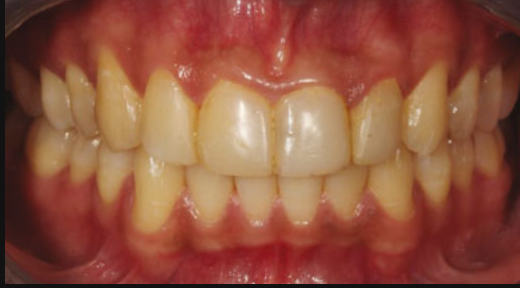

Fig. 2 - Initial intraoral photo

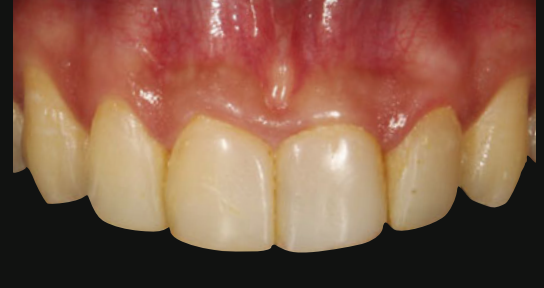

Fig. 3 - Initial close-up

DISCUSSION: With the development of adhesion, nowadays we have many materials and techniques for performing aesthetic restorations in the anterior sector. Indirect veneers and direct composite restorations are scientifically proved to be a very feasible option both aesthetically and functional. Both materials have biomimetic and biomechanical behavior similar to natural tooth, requiring minimally invasive preparations.

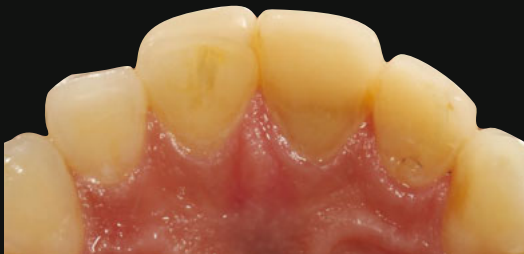

Fig. 4 - Occlusal after bleaching and new direct restorations

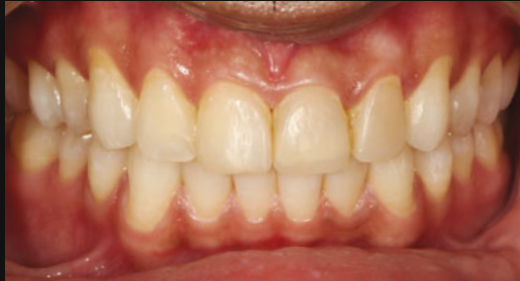

Fig. 5 - Intraoral after bleaching and new direct restorations

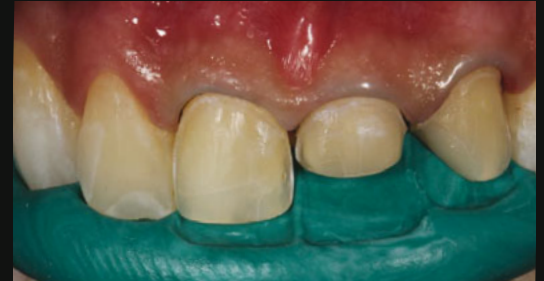

Fig. 6 - palatal matrix to control tooth preparation

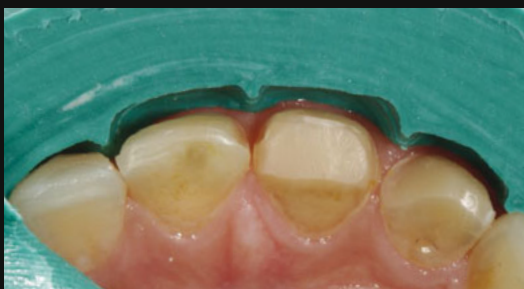

Fig. 7 - Buccal matrix to control tooth preparation

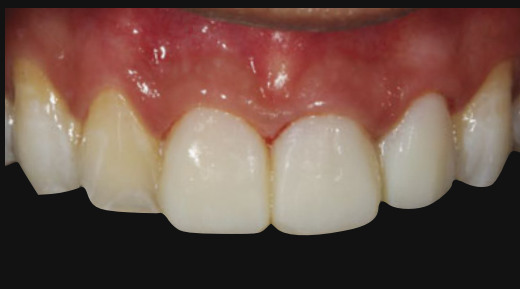

Fig. 8 - Provisional veneers of 11, 21 and 22 in bis-acrylic resin

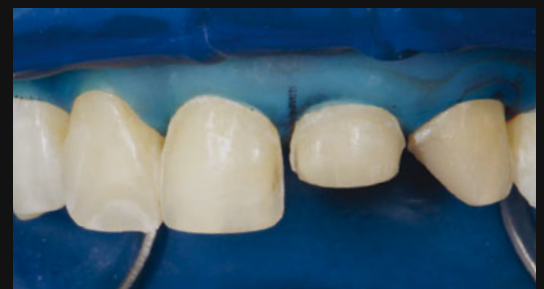

Fig. 9 - Rubber dam for adhesive cementation

CONCLUSION: Through the combination of different materials and techniques, it was possible to rehabilitate the function and esthetics of the smile, promoting a correct occlusal relationship. Both veneers and direct restorations present as an excellent alternative in such treatments as they allow highly esthetic and minimally invasive results.

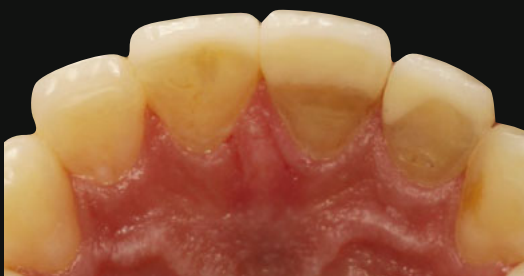

Fig. 10 - Final occlusal photo

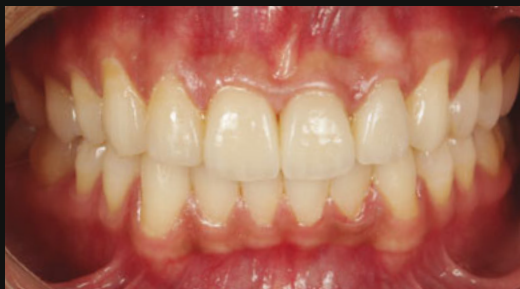

Fig. 11 - Final intraoral photo

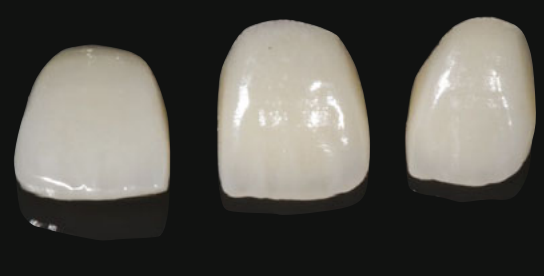

Fig. 12 - Feldspathic veneers of 11, 21 and 22

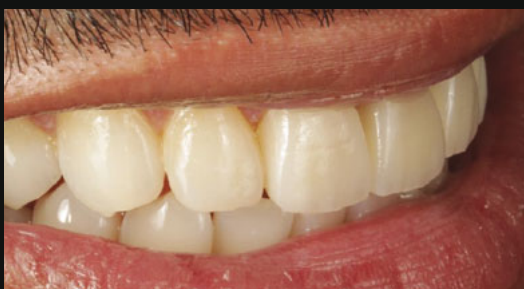

Fig. 13 - Final photo

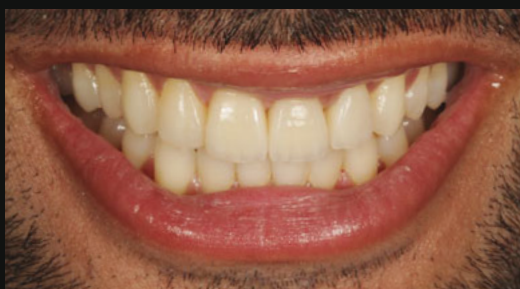

Fig. 14 - Final photo

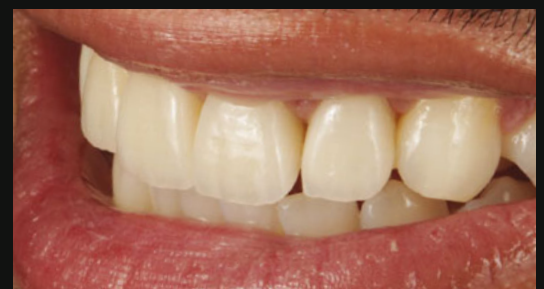

Fig. 15 - Final photo

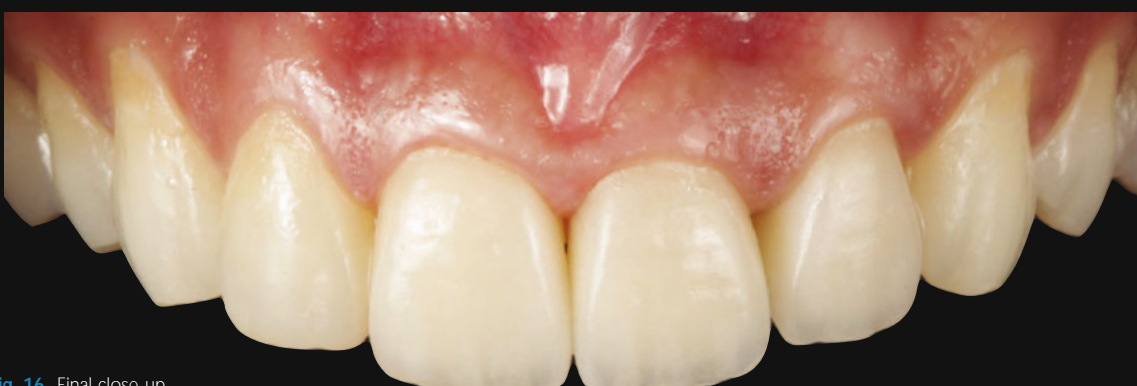

Fig. 16 - Final close-up