



EMERGENCY TREATMENT OF A CROWN-ROOT FRACTURE

Pestana, M.C.* Reis, G.N.* Sousa, A.J.**

*MSc in Dental Medicine students at Instituto Superior de Ciências da Saúde Egas Moniz
**DDS, Anatomy and Conservative Dentistry Assistant Professor at ISCSEM

Abstract

Twenty-one-year-old patient with no relevant prior clinical conditions came to the clinic due to an emergency regarding the tooth 1.3 which presented a crown-root fracture caused by an aggression, the tooth was previously intact. Due to the fracture configuration to position the clamp on the tooth 1.3 the mucoperiosteum was detached distally from the 1.1 and mesially from the 1.4 so that the clamp could be grasped directly to the bone. After direct pulp capping with calcium hydroxide and applying glass ionomer, the fragment was attached using dental adhesive and heated composite.

Objectives

Immediate and definitive reattachment of the fragment.
Describing the clinical procedure so that it is reproducible.

Introduction

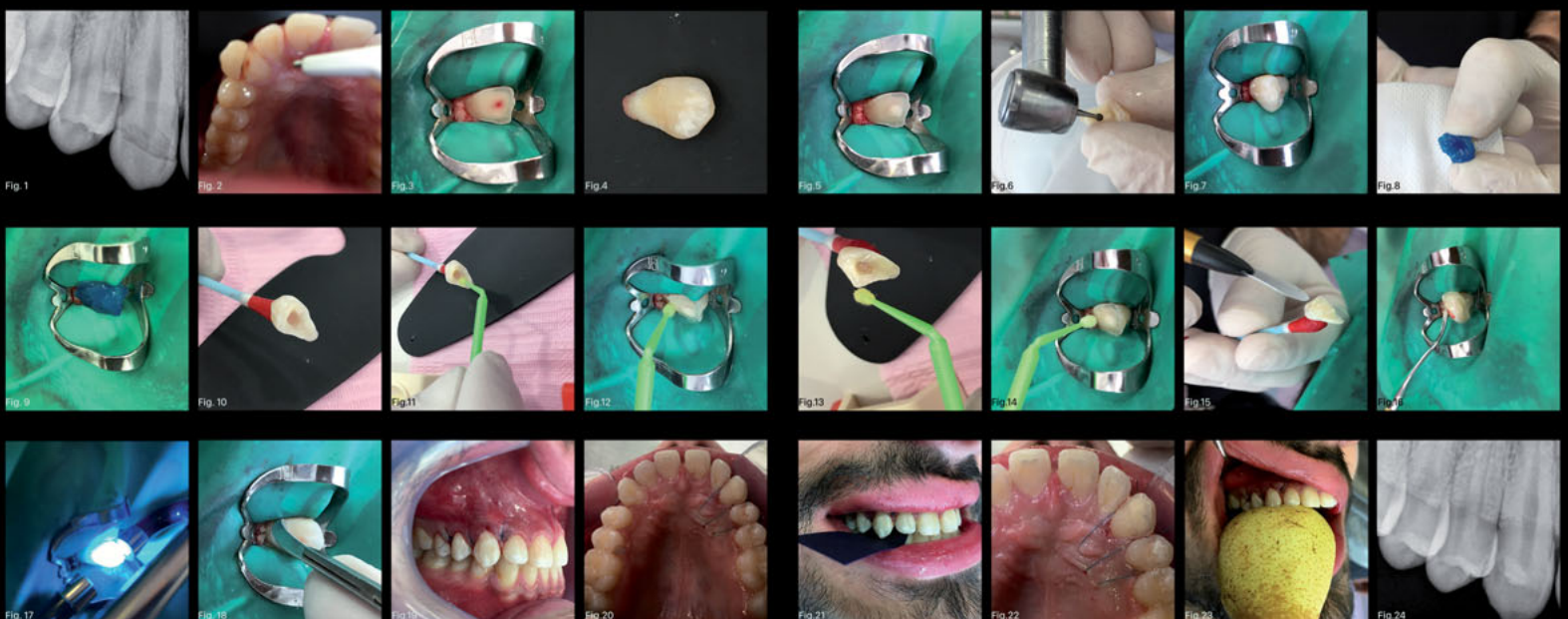Biological width invasion regarding crown-root fractures increases the execution difficulty degree when placing the dental dam so that there is no contamination of the operative field. However, if the bleeding can be controlled and aseptic conditions guaranteed reattaching the fragment has advantages over other procedures.

Many times this kind of trauma requires a multidisciplinary approach using other fields in Dental Medicine other than operative dentistry such as endodontics and surgery so that function and aesthetics can be re-established.

In this instance without mucoperiosteum detachment, it would not be possible to achieve the necessary isolation jeopardizing adhesion and probably the kind of treatment that was performed. Nevertheless, most of the crown-root fractures end up requiring further endodontic treatment. ⁽¹⁾

Materials

- Articaïne 72mg/1,8ml - (Inibsa)
- Sodium hypochlorite at 5,25%
- Calcium hydroxide Life - (Kerr)
- Glass ionomer Ionoseal - (VOCO)
- Orthophosphoric acid at 37%
- Three step adhesive system Optibond FL - (Kerr)
- Composite resin enamel plus HRI UD2 - (Micerium)
- Nylon monofilament suture 5/0 - (Ergon Sutramed)
- Double tip photopolymerizer Demetron VCL 501 - (Optilux)

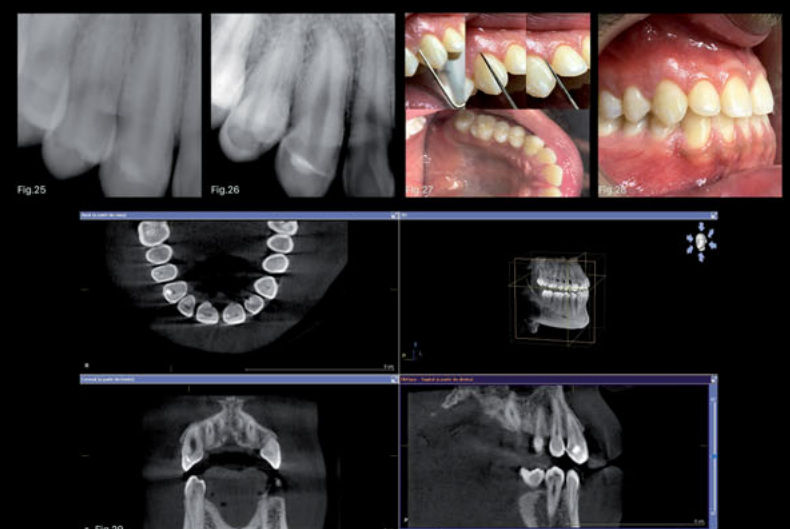


Clinical procedure ^{(1) (2) (3)}

- 1- Initial x-ray
- 2- Anaesthetic in a fair amount to promote vasoconstriction
- 3- Removal of the buccal wall
- 4- Rubber dam isolation from 2.4 to 1.4
- 5- Impossibility to grasp the 212 clamp on the tooth 1.3
- 6- Isolation removal from 1.3 keeping it on the other teeth
- 7- Mucoperiosteum detachment distally from 1.1 and mesially from 1.4
- 8- Traded the isolation from 2.4 to 1.4 for isolation only on the 1.3
- 9- Clamp grasped directly to the bone, only way to gain retention
- 10- Irrigation with sodium hypochlorite at 5,25%
- 11- Direct pulp capping with calcium hydroxide
- 12- Glass ionomer
- 13- Box in the palatal wall of the fragment so that there is no interference with the calcium hydroxide and the glass ionomer
- 14- Fragment adaptation test
- 15- Etching the fragment and the tooth
- 16- Adhesive system on the fragment and the tooth
- 17- Heated composite resin applied
- 18- Excess removal with surgical blade number 12
- 19- Double tip photopolymerization
- 20- Excess removal with surgical blade number 12
- 21- Dental dam removal
- 22- Suture with nylon monofilament 5/0
- 23- Occlusion verification
- 24- Resistance test
- 25- Control x-ray

Follow-Up ⁽⁴⁾

Electric test using C-Root VI (Coxo), the following results were obtained:
1) After one week first response at 11 units, maximum bearable stimulus at 14 units
2) After 4 weeks first response at 12 units, maximum bearable stimulus at 16 units. CBCT after 4 weeks (Fig.29)



Discussion

Advantages

Dental fragment bonding in immediate post-trauma keeps function, aesthetics and also reduces emotional stress.

Disadvantages

Mucoperiosteum detachment requires very high technical skills and can cause further damage to the periodontal tissues. In a case of bleeding adhesion will be compromised.

Conclusion

Immediate dental fragment bonding allows excellent results only in one appointment leaving the tooth functional and aesthetic; if further endodontic treatment is required it will be done in a complete tooth.