

# Immediate implant with immediate loading in the esthetic zone



Santos Silva, P. <sup>1</sup>; Peres, F. <sup>2</sup>  
<sup>1</sup>) DDS, Msc - Oral Surgery Specialist  
<sup>2</sup>) DDS, Orthodontics Specialist

## Introduction

Patient 42 years old, healthy and fit complained of pain on biting on 11. Upon metal-ceramic crown removal, it is noticed a vertical root fracture.

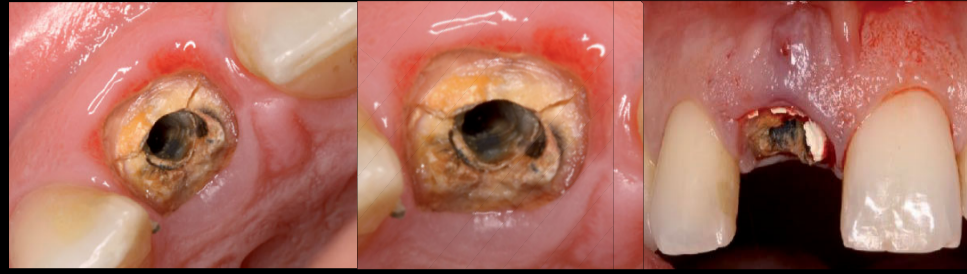


Fig. 2 - Inicial Intraoral photographies

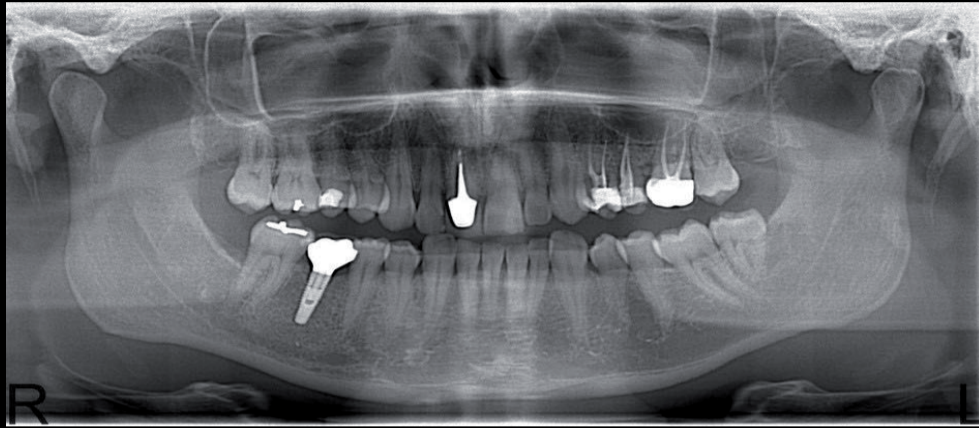


Fig. 1- Panoramic radiography

## Purpose

Extraction of 11 and implant placement at the same surgical time followed by an immediate loading with an acrylic provisional crown which was, 6 months later, replaced by a final zirconia crown.

## Methods

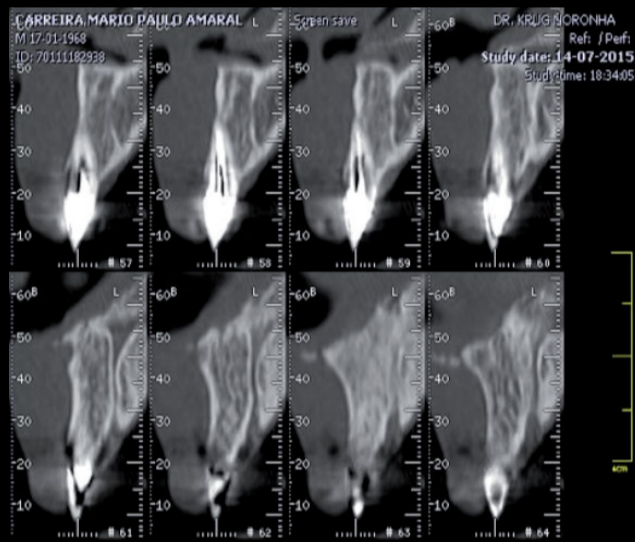


Fig. 3 - Computerized tomography

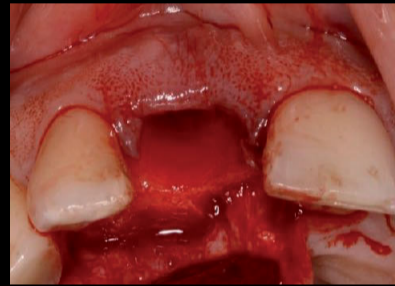

Fig. 4 - Flapless atraumatic extraction of 11

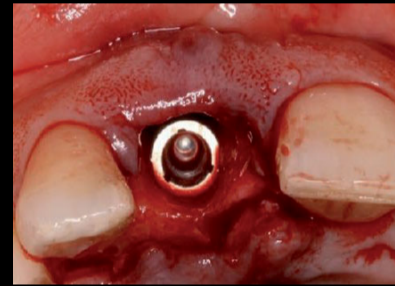


Fig. 5 - Camlog Promote Plus @ 4,3 13mm implant placement - palatal approach

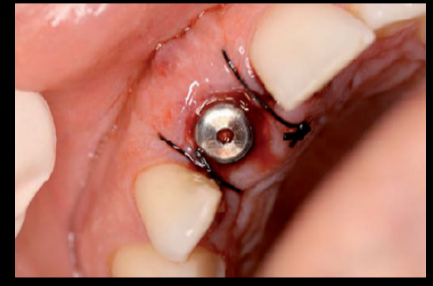

Fig. 6- GAP between implant and buccal plate regenerated with Geistlich Bio-Oss® Collagen

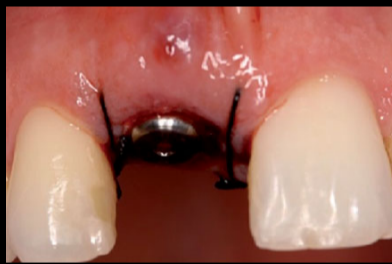

Fig. 7- Front view of the healing cap with Braun® silk non-absorbable 4/0 suture

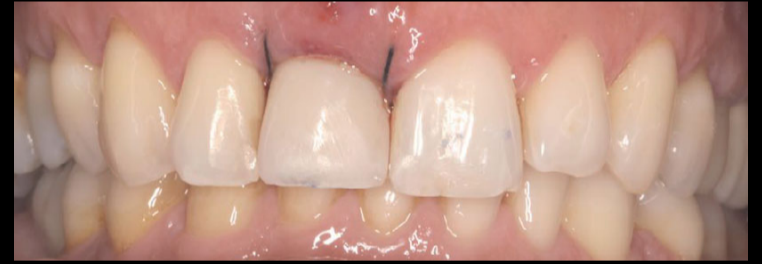

Fig. 8- Provisional acrylic crown on the day of the implant placement

## Results

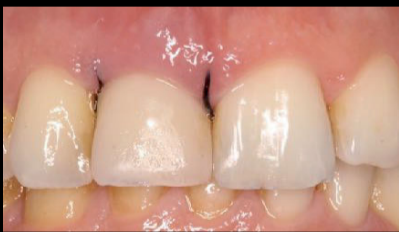

Fig. 9- Provisional acrylic crown 10 days after surgery, on the day of the suture removal

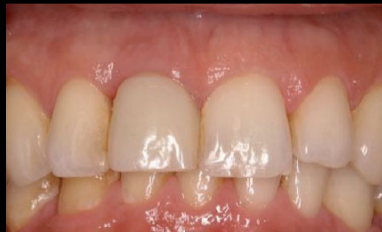

Fig. 10- Provisional acrylic crown 3 weeks after surgery

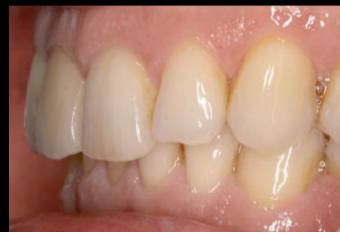

Fig. 11- Final zirconia crown 6 months after surgery - lateral view (left side)

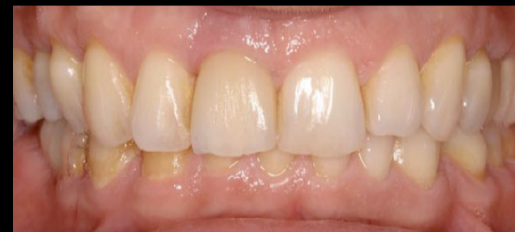

Fig. 12- Final zirconia crown 6 months after surgery - front view

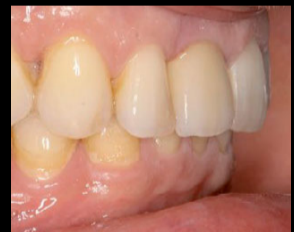

Fig. 13 - Final zirconia crown 6 months after surgery - lateral view (right side)

## Conclusion

As the buccal plate was intact, an immediate implant with an immediate provisional crown allowed to keep an adequate gingival margin with a correct papilla position. A follow-up period of 4 years shows good aesthetics with stable hard and soft tissues.

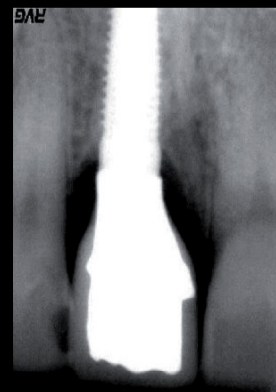


Fig. 14- Baseline - periapical radiography on the day of the implant placement

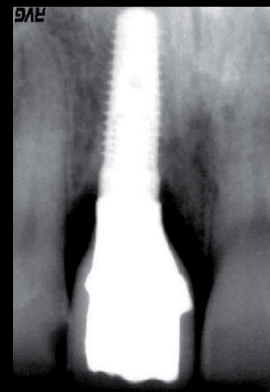


Fig. 15 - Periapical radiography 4 years after implant placement

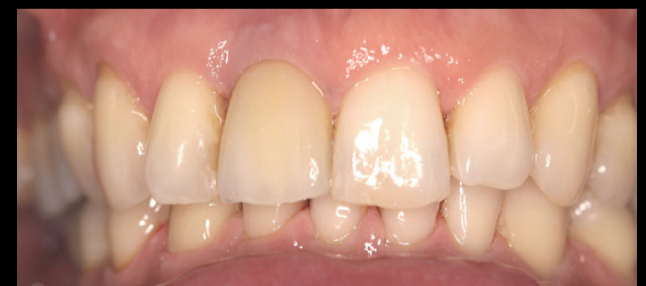

Fig. 16 - Final zirconia crown 4 years after surgery - front view

## Bibliography

- 1) Felice P, Zucchelli G, Cannizzaro G, Barausse C, Diazzi M, Trullenque-Eriksson A, Esposito M. Immediate, immediate-delayed (6 weeks) and delayed (4 months) post-extractive single implants: 4-month post-loading data from a randomised controlled trial. *Eur J Oral Implantol.* 2016;9(3):233-247.
- 2) Van Nimwegen WG Goené RJ, Van Daelen AC, Stellingsma K, Raghoobar GM, Meijer HJ. Immediate implant placement and provisionalisation in the aesthetic zone. *J Oral Rehabil.* 2016 Oct;43(10):745-52.
- 3) Mangano C, Raes F, Lenzi C, Eccellente T, Orolani M, Luongo G, Mangano F. Immediate Loading of Single Implants: A 2-Year Prospective Multicenter Study. *Int J Periodontics Restorative Dent.*