



David Couchat

David Couchat

# Prevention of tooth impaction with Invisalign: a case report

**Key words** aligner, en-masse distalization, impacted tooth, Invisalign, space reopening, unerupted tooth

*Pulling down an impacted tooth is always a challenge for the orthodontist. It must represent his highest priority before starting any other treatment phase. This article attempts to highlight the importance of early prevention and diagnosis when we encounter this condition. It also discusses the interest in using aligners in such cases, provided that the practitioner follows certain guidelines and starts with the specific staging of the ClinCheck. In this case report, a palatally impacted canine has been avoided, along with a slight Class II malocclusion treatment, using aligners from the Invisalign system.*

## Introduction

### Incidence

Impacted teeth are those that fail to erupt in the correct position into the dental arch. Studies have shown that impaction of canines is a normal condition in orthodontic treatment. The incidence in patients, regardless of their ethnic origin, is about 2%, occurring mostly at the maxil-

lary arch (from 1% to 3%), almost always palatally (85%) and more often in females (two out of three) than in males. Moreover, the age of the patient is crucial. Indeed, unless the tooth is in a difficult location or position, we have almost a 100% success rate in teenagers, while with adults, chances of success decrease as the patient gets older: the longer we wait, the more ankylosis of the teeth is stimulated, and the less we observe tooth movement.

### Investigations

At any age, our protocol includes several steps when there is a suspicion of impaction: the first is to perform a panoramic radiograph. If any abnormal location of a tooth is detected, further examination is undertaken, including a detailed family history and palpation. The second step consists of performing 3D imaging, usually a CBCT.

This case report describes the procedure of treatment of an unerupted left maxillary canine (tooth 23) of a seven-year-old patient on her first consultation.

## Case presentation

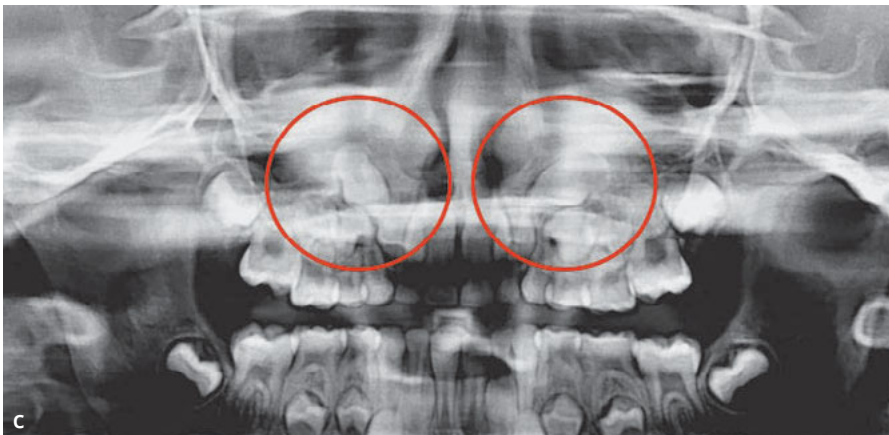
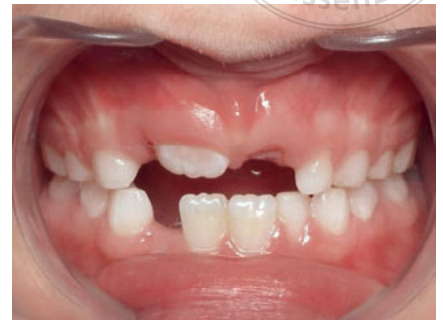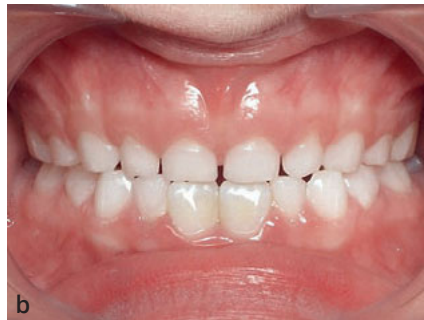### First phase

#### *Radiographic examination:*

In March 2012, the seven-year-old girl (CG) presented with skeletal Class I associated with a maxillary endognathia and

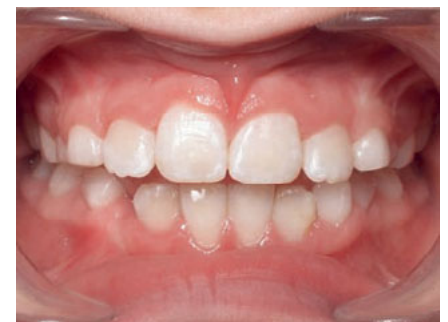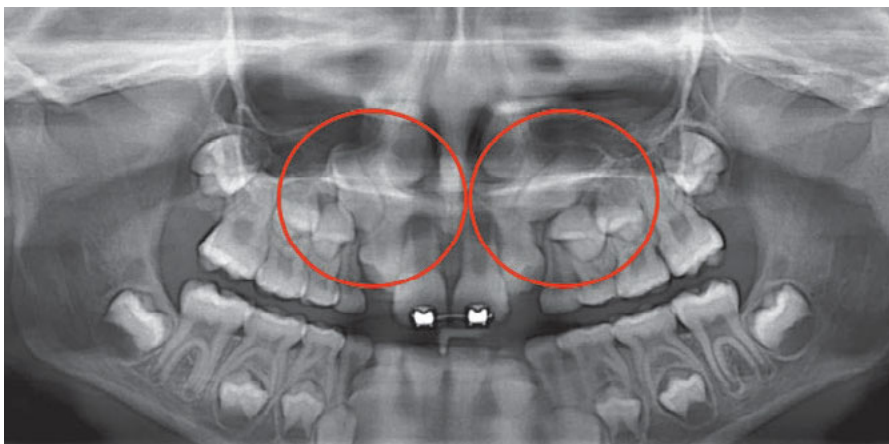
David Couchat, Dr  
Amiral Park Orthodontie,  
6, Rue Jean Baptiste Reboul  
13010 Marseille, France  
Tel : 00 33 4 91 77 91 21

Correspondence to: Dr David Couchat  
E-Mail: davidcouchat@wanadoo.fr



**Fig 2** September 2012: Eruption of maxillary central incisors. In January 2013, two brackets are bonded on teeth 11 and 21 and 1 month later (see Fig 3), a follow-up panoramic radiograph revealed that 23 is not keeping pace with 13: the latter goes down faster. Tooth 13 has become more vertical, while 23 is still horizontally positioned.

**Figs 1a to c** The patient (CG), March 2012. a) portrait; b) intra-oral photo; c) panoramic radiograph.



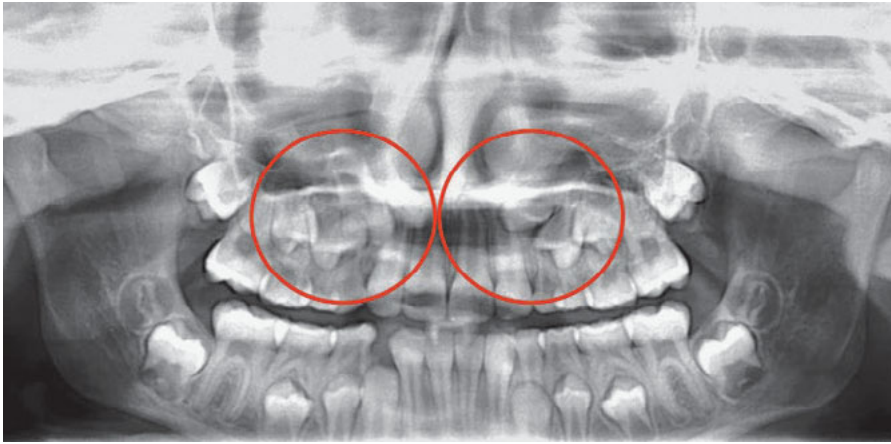
**Fig 4** October 2013. The maxillary incisors have erupted into the dental arch.

**Fig 3** Panoramic radiograph, February 2013. Tooth 23 does not keep pace with 13. In October 2013 (see Fig 4), the maxillary central and lateral incisors teeth have erupted and the Quad Helix is removed. At this point we noticed, as a wished effect, a Class II (anterior overjet) due to a loss of anchorage.

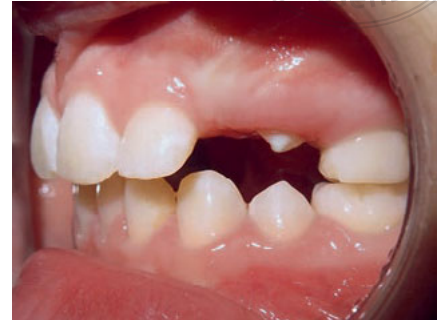an edge-to-edge incisor bite. Teeth 31 and 41 had just erupted into the oral cavity. At that point, the radiograph (Fig 1c) did not allow identification of any impaction. However, the left maxillary canine appeared to be more horizontally positioned and

differently oriented compared with tooth 13. The second molars were in the process of calcification.

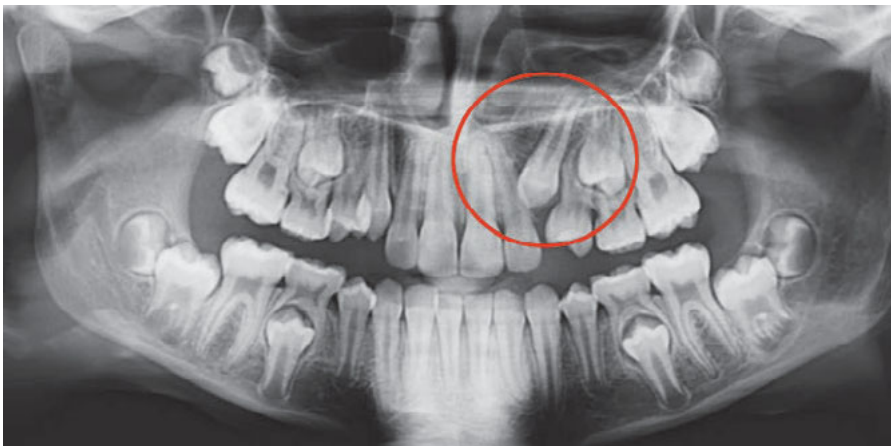After 6 months, in September 2012, a follow-up consultation was made and it was observed (Fig 2) that teeth 11



**Fig 5** July 2014. A panoramic radiograph shows the thickness of the dental follicle around tooth 23.



**Fig 6** July 2014. Extraction of teeth 63 and 64. Finally, in May 2016, it became obvious that without any intervention, the left maxillary canine (23) would stop its process of calcification and become impacted. Indeed, tooth 24 has completely erupted and there is no room for the canine to erupt naturally (see Fig 7).



**Fig 7** May 2016. A panoramic radiograph revealed the unerupted canine (23) This first phase of the treatment allowed us to correct the maxillary dental arch form with the assistance of the Quad Helix and guide the eruption of permanent teeth thanks to the deciduous teeth extraction.

and 21 had started to come out from the dental arch. There was a risk of there being a lack of room for teeth 12 and 22. Consequently, a Quad Helix was placed for expansion.

In July 2014, another panoramic radiograph was made (Fig 5), and an increased thickness of the dental follicle around tooth 23 was detected, revealing tooth eruption issues.

The decision was made to extract deciduous teeth 63 and 64 and to wait for 1 more year without any further action, giving tooth 23 a chance to erupt (Fig 6). At this stage, a minor dental Class II was observed on the same side of the impacted canine.

No more spontaneous improvement of eruption was expected at this stage. Therefore, a CBCT scan was performed and confirmed the diagnostic of impaction (Fig 8).

## Second phase

### *Treatment objectives*

The main goal was to reopen the spaces with en-masse distalization of teeth 24, 65 and 26. This had to be achieved at the same time as correcting the Class II malocclusion and moving mandibular arch teeth into alignment. This second phase of the treatment will be carried out with the Invisalign system.

### *Treatment progress*

The ClinCheck represented a crucial parameter to take into consideration: we could not follow the regular staging provided by the Invisalign software "Treat". Indeed, to make sure that we could correct the Class II malocclusion, the

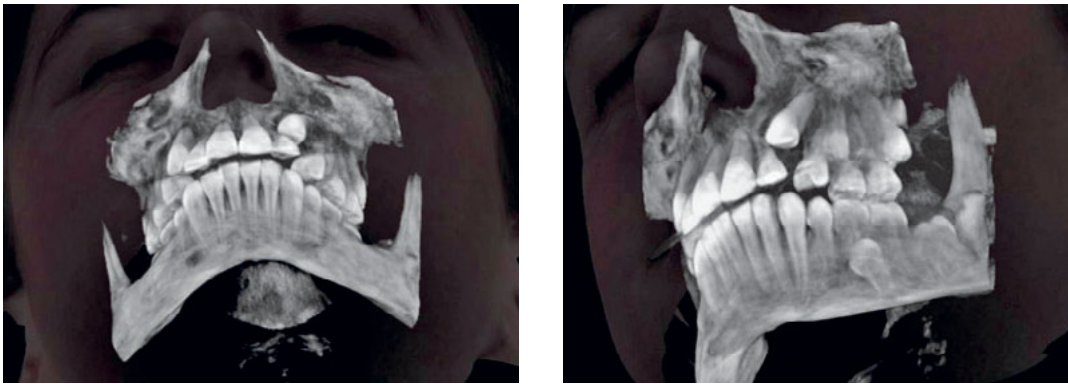


Fig 8 A cone beam scan reveals the position and location of tooth 23.

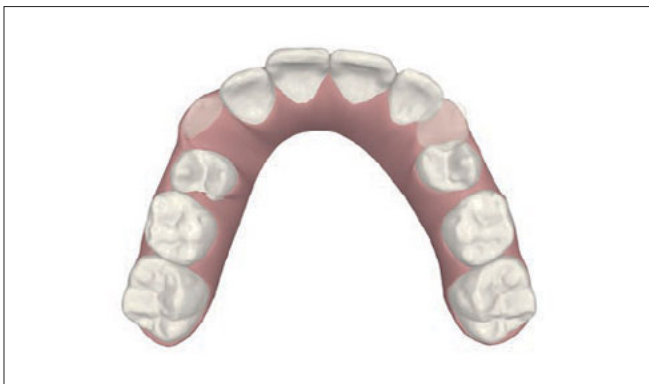

Fig 9 ClinCheck Stage 0.

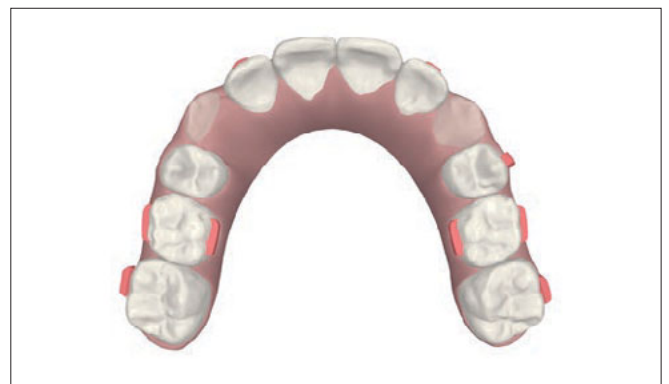
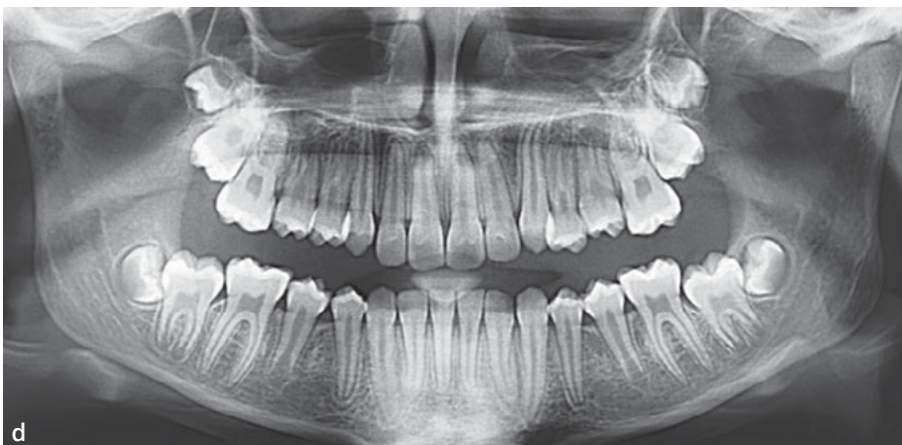
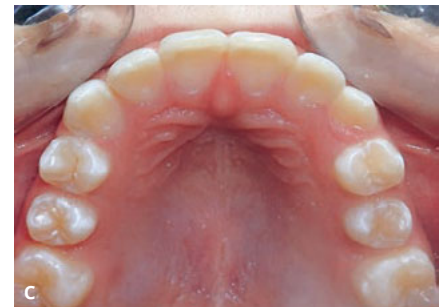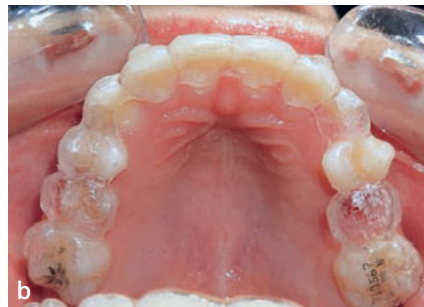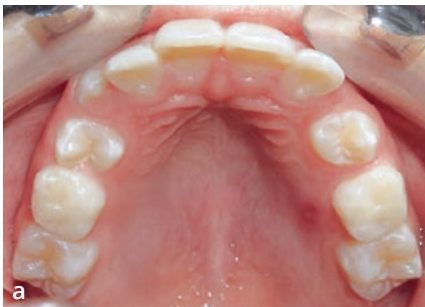Fig 10 ClinCheck, stage 55: space reopening.

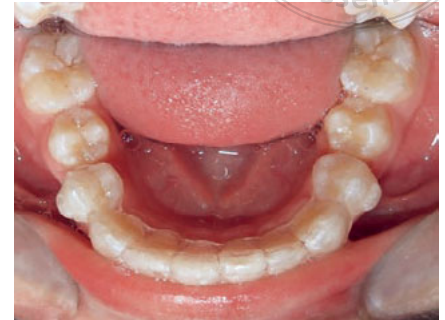

Figs 11a to d a) the initial situation at the start of Invisalign treatment. b) En-masse distalization in order to reopen the spaces. c) Final situation: spaces reopened. d) Tooth 23 favourably erupted into the oral cavity and located in an optimal position.

Fig 12 The patient in June 2017.



Fig 13 The mandibular aligner has been trimmed on the posterior second premolars and molars.



slight mandibular crowding and reopening the spaces at the same time, the modification of the ClinCheck should respect the following points:

1. Starting from the first aligner, reopening the spaces with simultaneous distalization of teeth 24, 65 and 26.
2. Aligning mandibular incisors from stage 0.
3. Increasing the number of aligners in order to slow down the velocity of tooth movement: we modified this from 35 aligners to 55.
4. Managing attachments: a limited number of attachments have to be bonded, but enough to make sure that we obtain a good fitting.
5. We will not use Class II elastics: so a slight loss of anchorage and an increase of the dental Class II might occur. But if the patient presents a Class I skeletal pattern with a skeletal Class III tendency, we admit this potential loss of anchorage and prefer to treat this condition during the third phase.

At the end of the treatment, GC was 12 years old and the left maxillary canine had successfully erupted (Fig 11d). All that remained to be corrected was the Class II malocclusion.

## Discussion

When a tooth has difficulty erupting, the first measure is to extract the deciduous teeth. If this is not sufficient, the orthodontist will proceed to the next step: reopening the spaces.

In this case, since the patient had a Class I malocclusion with a Class III tendency, an en-masse distalization was cho-

sen to allow a loss of anchorage to benefit the full treatment.

The reasons for selecting this particular ClinCheck staging (as described earlier) are:

1. The regular protocol provided by Invisalign performs a sequential distalization: it means "the aligners are set up to distalize one tooth at a time". On the contrary, we decided to use en-masse distalization to prevent the canine impaction in order to reopen the spaces as rapidly as possible, which would have been difficult to achieve as quickly with the Invisalign sequential distalization.
2. With 55 aligners, instead of the 35 initially programmed, the patient had enough time to wait for the canine eruption, changing aligners weekly.
3. A good fitting made possible with a good management of the attachments would ensure more efficiency of the forces while preserving the aesthetic side.

Another aspect worth considering is the particular use of the leeway space as a good opportunity to relieve the Class II malocclusion. Indeed, we continued to align with only two attachments on teeth 34 and 44 and aligners were specially trimmed on the posterior second premolars and molars of the aligner (see Fig 13). This had led to the mesialization of teeth 35 and 45 on one hand, and 36 and 46 on the other; thus helping to correct the dental Class II malocclusion.

From this point, the third phase starts with a classical teen treatment using the regular staging provided by Invisalign System.



## Conclusion

The advantages of the Invisalign system to prevent tooth impaction are evident, but timely treatment in such cases is crucial. In this situation, indeed, regular and early follow-ups explain the successful outcome of the treatment. The patient (CG) received orthodontic follow-ups from the age of seven, allowing for the detection of the risk of the uneruption of tooth 23.

Once the potential impaction had been located, an interceptive treatment was started, involving reopening the spaces and the use of the coil-spring effect.

Unfortunately, such patient follow-up may not always be feasible. The practitioner is sometimes confronted with situations where the patient has not been diagnosed on time: the next article will show the sequence of treatment of a patient with two impacted canines.

## References

1. Chenin Orthodontics, ClinCheck evaluation guide, 2017. Staging is the process of sequencing tooth movements from the initial to the final position. <http://www.cheninortho.com/File%20Library/Professional/7.pdf>.
2. Manne R, Gandikota C, Juvvadi SR, Rama HR, Anche S. Impacted canines: etiology, diagnosis, and orthodontic management. *J Pharm Biomed Sci* 2012;4:S234–238.
3. Benhamou Giuly A. Étude prospective sur 127 canines incluses maxillaires: durée de traitement et caractérisation de la population. *L'Orthodontie Bioprogressive* Vol 23:Décembre 2015.
4. SFSCMFCO - Société Française de Stomatologie, Chirurgie Maxillo-Faciale et Chirurgie Orale. Prise en charge d'une canine incluse - Recommandations de Bonne Pratique. Juillet 2015:6.
5. Monnet-Corti V, Fouque-Deruelle C, Magneville B. Canine, a tooth unlike the others: periodontal and prosthetic consideration. *Rev Odont Stomat* 2011;40:151–172.
6. Motamedi MH. Surgical Exposure and Orthodontic Alignment of Impacted Teeth. *A Textbook of Advanced Oral and Maxillofacial Surgery*;Vol 2:2015.
7. Koutzoglou SI and Kostaki A. Effect of surgical exposure technique, age, and grade of impaction on ankylosis of an impacted canine, and the effect of rapid palatal expansion on eruption: a prospective clinical study. *Am J Orthodont Dentofacial Orthop* 2013;143:342–352.
8. This method can be associated with the coil-spring effect with dental braces.
9. Ravera S, Castroflorio T, Garino F, Daher S, Cugliari G, Deregibus A. Maxillary molar distalization with aligners in adult patients: a multicenter retrospective study. *Prog Orthod* 2016;17:12.
10. The leeway space is the arch circumference difference between the primary canine, first primary and second primary molars, and the permanent canine and the first and second premolars. According to Black's means, the maxillary arch leeway space is 1.9 mm, and the mandibular arch leeway space is 3.4 mm. *Mosby's Dental Dictionary* St Louis;Mosby:2007.
11. Ajith SD, Shetty S, Hussain H, Nagaraj T, Srinath M. Management of multiple impacted teeth: A case report and review. *J Int Oral Health* 2014;6:93–98.