

## Introduction

A skeletal class II patient may present a mandibular retrognathia. This condition can lead to an inefficient breathing pattern, suboptimal mastication due to the improper occlusion pattern as well as an unsatisfactory profile. Although mandibular hypoplasia is a rather common occurrence, the combination of orthodontic and orthognathic procedures can be the most appropriate treatment for moderate to severe discrepancies. The lengthening of the mandible ramus can be achieved through a split ramus osteotomy or, in more severe cases, through a distraction device. This intervention can be chosen in order to achieve better aesthetics and function therefore improving the patient's quality of life. The aim of this poster is to present a surgical-orthodontic approach for effective treatment of a skeletal class II associated with severe mandibular retrognathia.

## Materials and Methods

A twenty-three-year-old patient with severe skeletal class II presented to the Institute of Orthodontics looking for malocclusion correction. The patient had undergone previous orthodontic treatment at another center, however she presented both breathing and feeding difficulties as well as unappealing facial aesthetics. After careful consideration of the initial case tooth-borne distraction osteogenesis for mandibular lengthening and surgical orthodontic treatment were suggested as the best treatment option.

## Results

Roth 0,018 prescription fixed appliances were placed to level the arches followed by the placement of the tooth-borne distraction osteogenesis device which was activated twice bilaterally every 12 hours. At the end of the distraction, 11 mm of mandibular lengthening were obtained. After this intervention the orthodontic treatment progressed in order to prepare the patient for a orthognathic surgery of maxillary impaction and mandibular repositioning. A significant improvement in the ANB angle was achieved from 16° to 4°. Despite the facial soft tissue improvement, the convex profile still didn't meet the patient's aesthetic expectations so, the patient was subsequently submitted to a genioplasty. Six months after the surgical procedures, the mandibular advancement remained stable and the patient reported a significant improvement in breathing and facial aesthetics, granting a better quality of life.

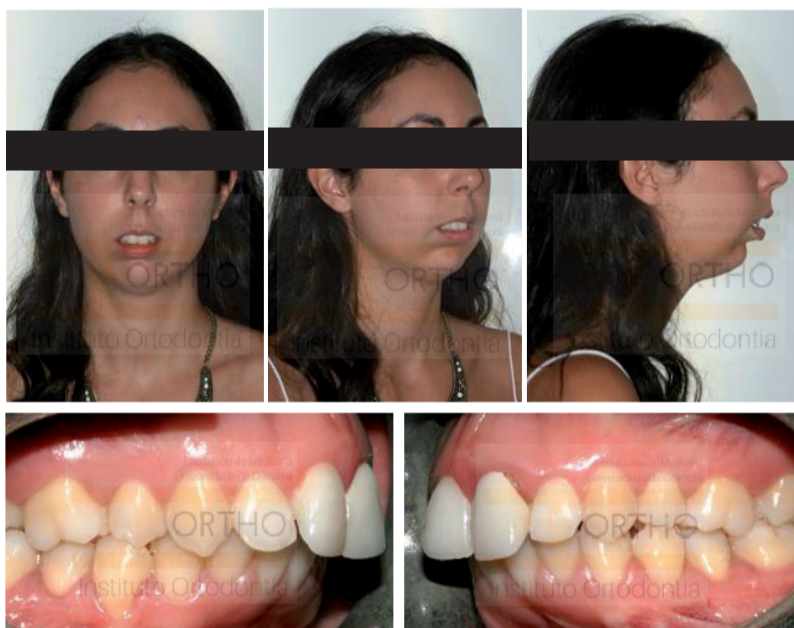

Fig.1- Initial photographs – extraoral and intraoral

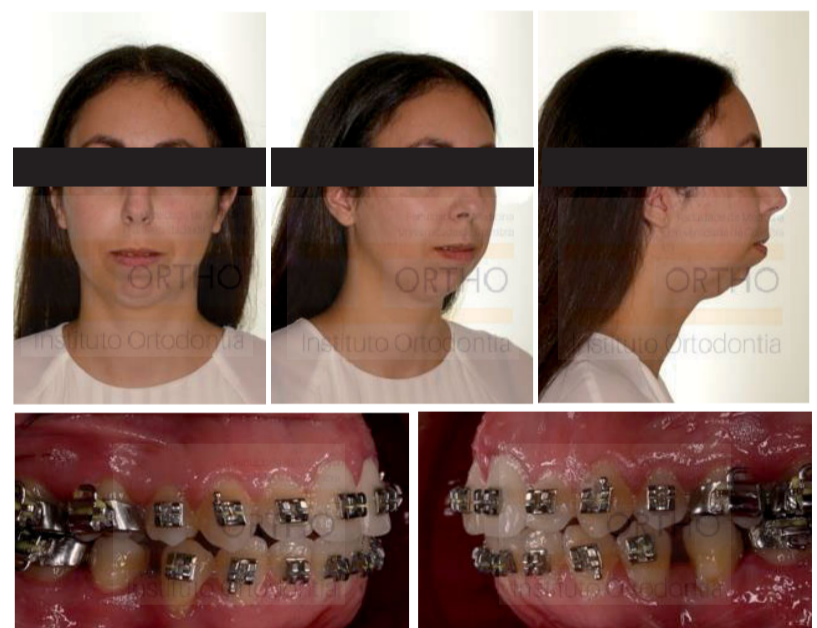


Fig. 2- Post-distraction photographs – extraoral and intraoral

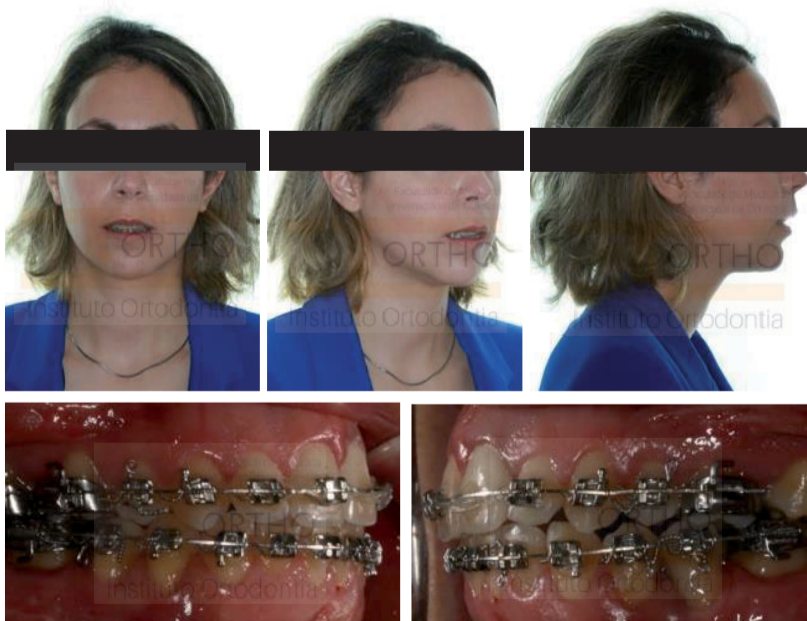

Fig.3- Post-surgical photographs – extraoral and intraoral

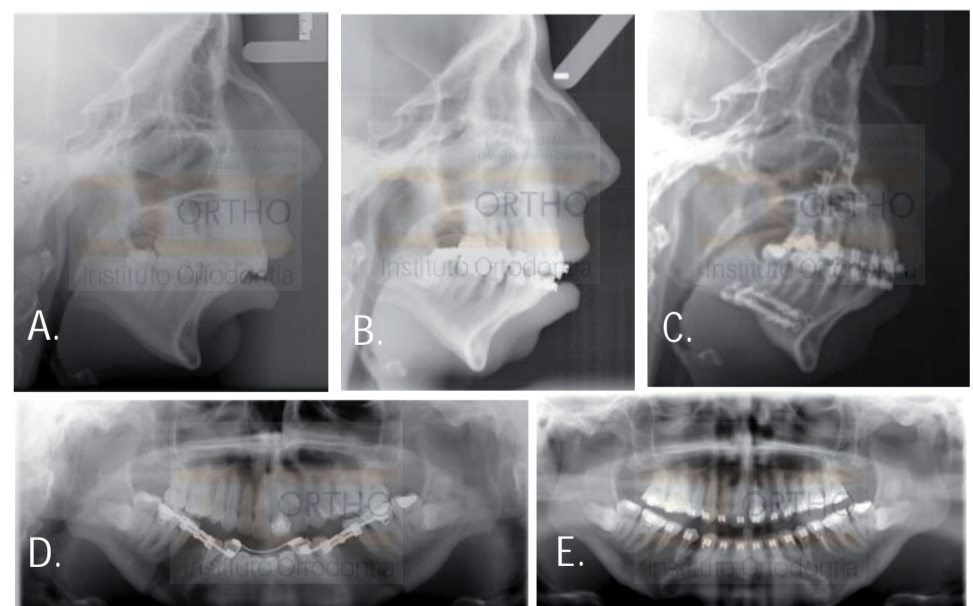


Fig. 4- X-ray exams: lateral cephalograms before treatment (A.); after distraction (B.); after bimaxillary surgery (C.); orthopantomography immediately after distraction (D.); orthopantomography one year post distraction (E.).

## Discussion and Conclusion

The patient had re-established a functional occlusion, a more suitable breathing pattern, a desirable profile and an overall pleasant facial aesthetic.

## References

