

Antonio Ciardo, Cornelia Frese, Ti-Sun Kim

Minimally invasive esthetic and functional rehabilitation after systematic periodontal therapy: a case report

Anamnesis: The patient was 45 years old at the time of his first consultation in 2017. He was referred for the treatment of his „progressive periodontitis“ and had not undergone previous periodontal therapy. The patient had no general diseases, took no medication and claimed to be a smoker (35 pack years). His main complaints were that he suffered from tooth hypersensitivity, tooth mobility, bleeding gums and pain on biting in the posterior right upper jaw.

Clinical findings: Oral inspection revealed generalized soft and localized hard biofilm formation. Teeth 17–26 and 38–47 were present and they responded positively to sensitivity testing and negatively to percussion. The marginal gingiva appeared slightly edematous and swollen. There were generalized probing pocket depths of more than 7 mm and localized values up to 12 mm for teeth 45 and 46. The attachment level was generally above 7 mm and locally up to 13 mm for tooth 14. Grade I–III tooth mobility and grade 1–2 furcation involvement were recorded. Tooth 22 was elongated, rotated and protruded. Panoramic X-ray imaging revealed that the alveolar ridge was located in the apical third of the roots as well as the presence of multiple areas of furcation involvement and periapical translucencies.

Diagnosis:

- Periodontitis Stage IV, generalized, grade C with modifying risk factor smoking
- Endo-periodontal lesion grade 3 at teeth 16 and 17
- Suspected endo-periodontal lesion at teeth 26, 38 and 47
- Suspected occlusal trauma at teeth 22 and 45
- Unharmonious anterior situation (multiple recessions, anterior teeth tipping towards vestibular, protrusion of tooth 22)

Therapy: The patient quit smoking until re-evaluation. Teeth with a mobility grade \geq II were splinted using composite. Root canal treatments of teeth 16, 17 and 26 as well as the functional reduction of teeth 22 and 45 were performed. Tooth 38 was extracted. Subsequently, anti-infective therapy ensued in form of a full-mouth-disinfection with adjuvant antibiotics. After re-evaluation and supportive periodontal therapy (SPT), corrective periodontal surgery of teeth with persisting probing pocket depths \geq 6mm was performed by means of distal wedge excisions, root amputations and furcation tunneling. Six months after periodontal surgery, the periodontium appeared stable. According to the

Section of Periodontology, Department of Conservative Dentistry, Clinic for Oral, Dental and Maxillofacial Diseases, University Hospital Heidelberg: Dr. Antonio Ciardo; Prof. Dr. Dr. Ti-Sun Kim, eMBA

Section of Restorative and Preventive Dentistry, Department of Conservative Dentistry, Clinic for Oral, Dental and Maxillofacial Diseases of the University Hospital Heidelberg: Prof. Dr. Cornelia Frese

Translation from German: Christian Miron

Citation: Ciardo A, Frese A, Kim T-S: Minimally invasive esthetic and functional rehabilitation after systematic periodontal therapy: a case report. Dtsch Zahnärztl Z Int 2020; 2: 119–130

Peer-reviewed article: submitted: 10.12.2019, revised version accepted: 10.02.2020

DOI.org/10.3238/dzz-int.2020.0119-0130

patient, there were subjective deficiencies due to interdental black triangles, recessions and tooth tipping towards vestibular in the anterior region. Thus, direct shape corrections of teeth 14–24 and 34–44 and closure of the interdental gap between teeth 43 and 44 followed.

Conclusion: After successful periodontal treatment, functional corrections and direct restorative techniques with composite can be used even for patients with severe periodontal disease in order to achieve minimally invasive and successful treatment outcomes.

Keywords: adjuvant antibiotic administration for subgingival instrumentation; endo-periodontal lesion; endodontic therapy; direct composite splinting; resective periodontal surgery; root amputation; furcation tunneling; shape correction; tooth widening; rehabilitation; smoking cessation; esthetics

Anamnesis

General anamnesis

The 45-year-old patient was in general good health, did not take any medication, and was a current smoker (35 pack years). He had a height of 172 cm and weighed 85 kg.

Specific anamnesis

The patient presented himself in May 2017 following a referral from

his family dentist for further treatment of his advanced periodontitis. He reported sudden tooth mobility, heavy bleeding and painful gums. He suffered from pronounced hypersensitivity and from pain on biting in the posterior upper jaw. He claimed to brush his teeth twice daily with an electric toothbrush without performing additional interdental cleaning. According to his knowledge, no systematic periodon-

tal therapy had thus far been performed.

Social anamnesis

The patient was married and had 2 children. He was employed. His family history of oral disease was inconspicuous.

Patient expectations

As part of the treatment plan, the patient's primary concern was maxi-

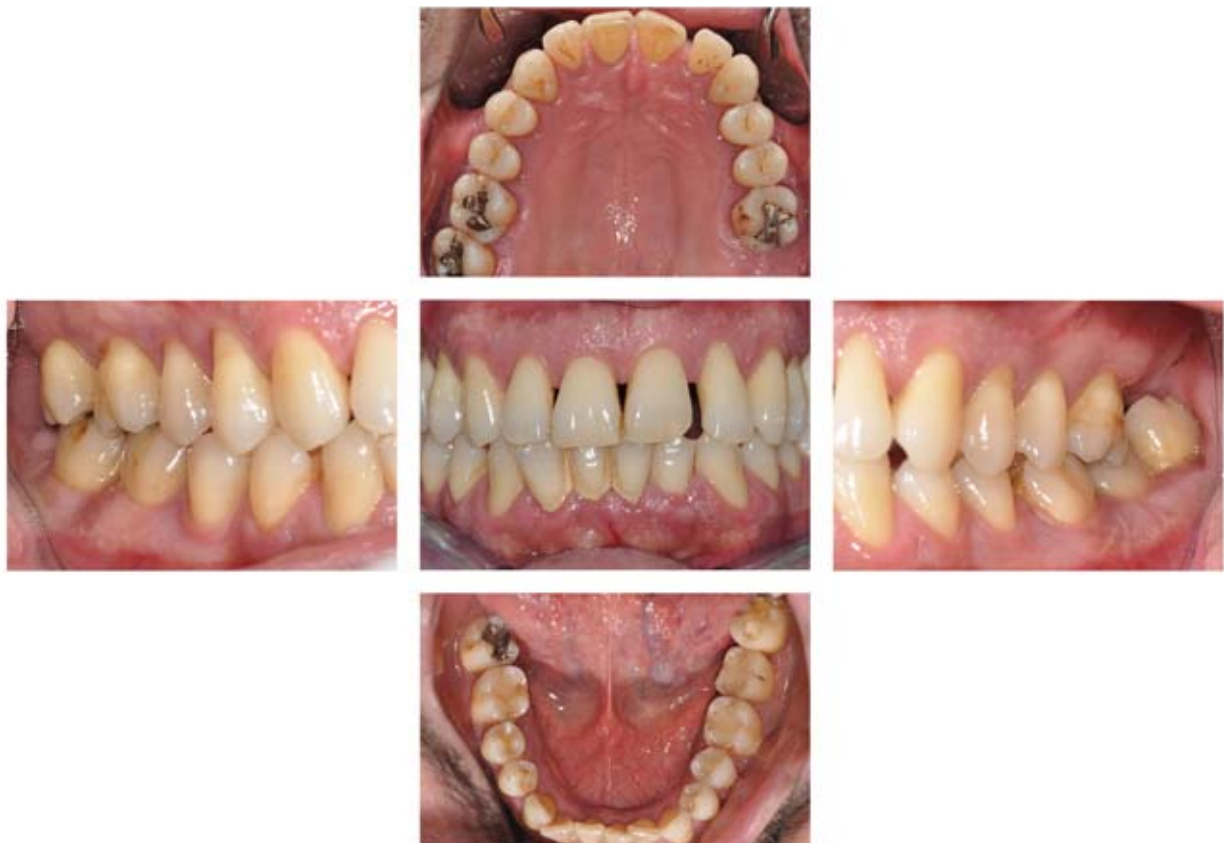

Figure 1 Photo status of the initial situation with localized hard and generalized soft biofilm and tooth tipping towards vestibular in the upper jaw anterior region (05/2017)

mum tooth preservation and elimination of oral pain and inflammation.

Findings

Extraoral findings

The extraoral findings were inconspicuous with the lips closed. When speaking, a pronounced foetor ex ore and a lisping was perceived by the practitioner.

Intraoral findings

The mucous membranes of the pharyngeal ring, the floor of the mouth, the tongue, the hard and soft palate, the cheeks and the lips showed no pathological findings. Generalized plaque as well as tartar and edematous swellings of the gingiva in the mandibular anterior region were present. In addition, generalized stains could be determined. There were 28 teeth present. Teeth 18, 27, 28 and 48 were missing. Teeth 17, 16, 26 and 47 were restored with direct amalgam restorations; teeth 37, 36, 35, 45 and 46 displayed direct composite restorations, which proved to be satisfactory on visual and tactile inspection. Little attrition, abrasion and erosion were found based to the patient's age. All teeth tested positive during sensitivity testing using cold

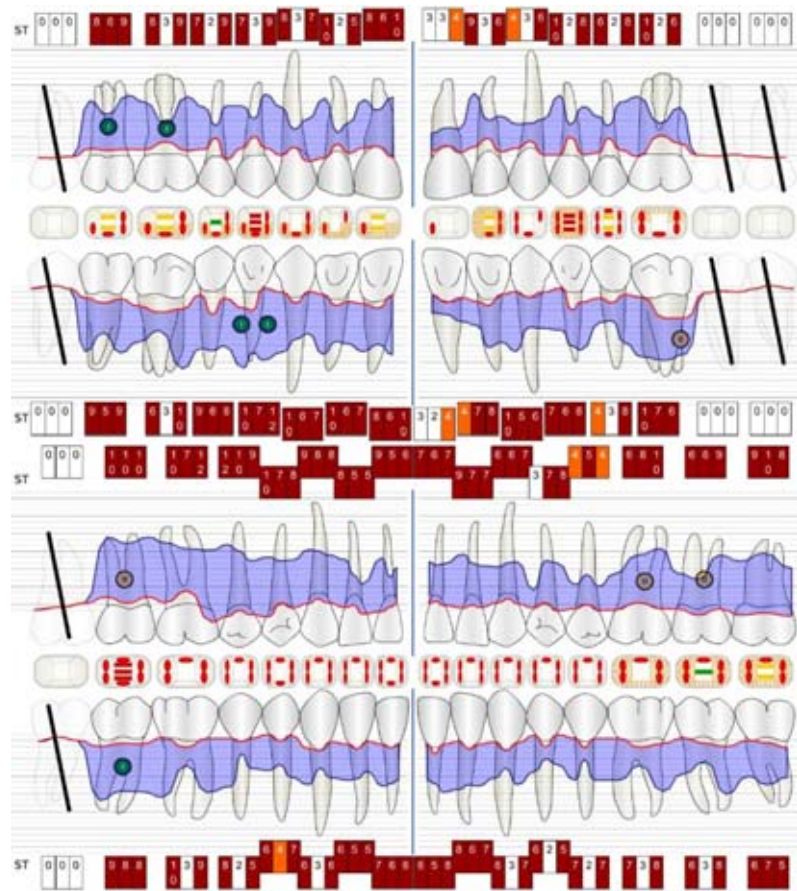


Figure 2 Initial findings with generalized probing pocket depths and attachment level ≥ 7 mm as well as generalized BOP and suppuration, mobility grade III and furcation involvement up to grade II (05/2017)

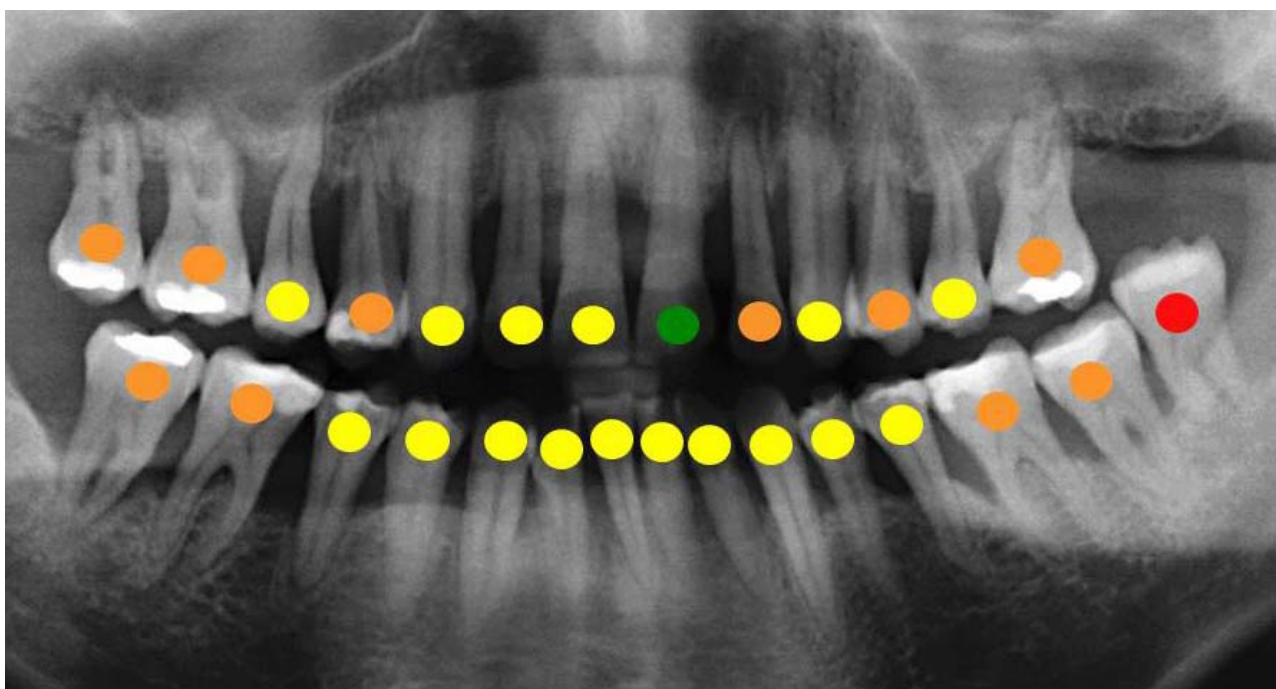


Figure 3 Panoramic X-ray (05/2017) with prognosis estimate (Kwok & Caton, 2007 [10]; prognosis gradation: green = favorable, yellow = questionable, orange = unfavorable, red = not possible)

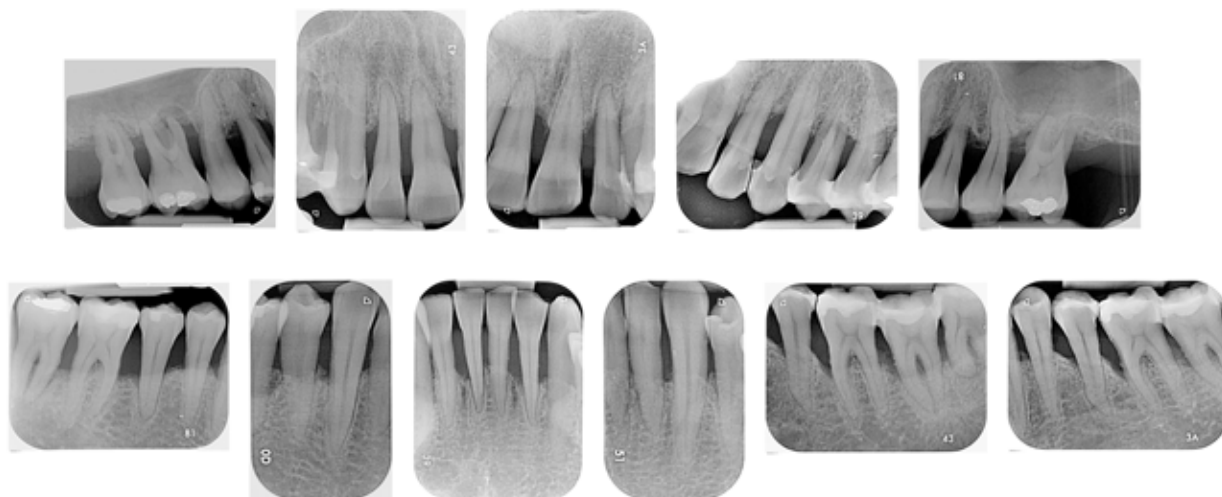


Figure 4 X-ray status with the generalized horizontal course of the alveolar ridge in the apical third of the root with apex involvement of teeth 17 and 16, furcation involvement and vertical defects (05/2017)

spray and the percussion test was negative (Fig. 1 and 2).

The probing pocket depths were 0–3 mm for 15 %, 4–6 mm for 32 % and ≥ 7 mm for 53 % of the sites. Teeth 16, 13, 12, 11, 23, 24, 26, 38, 36, 44, 46 and 47 displayed probing depths of up to 10 mm, while teeth 14

and 45 had probing depths up to 12 mm. The attachment level was 0–2 mm for 1 %, 3–4 mm for 13 % and ≥ 5 mm for 86 % of the sites. Bleeding on probing (BOP) was generalized and present for 74 % of the sites. After probing, pus discharge was observed around teeth 16–11, 22, 24,

26 and 38–36. Furcation involvement grade I and grade II was observed for teeth 17, 16 and 14 and teeth 26, 37, 36 and 47, respectively [8]. With regards to tooth mobility, teeth 15 and 37 displayed grade I, teeth 17, 16, 11, 22, 25 and 38 grade II, and teeth 14, 24 and 47 grade III.

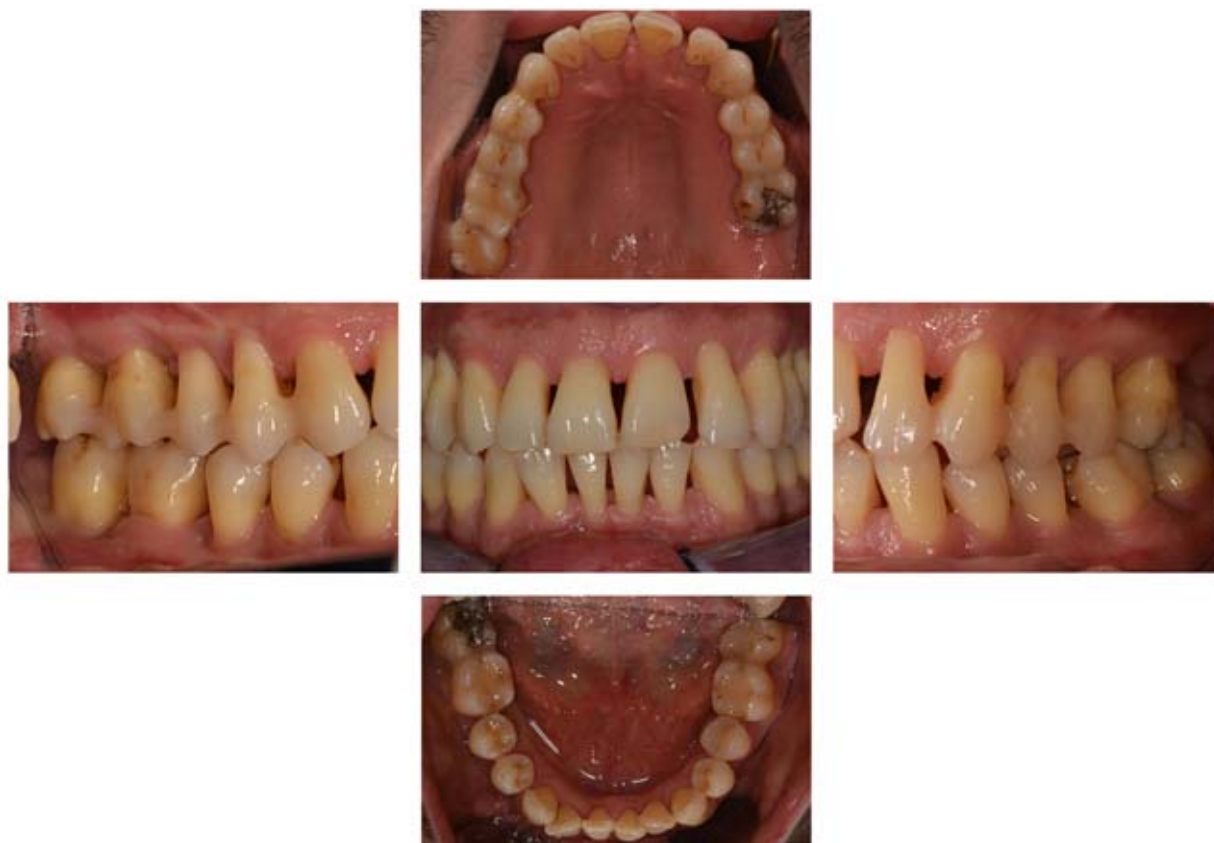

Figure 5 Photo status at SPT II with visible attachment losses and black triangles in the anterior region as well as existing direct splints (03/2018)

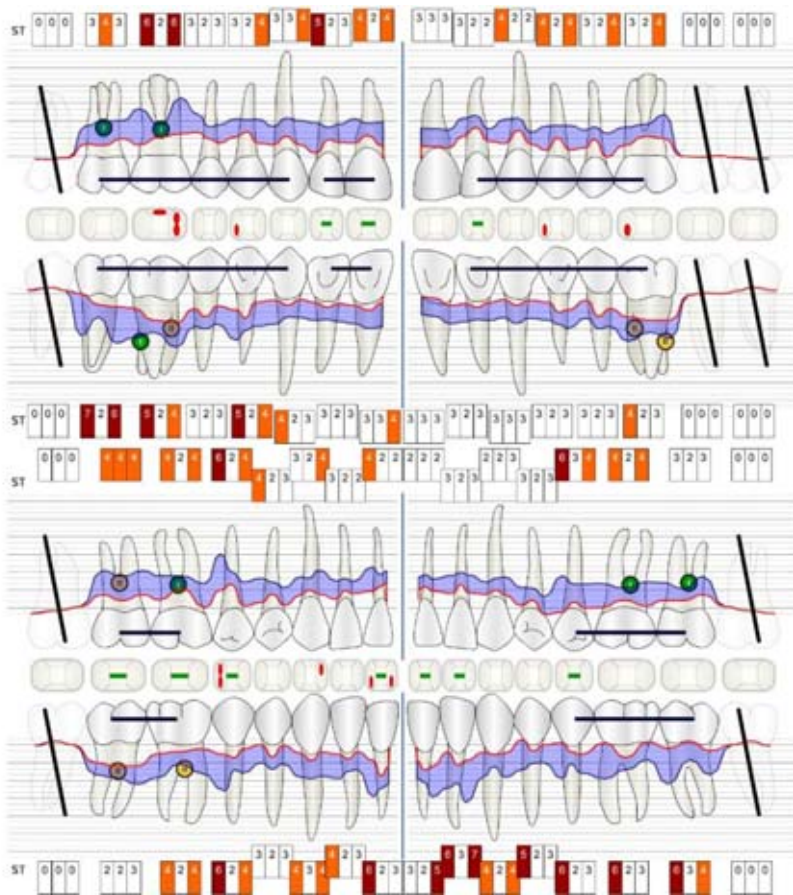


Figure 6 Findings at SPT II with generalized probing pocket depths ≤ 3 mm as well as localized BOP, mobility up to grade I and furcation involvement up to grade II (03/2018)

Radiological findings

In the panoramic X-ray image from 05/2017, the horizontal course of the alveolar ridge in the upper jaw was seen to be in the apical third of the root and in the lower jaw, in the middle to apical third of the root. Interradicular translucent areas that indicated furcation involvement were observed for the teeth 17, 16, 14, 24, 26, 38–36, 46 and 47. Periradicular translucencies extending to the radiological apex were observed on teeth 17, 16 and 26. The temporomandibular joints were symmetrical and the ventilation in the maxillary sinuses was equal as far as it could be assessed (Fig. 3).

In the X-ray status from 05/2017, additional periradicular translucencies were observed which indicated vertical bone defects around teeth 14, 24, 36 and 35. Periradicular translucencies corresponding to widened periodontal spaces were noticeable around teeth 22 and 45. Teeth 15–25 and 37–47 displayed no pathological findings at the root apices (Fig. 4).

Diagnosis

- Periodontitis stage IV, generalized, grade C with modifying risk factor smoking [13]
- Endo-periodontal lesions grade 3 on teeth 16 and 17 [13]
- Suspicion of endodontic lesions on teeth 26, 38 and 47
- Suspicion of occlusal trauma on teeth 22 and 45
- Unharmonious anterior situation (multiple recessions, anterior teeth tipping towards vestibular, protrusion of tooth 22)

Prognosis

A prognosis assessment according to Kwok & Caton, 2007 is shown in Figure 3 [9]. In this case, local factors such as attachment level, probing pocket depth, furcation involvement and tooth position were used for differentiation [9].

Therapy

Therapeutic plan

- Smoking cessation
- Endodontic treatment of teeth 16, 17 and 26
- Extraction of tooth 48
- Systematic periodontal therapy

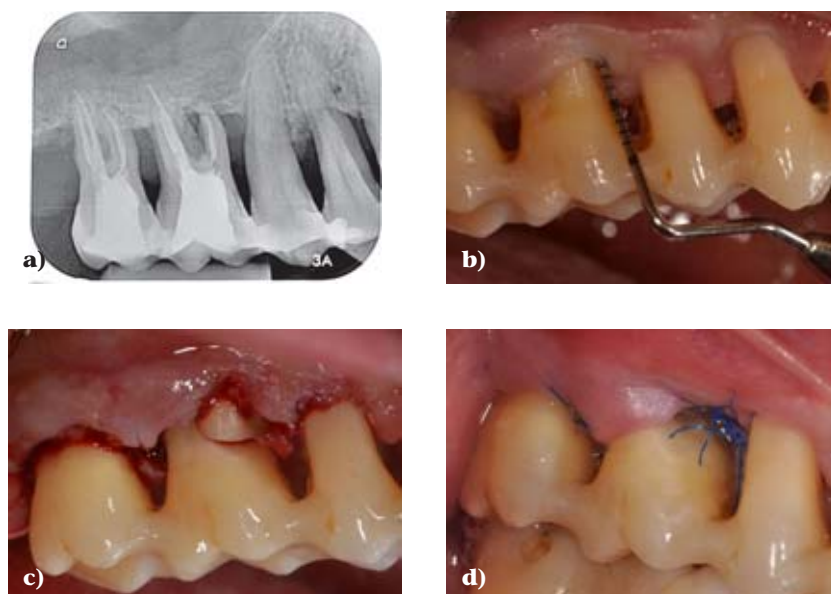


Figure 7a–d Resective periodontal surgery on teeth 17 to 15 with root amputation (mb) of tooth 16 and distal wedge excision on tooth 17 (a: endodontic therapy, b: pre-operatively, c: mesiobuccal root amputation, d: 1 week post-operatively)

- Direct composite splinting of all teeth with mobility grade \geq II
- Functional corrective measures on teeth 22 and 45
- Esthetic rehabilitation of the anterior teeth

Endodontic therapy

Teeth 17 and 16 were endodontically treated with mechanical instrumentation as part of the anti-infective therapy. The pre-surgical endodontic treatment of tooth 26 was performed after the anti-infective therapy. Before trepanation closure with composite, the root canal fillings were each shortened by about 3 mm from the canal entrance in order to guarantee separation of the roots in composite during the ensuing root amputation.

Anti-infective therapy

The patient could be convinced to stop smoking. During periodontal pre-treatment, he managed to become a non-smoker abruptly with the help of nicotine patches. The patient attended 3 oral hygiene sessions at intervals of approximately 2 weeks. In these sessions, intensive oral hygiene training with individualized interdental brushes (Curaprox CPS 14, LS 635G, LS 636, Curaden Germany GmbH, Stutensee, Germany), which were adapted

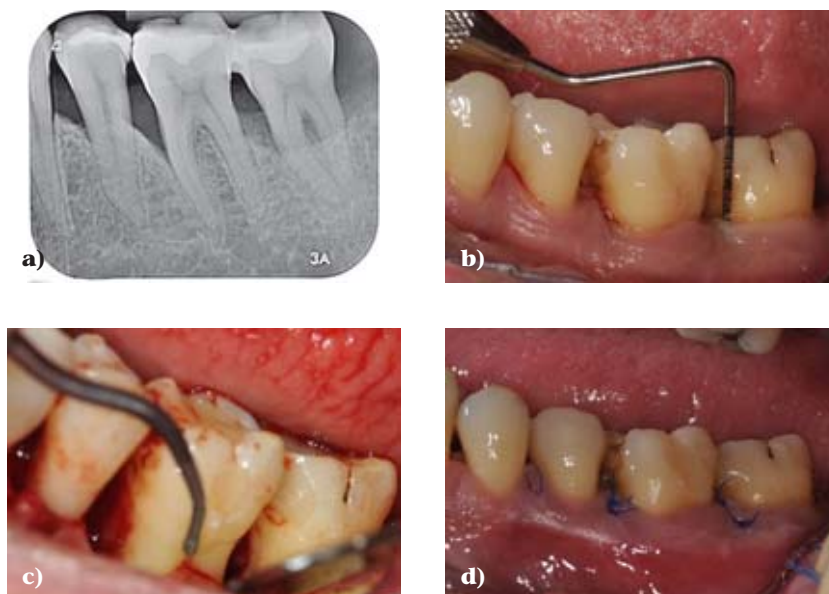


Figure 8a-d Periodontal surgery on teeth 37 to 34 with subtractive odontoplasty in the furcation area of tooth 36 (a: X-ray imaging of initial situation, b: pre-operatively, c: odontoplasty + distal root amputation, d: 1 week post-operatively)

to his interdental spaces, took place and the parameters Plaque Control Record (PCR according to O'Leary, 1972) and Gingival Bleeding Index (GBI according to Ainamo & Bay, 1975) were recorded [2, 12]. The GBI was between 1 % and 0 % in each case and the PCR could be improved from 61 % to 14 % over the course of the sessions. All teeth with a mobility grade \geq II were splinted directly with composite (teeth 17–13,

12–11, 22–27, 37–36 and 45–47). The functional contact relations of teeth 22 and 45 were corrected by selective reduction.

Subgingival scaling and root planning (SRP) was performed for each half of the mouth as part of a full-mouth disinfection (FMD) on 2 consecutive days [18]. Due to the endo-periodontal lesions and the recently performed root canal treatments, teeth 17 and 16 were only instrumented in the coronal third of the root in order to not endanger the endodontic regeneration potential of the apical root areas [16]. Tooth 48 was extracted during the FMD. Subsequent to SRP, chlorhexidine gel (1 %) was applied to the treated pockets. An adjuvant systemic antibiotic was prescribed – 375 mg amoxicillin and 250 mg metronidazole

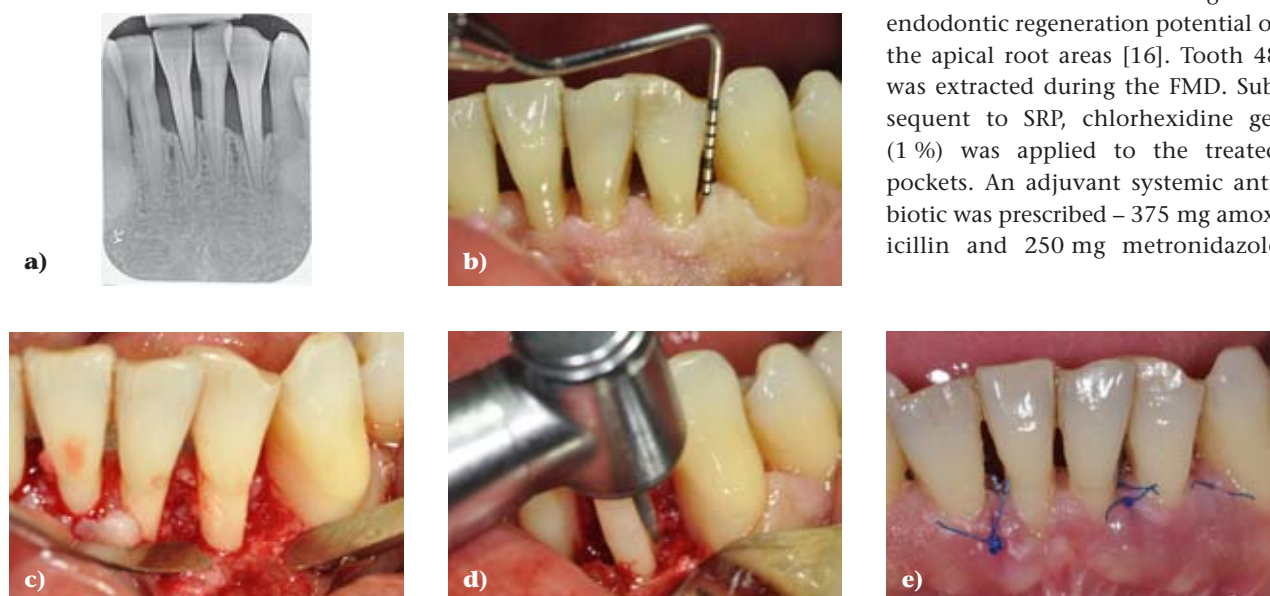


Figure 9a-e Periodontal surgery on teeth 33 to 31 with subtractive measures of root reduction on tooth 32 and periodontal surgery on teeth 41 to 42 (a: X-ray imaging of initial situation, b: pre-operatively, c: defect and root surface cleaned, d: odontoplasty, e: 1 week post-operatively)

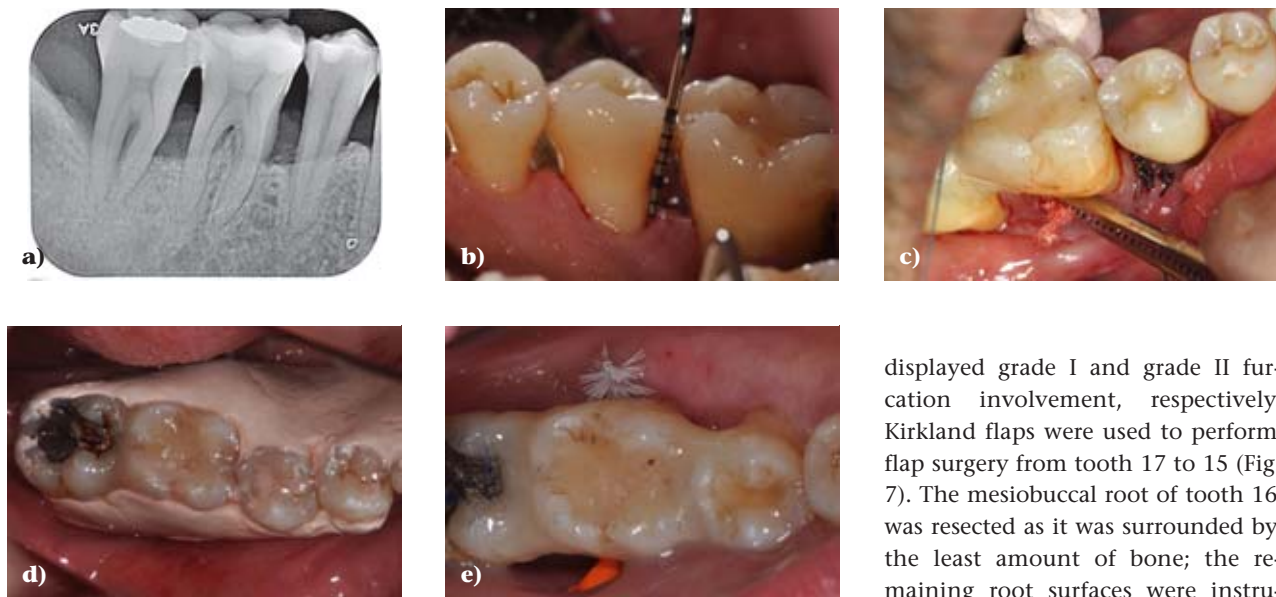


Figure 10a–e Periodontal surgery on teeth 44 to 47 with tunneling of the furcation of tooth 46 (**a**: X-ray imaging of initial situation, **b**: pre-operatively from lingual, **c**: tunneled furcation area traversed with gauze bands, **d**: gingival dressing, **e**: 1 week post-operatively with adapted interdental brushes in the furcation)

3 times daily for 7 days [1]. The patient was instructed to rinse the oral cavity twice daily with chlorhexidine mouthwash (0.2 %, alcohol-free) for the following 2 weeks and to brush the teeth with chlorhexidine gel (1 %) before using the interdental brushes. One week later, a follow-up examination was performed; the gingiva appeared inconspicuous and another subgingival instillation of chlorhexidine gel (1 %) was applied into the treated pockets. Another week later, a second follow-up examination was performed and the findings were again inconspicuous. The resulting chlorhexidine stains on the tooth surfaces were removed by polishing.

Reevaluation/supportive periodontal therapy (SPT I)

The patient came for re-evaluation/SPT I 3 months after SRP. Subjectively, he reported a perceived clear improvement in the periodontal situation with no recurrent inflammation or bleeding.

The probing pocket depths were 1–3 mm at 60 %, 4–6 mm at 36 % and ≥ 7 mm at 4 % of the sites. The attachment level was 0–2 mm at 4 %, 3–4 mm at 31 % and ≥ 5 mm at 64 % of the sites. Bleeding on Probing (BOP) was recorded for 12 % of

the sites. Grade I furcation involvement was present at teeth 17, 36 and 46, while grade II was observed at teeth 16, 26, 37 and 47. Teeth 12–22, 35, 32–42 and 45 exhibited grade I mobility. The mobility of teeth 22 and 35 resulted from fractures of the composite splints. These were repaired with composite during treatment. The sensitivity test using cold spray was negative on the endodontically treated teeth 17 and 16 and positive on all other teeth, while the percussion test was negative for all teeth. Supragingival and subgingival scaling of all recessed pockets ≥ 4 mm with BOP was performed. The root surfaces of teeth 17 and 16 were also instrumented to the bottom of the pockets at approximately 7 months after endodontic therapy. The periodontitis risk assessment modified according to Ramseier & Lang 1999 showed a high risk of periodontitis; thus, a 3-month SPT interval was recommended [15].

Corrective surgical therapy

Prior to corrective surgical therapy, SPT II (approximately 6 months after FMD) was awaited (Fig. 5 and 6).

Probing pocket depths of up to 6 mm at tooth 16 and 7 mm at tooth 17 were still present. Teeth 17 and 16

displayed grade I and grade II furcation involvement, respectively. Kirkland flaps were used to perform flap surgery from tooth 17 to 15 (Fig. 7). The mesiobuccal root of tooth 16 was resected as it was surrounded by the least amount of bone; the remaining root surfaces were instrumented under direct vision and the furcation entrance between the palatal and distobuccal roots was levelled by subtractive surgery. The tooth was reduced from functional occlusion to counteract extraaxial loading. A distal wedge excision was performed at tooth 17. The wound was closed with single button sutures (5–0 Prolene). Seven days later, the wound was checked and the sutures were removed. The patient was symptom-free and wound healing progressed concordantly.

Teeth 37–35 showed mesial probing pocket depths of up to 6 mm with grade I furcation involvement at teeth 37 and 36. A flap operation was performed using a Kirkland flap with subtractive odontoplasty of the furcation area on tooth 36 (Fig. 8). Wound closure was performed using 5–0 Prolene. The sutures were removed one week post-operatively.

Teeth 31 and 41 showed persistent, localized probing depths of up to 7 mm. A flap operation on tooth 32 using a Kirkland flap and subtractive root reduction measures ensued (Fig. 9). The sutures (5–0 Prolene) were removed one week post-operatively.

Tooth 45 still had a probing depth of up to 6 mm. Teeth 46 and 47 displayed furcation involvement up to grade II. A flap operation was performed at teeth 47 to 45. Schluger and Sugarman files for the tunneling (Hu-Friedy Mfg. Co., LLC., Frankfurt am Main, Germany) of the furcation of tooth 46 were used, while subtractive measures of the furcation area on

tooth 47 were performed (Fig. 10). After primary wound closure (4–0 Ethibond), a gum dressing was applied in the created tunnel and pericoronally. One week post-operatively, the gum dressing and sutures were removed and an interdental brush (Curaprox, CPS 14) was adjusted to fit in the tunnel for daily hygiene.

Tooth 26 showed furcation involvement up to grade II. A flap operation was performed with amputation of the two buccal roots of tooth 26 (Fig. 11). The wound was closed with 5–0 Prolene. In order to minimize extraaxial loading, the height and width of the tooth crown was reduced towards the buccal direction. One week post-operatively, wound healing progressed concordantly.

Esthetic and functional rehabilitation

Stable periodontal conditions were seen at SPT III. However, the patient was not definitively satisfied with the esthetic and functional consequences of his periodontal disease and its therapy. Subjectively, he was disturbed by the black triangles, the tooth tipping towards vestibular of the maxillary anterior teeth, and especially, the elongated, extruded and rotated tooth 22. Phonetic impairments existed in the form of lisping and the patient stated that he often spat while speaking. Although hypersensitivity was improved by local fluoridation measures, it was still noticeably present. Tooth 22 continued to display an interference contact during protrusive movements.

A wax-up was used to aid the patient in visualizing the intended result of the treatment and a silicone key was made from it. While being kept relatively dry, the enamel of teeth 14–24 and 34–44 was sandblasted with aluminum oxide powder, etched, and then primer and adhesive (Optibond FL) were applied and light-cured. Using the individualized direct veneering technique, the tooth shape and position were corrected with composite (Tetric Evo Ceram, Dentin & Enamel, A3 & A2). In this way, the existing rotations, protrusions and elongations were compensated and the gaps were completely closed. Tooth 22 was reduced

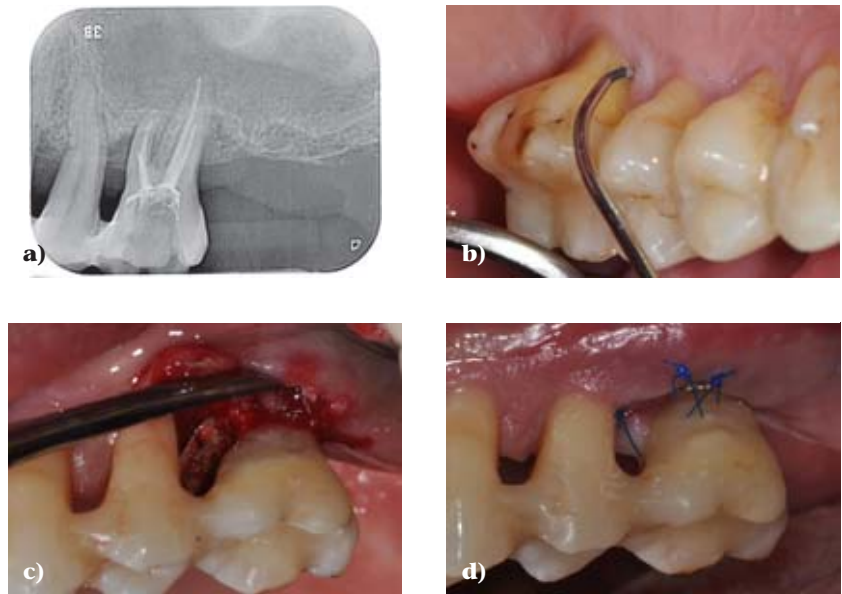


Figure 11a–d Resective periodontal surgery on teeth 25 to 26 with root amputation (mb + db) of tooth 26 (a: endodontic therapy, b: pre-operatively, c: mesio Buccal and distobuccal root amputation, d: 1 week post-operatively)

to such an extent that the functional interference contact was eliminated. The final tooth shape adjustments and high-gloss polishing took place in a second appointment. First, macrostructures were integrated by vertical indentations of the labial surfaces and the transitions of the proximal areas were designed with Soflex discs. Subsequently, the high-gloss polishing was carried out using silicone polishers and precisely fitting interdental brushes (Fig. 12 and 13) were selected.

Supportive periodontal therapy

The patient appeared regularly for SPT. Every 3 months he received a professional teeth cleaning and oral hygiene instructions. The GBI was 0 % and the PCR ranged between 15 and 44 %. Every 6 months a dental examination was performed; the periodontal status was determined and subsequent subgingival instrumentation of sites where increased probing pocket depths existed was carried out. The patient reported having the feeling of a stable absence of inflammation during the SPT. However, during the SPT phase, he started smoking again (approximately 10 cigarettes/day) and attributed this to increased stress levels and a supposedly stable oral health.

In SPT III, the probing depths were 1–3 mm at 88 % and 4–5 mm at 12 % of the sites, respectively. BOP was present at 6 % of the sites.

At SPT IV in 07/2019, the probing depths were 1–3 mm at 94 % and 4 mm at 6 % of the sites (Fig. 14 and 15). The attachment level was 0–2 mm at 15 %, 3–4 mm at 42 % and ≥ 5 mm at 43 % of the sites. BOP was observed at 9 % of the sites. Tooth 46 showed grade III furcation involvement with functional home-based hygiene. Teeth 17, 16, 14, 24, 37 and 36 continued to show grade I furcation involvement. Teeth 12, 11, 22 and 32–41 exhibited grade I mobility. The sensitivity test using cold spray was negative on the endodontically treated teeth 17, 16 and 26, but positive on all other teeth, while the percussion test was negative on all teeth. Due to the enlarged interdental spaces in the posterior region and reduced interdental spaces in the anterior region, the interdental brushes also had to be adapted based on their corresponding PHD values (PHD = passage hole diameter) (Curaprox CPS 12, 15; TePe grey, black, TePe D-A-CH GmbH, Hamburg, Germany). The periodontitis risk assessment modified according to Ramseier & Lang, 1999 indicated a medium periodontitis risk. Thus, a 6-month SPT interval was recommended (Fig. 16) [15].

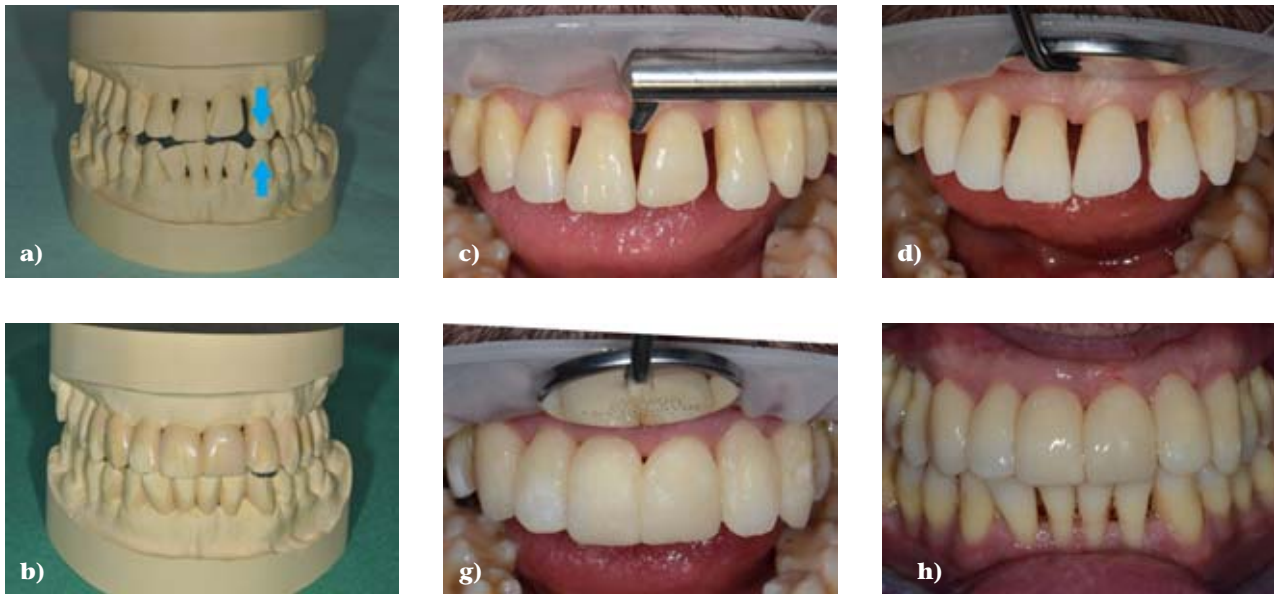


Figure 12a-j Shape corrections of teeth 14–24 and 34–44 (a: functional interference contact on tooth 12, b: wax-up, c + d: teeth sandblasted, e: incisal silicone stop, f: edge build-up, g: composite layering, h + i: composite finishing, j: polishing)

Epicrisis

The initial diagnosis was based on the masticatory dysfunction due to the existing tooth mobility \geq grade II and tooth tipping towards vestibular in the upper front area [13]. Since the attachment level at more than 30 % of the teeth was \geq 5 mm approximately, a generalized extent was observed [13]. As the primary criterion for determining the grading, the bone resorption index could be calculated as indirect evidence [13]. This was $>$ 1.00 (tooth 16: 100 % bone resorption/45 years of age), so that a

rapid rate of progression (grade C) could be assumed [13]. In addition, initial smoking \geq 10 cigarettes/day constituted a modifying factor for the classification as grade C [13].

Diagnosis of grade III endo-periodontal lesions was based on the presence of deep periodontal pockets on more than one side of each tooth [13]. The appraisal of teeth 26, 38 and 47 was in this respect more critical. Although the advanced periradicular bone loss as seen in the X-ray was indicative of an endo-periodontal lesion, the teeth reacted posi-

tively to sensitivity testing and did not show any signs of pulpitis.

The decision to use adjuvant antibiotics was made in accordance with the current S3 guideline of the DG PARO/DGZMK [1]. Since the probing pocket depths at over 35 % of the measured sites were \geq 5 mm and the patient was \leq 55 years old, it was possible to prescribe systemic antibiotics [1]. The selection and dosage chosen here corresponds to the original recommendation for the „Van Winkelhoff cocktail“. The current S3 guideline specifies a dosage of 500 mg amoxicillin and 400 mg metronidazole [1].

By preserving the teeth, including the ones with an unfavorable prognosis, the patient could achieve a state of periodontal stability. Figure 17 shows the changes in probing pocket depth and attachment level at SPT IV compared to the initial situation.

As an alternative treatment, the planning of a removable denture would have been possible. Due to the generally advanced loss of attachment and the questionable value of the abutment teeth, this may have possibly implied the complete extraction of teeth in the upper jaw. Individual periodontally compromised teeth could have been retained in situ during the fabrication of a cover denture. The patient declined this treatment option due to his young

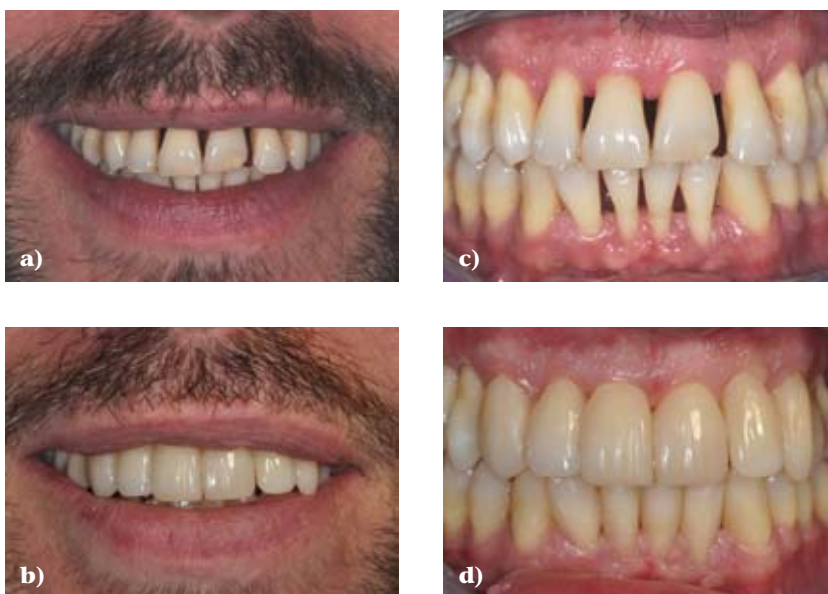

Figure 13a-d Anterior esthetics before (a, b) and after shape corrections (c, d)

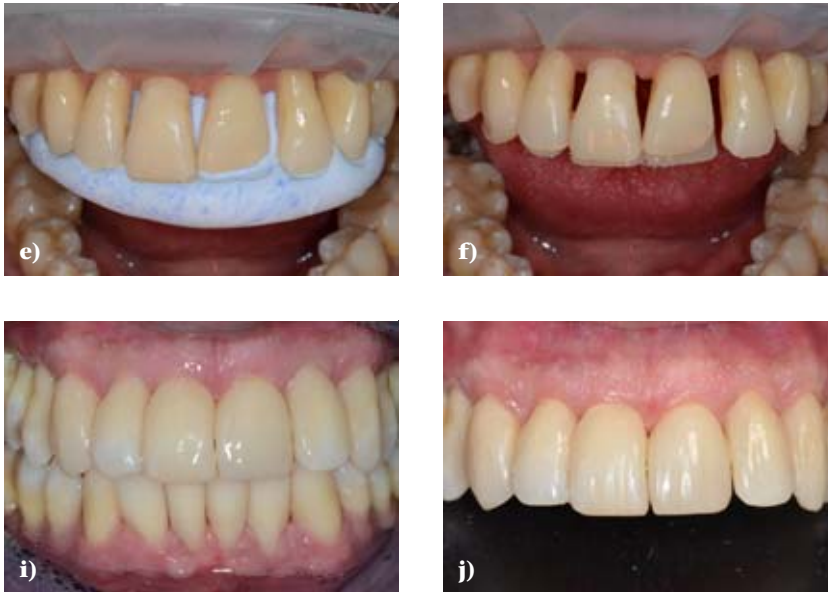

Figure 12a-j Shape corrections of teeth 14–24 and 34–44 (a: functional interference contact on tooth 12, b: wax-up, c + d: teeth sandblasted, e: incisal silicone stop, f: edge build-up, g: composite layering, h + i: composite finishing, j: polishing)

age and the desire to preserve his teeth and be treated with a fixed restoration.

The prognosis for the success of resected molars is well documented

[3–6]. In a dental office setting, Fugazzotto showed a cumulative success rate over 15 years of 96.8 % for resected molars compared to 97 % for implants in the molar region [6].

According to Alassadi et al., the main reasons for the possible extraction of a resected molar are fractures (39.5 %), caries (26.3 %) and periodontal causes (23.7 %) [3].

The patient’s compliance during SPT and the adequate home-based hygiene were the basis for why the tunneling of the resected maxillary molars could be achieved successfully [11, 17]. Regular fluoridation of the furcation areas should also be carried out in the future in order to prevent caries occurrence on the exposed root surfaces where the caries risk is high [10].

The patient’s desire for esthetics in the anterior region could be fulfilled by means of form corrections. In a study conducted in more centers, the functional and overall survival rates of shape corrections were over 98.5 % after 10 years and 77.6 % after 15 years [19]. Chipping fractures were identified as the most frequent adverse occurrences [19]. The periodontal parameters (probing pocket depth, attachment level, bleeding index) were also stable after a mean follow-up period of 15.5 years

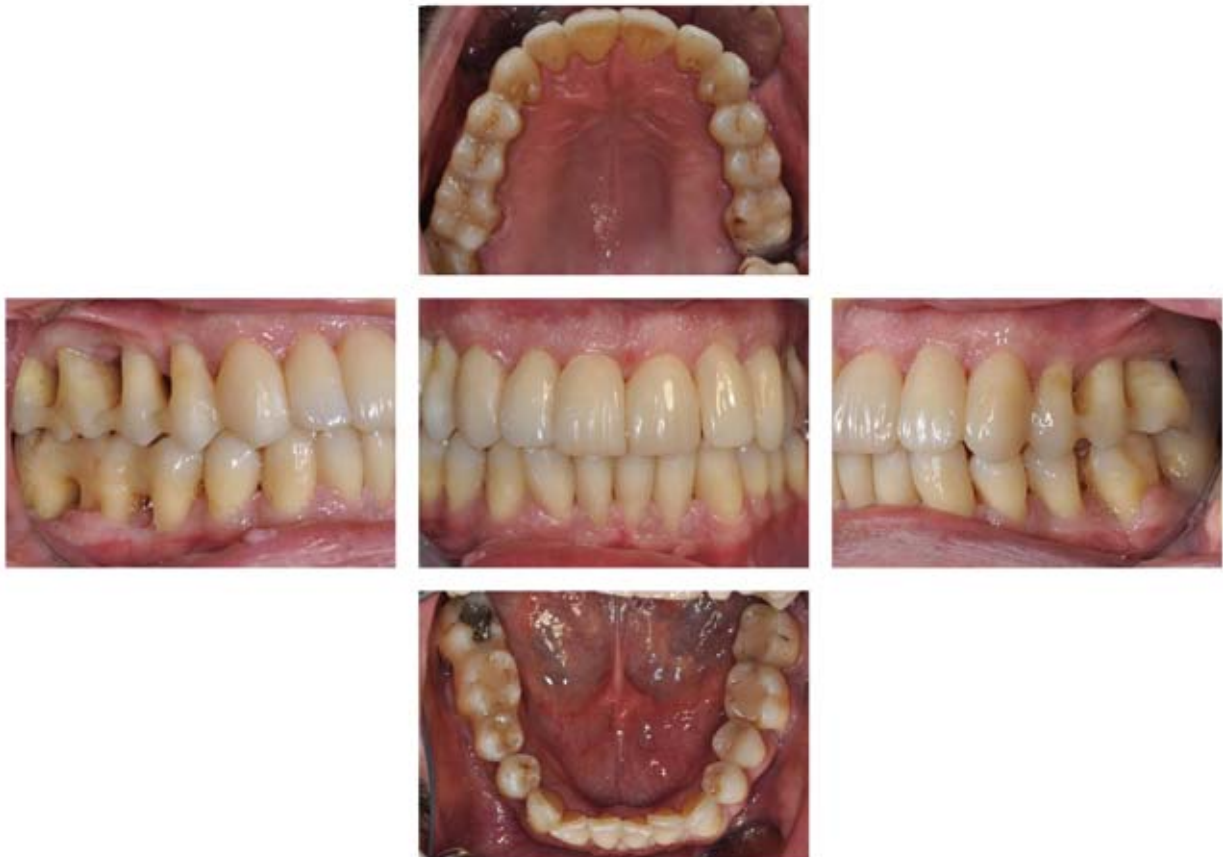

Figure 14 Photo status, mostly inflammation-free with existing form corrections of teeth 14–24 and 34–44 (07/2019)

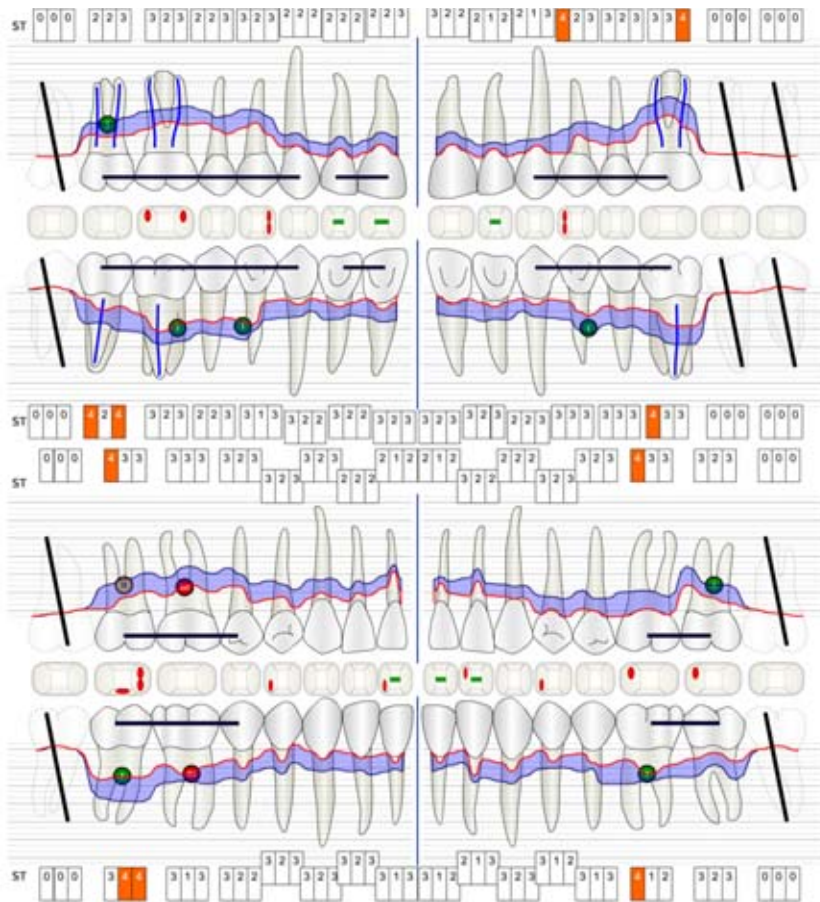


Figure 15 Findings of SPT IV with generalized probing pocket depths ≤ 3 mm as well as localized BOP, mobility up to grade I and furcation involvement up to grade III (07/2019)

and they showed no statistically significant differences compared to examinations on defined control teeth [7]. However, due to increased biofilm adhesion on aged composite material, the plaque index was slightly higher than on the natural control teeth [7].

To objectify and evaluate the success of the treatment, this patient case was evaluated according to the SSO Quality Guidelines. The results are predominantly class A [14].

Conclusion

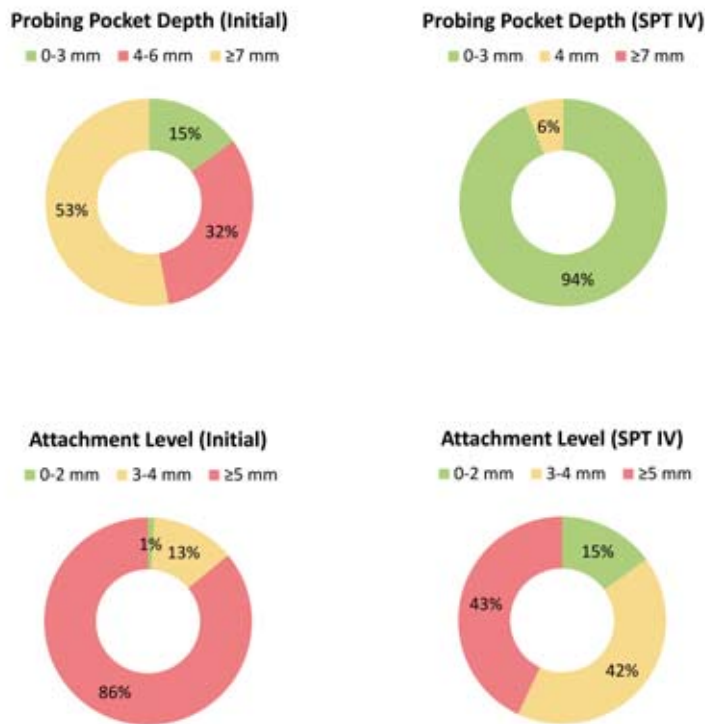
Patients with severe periodontal diseases can be rehabilitated after successful periodontal therapy by means of functional corrections and direct restorative techniques with composite. In this way, tooth substance is preserved, and to a large extent, esthetic and functional demands can be successfully fulfilled.

Conflicts of Interest

Parts of this case documentation were presented at the annual conference of the German Society of Periodontology in 2019 and a poster

	Low risk		Moderate risk		High risk	
1. Bleeding on Probing (BOP) in %	≤ 4	5–9	10–16	17–25	25–35	≥ 36
2. Number of sites with probing pocket depths of ≥ 5 mm	≤ 2	4	6	8	9	≥ 10
3. Number of teeth lost (without wisdom teeth)	≤ 2	4	6	8	9	≥ 10
4. Bone loss (Index)	$\leq 0,25$	0,26–0,5	0,51–0,75	0,76–1,0	1,1–1,24	$\geq 1,25$
5. Cigarette consumption	Non-smoker	Former smoker	≤ 10 /day	10–19/day	≥ 20 /day	
Preliminary risk assessment →	Low risk		Moderate risk		High risk	
6. Systemic/genetic factors: – Diabetes mellitus, – HIV-infection, – gingivo-periodontal manifestation of systemic diseases, – Interleukin-1 β -polymorphism	Factor not present		Factor not recorded		Factor present	
Final risk assessment →	Low risk 1 SPT/year		Moderate risk 2 SPT/year		High risk 3–4 SPT/year	

Figure 16 Periodontitis risk assessment 07/2019 (modified according to [15])



(Fig. 1–17: A. Ciardo)

Figure 17 Comparison of periodontal parameters: Initial situation (05/2017) – SPT IV (07/2019)

award was received. Dr. Antonio Ciardo is sponsored by the Medical Faculty of Heidelberg as part of the Physician Scientist Program. The other authors declare that there is no conflict of interest within the meaning of the guidelines of the International Committee of Medical Journal Editors.

References

1. Adjuvante systemische Antibiotikagabe bei subgingivaler Instrumentierung im Rahmen der systematischen Parodontitistherapie (S3). 2018, AWMF online: DG PARO, DGZMK
2. Ainamo J, Bay I: Problems and proposals for recording gingivitis and plaque. *Int Dent J* 1975; 25: 229–235
3. Alassadi M, Qazi M, Ravida A, Siqueira R, Garaicoa-Pazmino C, Wang HL: Outcomes of root resection therapy up to 16.8 years: A retrospective study in an academic setting. *J Periodontol* 2019
4. Carnevale G, Pontoriero R, di Febo G: Long-term effects of root-resective therapy in furcation-involved molars. A 10-year longitudinal study. *J Clin Periodontol* 1998; 25: 209–214
5. Derks H, Westheide D, Pfefferle T, Eickholz P, Dannewitz B: Retention of molars after root-resective therapy: a retrospective evaluation of up to 30 years. *Clin Oral Investig* 2018; 22: 1327–1335
6. Fugazzotto PA: A comparison of the success of root resected molars and molar position implants in function in a private practice: results of up to 15-plus years. *J Periodontol* 2001; 72: 1113–1123
7. Hahn B, Wohlrab T, Frese C et al.: Zahnformkorrekturen mit Kompositmaterialien (FOKOS) – eine multizentrische Anwendungsbeobachtung. Teil 2: Parodontale Gesundheit. *Dtsch Zahnärztl Z* 2019; 74: D9–D10
8. Hamp SE, Nyman S, Lindhe J: Periodontal treatment of multirrooted teeth. Results after 5 years. *J Clin Periodontol* 1975; 2: 126–135
9. Kwok V, Caton JG: Commentary: prognosis revisited: a system for assigning periodontal prognosis. *J Periodontol* 2007; 78: 2063–2071
10. Marinho VC, Worthington HV, Walsh T, Chong LY: Fluoride gels for preventing dental caries in children and adolescents. *Cochrane Database Syst Rev* 2015; Cd002280
11. Nibali L, Akcali A, Rudiger SG: The importance of supportive periodontal therapy for molars treated with furcation tunnelling. *J Clin Periodontol* 2019; 46: 1228–1235
12. O’Leary TJ, Drake RB, Naylor JE: The plaque control record. *J Periodontol* 1972; 43: 38
13. Papapanou PN, Sanz M, Buduneli N et al.: Periodontitis: consensus report of workgroup 2 of the 2017 World Workshop on the classification of periodontal and peri-implant diseases and conditions. *J Periodontol* 2018; 89 (Suppl 1): S173–s182
14. Qualitätsleitlinien Parodontologie (Fassung 2014). *Swiss Dental Journal* 2014; 124: 261–267
15. Ramseier C, Lang NP: Die Parodontalbetreuung. Ein Lernprogramm zur Qualitätssicherung in der Parodontologie (CD-ROM). Quintessenz Verlag, Berlin 1999
16. Rotstein IS, James H: The endo-periodontal lesion: a critical appraisal of the disease condition. *Endodontic Topics* 2006; 13: 34–56
17. Rudiger SG, Dahlen G, Emilson CG: The furcation tunnel preparation – a prospective 5-year follow-up study. *J Clin Periodontol* 2019; 46: 659–668
18. Saxer CM, Quirynen M, Saxer UP: Therapiekonzept „Full-Mouth-Disinfection“*. *Parodontologie* 2007; 18: 331–349
19. Wohlrab T, Frese C, Soliman S et al.: Zahnformkorrekturen mit Kompositmaterialien (FOKOS) – eine multizentrische Anwendungsbeobachtung. Teil 1: Überleben + Versagensanalyse. *Dtsch Zahnärztl Z* 2019; 74: D9



(Photo: Antonio Ciardo)

DR. MED. DENT. ANTONIO CIARDO
 Section of Periodontology,
 Department of Conservative
 Dentistry, Clinic for Oral, Dental and
 Maxillofacial Diseases,
 University Hospital Heidelberg
 Im Neuenheimer Feld 400,
 69120 Heidelberg
 antonio.ciardo@med.uni-heidelberg.de