

A Case of Primary Lymphoepithelial Carcinoma in the Palate

Juan Hong MENG¹, Wei ZHANG¹, Nian Hui CUI¹, Hai Yan LUO², Xu Chen MA³,
Deng Gao LIU³

Lymphoepithelial carcinoma (LEC) is an undifferentiated tumour that is associated with a dense lymphoid stroma. An exceptionally high incidence of this tumour is found in the Inuit populations and Asians^{1,2}. This neoplasm has been associated with Epstein-Barr virus (EBV) infection^{2,3}. LECs of salivary glands represent rare epithelial malignancies. They have been reported rarely in the minor salivary glands, particularly in the palate. This case report describes a primary LEC arising from the palate, which may come from the minor salivary gland.

Case Report

A 74-year-old Chinese woman presented to Peking University School and Hospital of Stomatology with the chief complaint of a mucosal ulceration in the palate, which had been present for one year. The ulceration was a little painful, and had initially grown slowly, but had grown very quickly in the previous month. She had taken antibiotics, with no change in her symptoms. She had worn complete dentures for a few years. She reported no associated fever, rhinostegnosis or rhinorrhagia, but she had a history of tuberculosis, with a node in the neck 2 years previously, which had been resected and verified by a biopsy, followed by anti-tuberculosis treatment for

6 months. Two biopsies on the mucosal ulceration were made 8 months and 4 months previously respectively, and were described histologically as 'oral ulceration' by the local hospital.

Physical examination revealed a large, deep, red, mucosal ulceration in the posterior hard palate to hard-soft palate junction, which was approximately 2.5 x 2.5 cm, clean, mulberry-like, fleshy, with a non-flat floor and firm, protuberant borders surrounding the ulcer (Fig 1). It was firm and painful on palpation. She was edentulous. No evidence of other mucosal abnormality or enlargement of cervical lymph nodes was present. There was no positive evidence of chest x-rays.

Cone Beam CT (NewTom, QRDVT-9000, Italy) scanning revealed a lesion in the left side of the hard palate with focal bony destruction (Fig 2). A purified protein derivative (PPD) test was negative. The results of physical examination of the nose, nasopharynx and larynx indicated no mucosal abnormalities and the nasopharyngeal biopsy was negative. An incisional biopsy of the ulceration was carried out and the result of histopathological analysis indicated a LEC. Under light microscopy, tumour islands were infiltrated by abundant lymphoid tissues, and carcinoma cells were mixed with many small lymphocytes. The epithelial layer remained intact. Indistinct cell borders, vesicular nuclei and prominent nucleoli were found in carcinoma cells (Fig 3). A combination of surgical resection and adjuvant radiotherapy was suggested to the patient, but she insisted on returning to her local hospital for treatment.

Discussion

LEC, once known as undifferentiated carcinoma with lymphoid stroma and carcinoma ex lymphoepithelial lesion, is an undifferentiated tumour that is associated with

¹Department of Oral and Maxillofacial Surgery,

²Department of Oral Pathology,

³Department of Oral Radiology, Peking University School and Hospital of Stomatology, Beijing, P.R. China.

Corresponding author: Dr. Wei ZHANG, Department of Oral and Maxillofacial Surgery, Peking University School and Hospital of Stomatology, #22 ZhongGuanCun South St., Beijing 100081, P.R. China. E-mail: kqzhangwei@hsc.pku.edu.cn

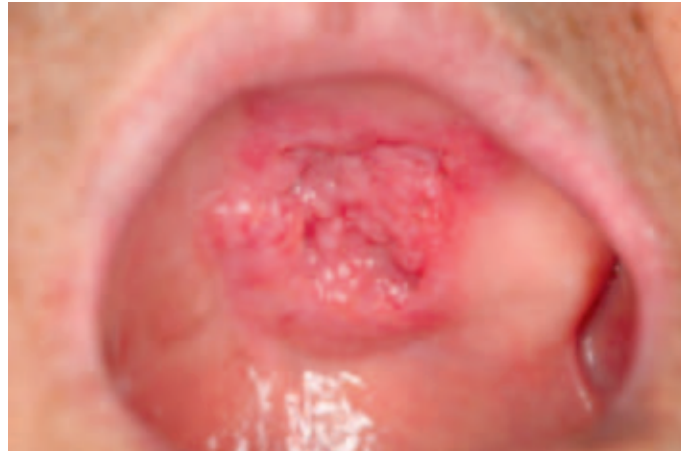

Fig 1 A large, deep, red, mucosal ulceration was present in the posterior hard palate at the junction of hard-soft palate.

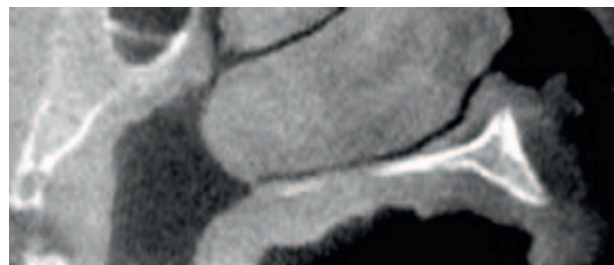
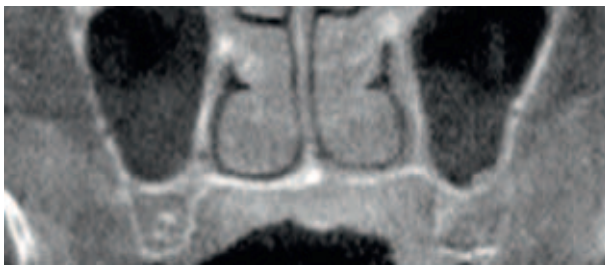

Fig 2 A Cone Beam CT scanning revealed a lesion in left side of hard palate with focal bony destruction. A) Coronal plane. B) Sagittal plane

a dense lymphoid stroma^{1,4,5}. Undifferentiated carcinomas of salivary glands are a group of uncommon malignant epithelial neoplasms that lack the specific light-microscopic morphological features of other types of salivary gland carcinomas. These carcinomas are similar histologically to undifferentiated carcinomas that arise in other organs and tissues. According to the 1991 World Health Organization (WHO) classification of salivary gland tumours, LEC is classified as undifferentiated carcinoma of the salivary gland. As a variant of undifferentiated carcinoma, it is distinguished from small cell and large cell undifferentiated carcinoma by its association with benign lymphoepithelial lesions^{2,3}. But according to the 2005 WHO classification, LEC is de-

finied as an independent classification of salivary gland tumours⁶.

Of the reported occurrences, 80% of LEC in salivary gland are in the parotid glands, followed by the submandibular glands⁷. In addition to the presence of a parotid or submandibular mass, pain is a frequent symptom, and facial nerve palsy occurs in approximately 20% of patients. Of the patients, > 40% have metastases to cervical lymph nodes at initial presentation, 20% develop local recurrences or lymph node metastases, and 20% develop distant metastases, which tend to occur in the lung, liver, bone and brain^{8,9}. A 5-year survival rate of 75–86% has been reported in patients treated by combined surgery (including neck dissection) and radiation

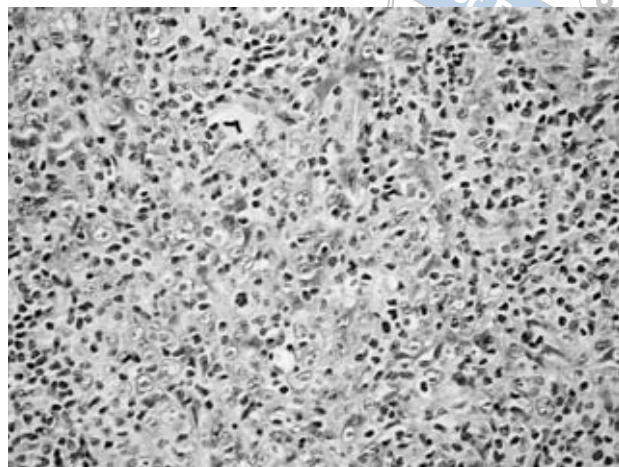
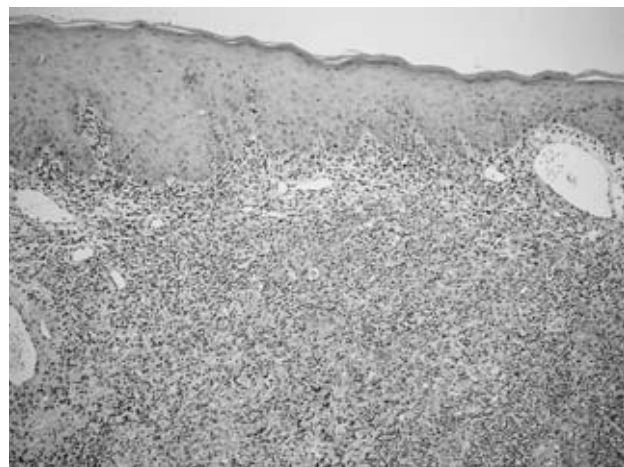


Fig 3 Light microscopy of lymphoepithelial carcinoma of minor salivary gland. A) Carcinoma cells are mixed with many small lymphocytes. Tumour islands are infiltrated by abundant lymphoid tissues. Epithelial layer is intact. B) Indistinct cell borders, vesicular nuclei and prominent nucleoli are found in carcinoma cells.

therapy^{2,8}. Many results indicated that EBV infection and certain geographic factors play important roles in the pathogenesis of the salivary LEC¹⁻³.

Histologically, tumours in the minor salivary glands include pleomorphic adenoma, adenoid cystic carcinoma, mucoepidermoid carcinoma, acinic cell carcinoma and adenocarcinoma. They are characterised by a higher incidence of palatal involvement^{10,11}. Wang et al¹¹ reported 60 cases of carcinoma of minor salivary gland in the palate; the occurrence of the tumours in descending order was mucoepidermoid carcinoma, adenoid cystic carcinoma, malignant pleomorphic adenoma, adenocarcinoma and acinic cell carcinoma. However, due to the fact that most cases affect the parotid gland, LEC has rarely been reported in the minor salivary glands in the literature. Two cases described the buccal area as the primary sites¹²⁻¹⁴. In the present study, we report a LEC which may have developed in the minor salivary glands of the palate of a 74-year-old woman.

LEC is very similar to nasopharynx carcinoma (NPC), which is also related to EBV infection. So an important differential diagnosis is NPC, and a complete examination should be done to exclude NPC³. In the present case, the examination of the nose, nasopharynx and larynx indicated no mucosal abnormalities. Clinically, another differential diagnosis is midline malignant reticulosis (MMR), the symptoms most commonly being swelling, ulceration and necrosis in the midline of palate, accompanied by a perforation of the palate. A necrotising infiltration of atypical lymphoid cells mixed with in-

flammatory cells was confirmed as the histopathological feature of MMR¹⁵. It is also difficult to differentiate LEC from other neoplasms that present as an ulceration, including mucoepidermoid carcinoma, adenoid cystic carcinoma, acinic cell carcinoma, and adenocarcinoma. Light microscopy is helpful to arrive at the final diagnosis.

Since LEC is so rare, when cases present they are easily misdiagnosed. A continuous ulceration with a history of tuberculosis node led to a first impression of tuberculosis ulceration. Inappropriate biopsy sites and lack of knowledge of this tumour could lead to delays in diagnosis. Any lesion arising from the hard palate should be considered as a possible minor salivary gland tumour¹⁶. Accordingly, avoiding a misdiagnosis is a primary concern in the diagnosis of these neoplasms, especially in small salivary gland.

References

1. Hamilton-Dutoit SJ, Therkildsen MH, Neilsen NH, Jensen H, Hansen JP, Pallesen G. Undifferentiated carcinoma of the salivary gland in Greenlandic Eskimos: demonstration of Epstein-Barr virus DNA by in situ nucleic acid hybridization. *Hum Pathol* 1991;22:811-815.
2. Leung SY, Chung LP, Yuen ST, Ho CM, Wong MP, Chan SY. Lymphoepithelial carcinoma of the salivary gland: in situ detection of Epstein-Barr virus. *J Clin Pathol* 1995;48:1022-1027.
3. Chan JK, Yip TT, Tsang WY, Poon YF, Wong CS, Ma VW. Specific association of Epstein-Barr virus with lymphoepithelial carcinoma among tumors and tumorlike lesions of the salivary gland. *Arch Pathol Lab Med* 1994;118:994-997.

4. Batsakis JG. Pathology Consultation. Carcinoma ex lymphoepithelial lesion. *Ann Otol Rhinol Laryngol* 1983;92:657-658.
5. Cleary KR, Batsakis JG. Undifferentiated carcinoma with lymphoid stroma of the major salivary glands. *Ann Otol Rhinol Laryngol* 1990;99:236-238.
6. Leon Barnes, John W Eveson, Peter Reichart, David Sidransky. WHO Pathology and Genetics in Head and Neck Tumours. IARC Press Lyon, France, 2005.
7. Ellis GL, Auclair PL. Tumors of the Salivary Glands. Atlas of Tumor Pathology. 3rd series. Washington, DC: Armed Forces Institute of Pathology, 1996.
8. Borg MF, Benjamin CS, Morton RP, Llewellyn HR. Malignant lympho-epithelial lesion of the salivary gland: a case report and review of the literature. *Australas Radiol* 1993;37:288-291.
9. Saw D, Lau WH, Ho JH, Chan JK, Ng CS. Malignant lymphoepithelial lesion of the salivary gland. *Hum Pathol* 1986;17:914-923.
10. Toida M, Shimokawa K, Makita H, Kato K, Kobayashi A, Kusunoki Y et al. Intraoral minor salivary gland tumors: a clinicopathological study of 82 cases. *Int J Oral Maxillofac Surg* 2005;34:528-532.
11. Wang ZY, Ye BF, Xu MY. Carcinoma of minor salivary glands in the palate: a clinical analysis of 60 cases. *Zhong Guo Kou Qiang He Mi-an Wai Ke Za Zhi* 1997;7:210-212.
12. Bosch JD, Kudryk WH, Johnson GH. The malignant lymphoepithelial lesion of the salivary glands. *J Otolaryngol* 1988;17:187-190.
13. Worley NK, Daroca PJ Jr. Lymphoepithelial carcinoma of the minor salivary gland. *Arch Otolaryngol Head Neck Surg* 1997;123:638-640.
14. Lu SY, Huang CC, Hsiung CY, Eng HL, Huang HY. Primary lymphoepithelioma-like carcinoma of minor salivary gland: a case report with immunohistochemical and in situ hybridization studies. *Head Neck* 2006;28:182-186.
15. Chen L, Liu W, Liu Y, Li F, Zhou Z. Clinicopathologic and immunohistochemical studies of midline malignant reticulosis in palate. *Hua Xi Yi Ke Da Xue Xue Bao* 1994;25:312-315.
16. Jaber MA. Intraoral minor salivary gland tumors: a review of 75 cases in a Libyan population. *Int J Oral Maxillofac Surg* 2006;35:150-154.