

Comparison of Measurements on Cone Beam Computed Tomography for Periodontal Intrabony Defect with Intra-surgical Measurements

Fei LI¹, Ping Yi JIA¹, Xiang Ying OUYANG¹

Objective: To explore the relationship between cone beam computed tomography (CBCT) measurements and direct measurements during the surgery to correct intrabony defects.

Methods: Forty-four patients with 44 intrabony defects who finished initial periodontal therapy and were considered for periodontal surgery were recruited. Digital periapical radiography and CBCT was performed before the surgery. The distance from the bottom of the defect to the cemento-enamel junction (CEJ-BD), the depth and mesio-distal width of the defect were measured on CBCT, periapical radiographs and during the surgery. The buccal-lingual width of the defect was only recorded on CBCT and during the surgery. Lastly, intra-surgical linear measurements were compared with measurements of radiographs and CBCT, respectively.

Results: The means of the intra-surgical CEJ to BD, the depth of the defect, the mesio-distal (M-D) width and the buccal-lingual (B-L) width of the defect were 8.90 mm, 5.52 mm, 3.35 mm and 7.40 mm, respectively. Between CBCT measurements and surgical measurements the differences for the CEJ to BD (0.76 ± 1.40 mm) and the depth of the defect (0.63 ± 1.67 mm) were statistically significant, but the differences for the M-D width (-0.17 ± 0.67 mm) and the B-L width (-0.16 ± 0.65 mm) of the defect were not statistically significant.

Conclusion: CBCT could provide relatively accurate measurements of the M-D width of the defect and additionally showed accurate measurements of the B-L width of the defect which periapical radiographs could not show. However, for vertical measurements of the intrabony defect (CEJ to BD and depth of the defect), when compared with measurements during the surgery, CBCT showed no advantages over periapical radiographs. A new method should be developed for accurately measuring the periodontal intrabony defects using CBCT in the future.

Key words: cone beam computed tomography, intrabony defect, linear measurement, periapical radiography

Gingival inflammation, periodontal pocket formation, attachment loss and alveolar bone resorption are the main features of periodontitis. These features are evaluated by clinical observation and periodontal prob-

ing, however this does not include bone loss. The alveolar bone resorption should be detected by radiograph¹, which includes periapical radiography, bitewing radiography and panoramic radiography. Periapical radiography is commonly used in clinical practice. Periodontal bone resorption, observed by periapical radiographs, is divided into vertical and horizontal bone resorption. Vertical resorption is characterised by the formation of intrabony defect observed during the surgery, which manifests as either a one-wall, two-wall or three-wall intrabony defect. Intrabony defects are three-dimensional (3D) structures in the vertical, mesio-distal and buccal-lingual direction. However, periapical radiographs provide only a two-dimensional (2D) view, which cannot provide all the information about periodontal intrabony defects².

¹ Department of Periodontology, Peking University School and Hospital of Stomatology, Beijing, P.R. China.

Corresponding author: Dr Xiang Ying OUYANG, Department of Periodontology, Peking University School and Hospital of Stomatology, #22 Zhongguancun South Avenue, Haidian District, Beijing 100081, P.R. China. Tel: 86-10-82195531; Fax: 86-10-62173402; Email: kqouyangxy@126.com

This work was supported by Beijing Municipal Science and Technology Plan the Capital Characteristic Clinical Application Research (Z141107002514059).

Cone beam computed tomography (CBCT), a relatively new imaging modality, was introduced to dentistry in the late 1990s and is now widely used in the dental field³⁻⁶. Compared with conventional computerised tomography (CT), CBCT has relatively lower doses, lower cost and displays 3D structures. Misch et al⁷ reported that all intrabony defects were detected using CBCT on mandibles of dry skulls, but only 67% of them were diagnosed using periapical radiographs. Interproximal bone loss could be detected on the periapical radiographs, but the extent and severity of intrabony defects cannot be shown because of the obstruction of the buccal plate. Vandenberghe et al⁸ evaluated the digital intraoral radiography and CBCT in order to determine periodontal bone loss on human cadaver and dry skulls. In their study, direct physical measurements on the skull models were the gold standard. When the distance from the cemento-enamel junction (CEJ) to the alveolar crest (AL) was measured, 80% of cases showed the measurement discrepancy within 0.5 mm measured by CBCT compared to the gold standard, but only 63% by intraoral radiographs. Both of these studies showed that the CBCT was better in evaluating the periodontal intrabony defect than periapical radiographs, but they were both *in vitro* studies. Few *in vivo* studies were performed which evaluated the periodontal bone defect. The aim of the present study was to explore the relationship between CBCT measurements and direct measurements during surgery.

Materials and methods

Subjects

Forty-four patients (22 women and 22 men) with an average age of 39 years old were recruited in this study, and they were diagnosed as generalised aggressive periodontitis (11 patients) or advanced chronic periodontitis (33 patients). They had already finished initial periodontal therapy. Periodontal surgeries were performed in the Peking University School of Stomatology between September 2011 and November 2014. Periodontal surgeries involved operating on at least one tooth with probing depths (PD) ≥ 5 mm, with the depth of intrabony defects ≥ 3 mm in periapical radiography and with bleeding on probing (BOP). Digital periapical radiography and CBCT were performed before the surgery and direct measurements of intrabony defects were recorded during the surgery. Patients with any of the following conditions were excluded from the study: smoking more than ten cigarettes per day; < 18 years of age; untreated

carious lesions or filling materials at the cemento-enamel junction (CEJ) which leads to difficulty in identifying the CEJ; metal crowns in the CBCT irradiation area or silver amalgam fillings near the alveolar crest. Overall, 44 intrabony defects were included (12 anterior teeth, 15 premolars, 17 molars). Amongst them, 3 one-wall defects, 9 two-wall defects, 12 three-wall defects and 20 combined defects were included, respectively. This study was approved by the Institutional Review Board of Peking University School of Stomatology.

Pre-surgical clinical measurement

Clinical examination was performed by experienced periodontists. Clinical parameters included pocket depth (PD), gingival recession (GR) and clinical attachment level (AL), which were measured on the buccal (labial) and lingual (palatal) sites using a periodontal probe graded in millimeters (UNC-15; HU-Friedy, Chicago, USA). Additionally the distance from the bottom of the intrabony defect to the CEJ was measured by means of bone sounding (BS), which is used for detecting bone level. If the parameters above were different in the buccal and lingual sites, the deepest value would prevail.

Intra-surgical clinical measurement

Surgery and intra-surgical measurements were performed under local anaesthesia by the experienced periodontist. During the surgery, after thorough debridement, all direct surgical measurements were made with a probe (HU-Friedy) (Fig 1a), accurate to the nearest 0.5 mm. The following parameters were measured:

- 1) Bone loss: The distance from CEJ to the bottom of the defect (CEJ-BD). The probe was placed along the root surface parallel to the tooth axis. The top of the probe was located in the most apical point of the defect. The probe was kept close to the interproximal contact point. The distance from CEJ to the bottom of the defect was recorded.
- 2) Depth of the intrabony defect: The distance from the bottom of the defect to the level of the alveolar bone crest. One probe was placed along the root surface as mentioned above. Another probe was placed horizontally, perpendicular to the tooth axis, on the crest level of the alveolar bone. The distance from the point of intersection of the two probes to the bottom of the defect was recorded as the depth of the defect.
- 3) Mesio-distal (M-D) width of the defect: Horizontal distance from the root surface to the mesial or distal edge of the bone defect at crest level. The probe was

placed horizontally and perpendicular to the root surface. The horizontal distance from the mesial or distal edge of the bone defect at crest level to the root surface was recorded.

- 4) Buccal-lingual (B-L) width of the defect: The horizontal distance from the buccal edge to the lingual edge of the bone defect at bone crest level. When the buccal and lingual bone walls were at the same level, the horizontal distance from the inside of the buccal edge to the inside of the lingual edge of the bone defect at the bone crest level was recorded. When the buccal and lingual bone walls were at different levels, one probe was placed vertically, along the tooth axis, on relatively lower bone crest. Another probe was placed horizontally on the relatively higher bone wall crest level. The distance from the intersection point of the two probes to the higher bone crest was recorded as the B-L width of the defect.

Intrabony defect measurements on periapical radiographs

Digital images were obtained using the long cone paralleling technique with a bite registration positioning device. The exposure setting was 70 kVp with 12 to 25 mA. The examiner took linear measurements by KADAK imaging software 6.12.17.0. using the monitor of a computer accurate to the nearest 0.1 mm. Parameters were measured as follows:

- 1) Bone loss: The distance from CEJ to the bottom of the defect⁹ (CEJ-BD in Fig 1b). The distance from the most apical point of the bottom of the defect to the CEJ was measured. The landmark of the bottom of the defect is the lowest discontinuous point of the periodontal ligament.
- 2) Depth of the intrabony defect: The distance from the point AC' to the bottom of the defect (AC'-BD in Fig 1b). AC is short for alveolar crest. A line perpendicular from the AC to the root surface was drawn. The intersection point across the root surface was AC'.
- 3) M-D width of the intrabony defect (AC-AC' in Fig 1b): The distance from the point AC' to the alveolar crest (AC). The line perpendicular from the top of the alveolar crest to the root surface was drawn as mentioned above.

Intrabony defect measurements on CBCT

CBCT was performed in the study area using the high-resolution imaging system (New tom VG, Quantitative Radiology, Verona, Italy) with the setting in the range

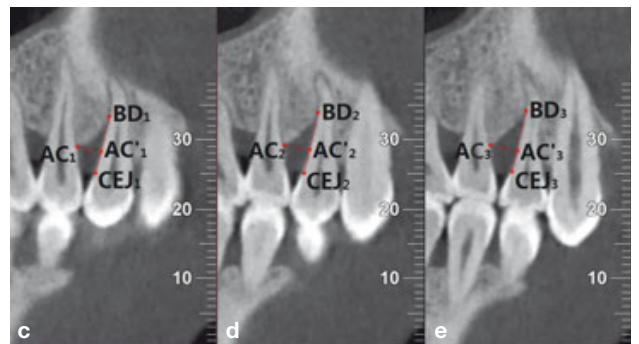
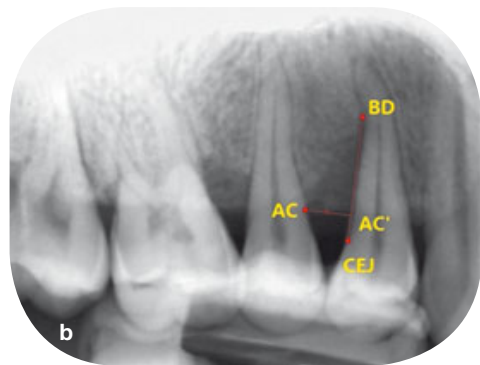
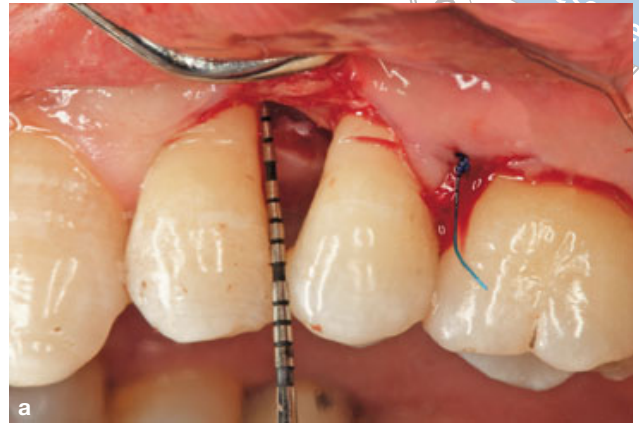

Fig 1 Intrabony defect measurements during the surgery, on the periapical photograph and on the CBCT. **a)** Clinial photograph during the surgery. The probe was placed along the root surface parallel to the tooth axis. **b)** Periapical photograph image. A line perpendicular from the top of the alveolar crest to the root surface was drawn. The intersection point across the root surface was AC'. The distance from AC' to BD was recorded as the depth of the defect. **(c-e)** Different sagittal planes for CBCT. Each slice was analysed for the different measures. The maximum value was chosen.

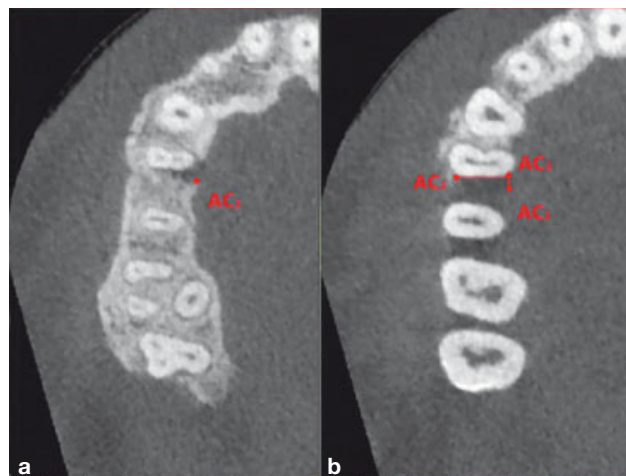
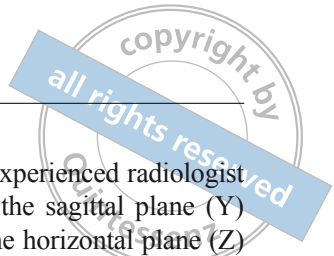


Fig 2 The B-L width of the defect was measured on the axial plane of the CBCT. **a)** Innermost and most apical point for the lingual alveolar crest was AC₁. **b)** Innermost and most coronal point for the buccal alveolar crest was AC₂; a line perpendicular from the AC₁ to the root surface was drawn. The intersection point across the root surface was AC₃. The horizontal distance of the two points (AC₂ to AC₃) was measured as the B-L width of the defect.

Table 1 General status of sites with intrabony defects before the surgery.

Clinical parameters	Measurement (mean ± standard deviation) (mm)
PD	7.06 ± 1.00
GR	0.28 ± 1.92
CAL	7.34 ± 1.91
BS	8.11 ± 1.12

PD: pocket depth; GR: gingival recession; AL: clinical attachment level; BS: bone sounding. The bottom of the defect to the CEJ was measured with a probe.

Table 2 Intra-examiner correlation coefficients.

	PR	CBCT
CEJ-BD	0.969	0.984
Depth of defect	0.979	0.980
M-D width of defect	0.906	0.983
B-L width of defect		0.990

PR: periapical radiograph; BD: bottom of the defect; M-D: mesio-distal; B-L: buccal-lingual.

of 12 to 17 mA and 110 KV. An experienced radiologist adjusted CBCT images to make the sagittal plane (Y) parallel to the axis of the tooth, the horizontal plane (Z) parallel to the bite plane, and reconstructed the image with 0.125 mm slice thickness. Then the volume data was sliced with 0.5 mm thickness in order to acquire adequate scanning data for measuring. Each slice was analysed for the separate measures because the extreme points for CEJ, BD and AC were usually located in two different slices. The parameters which were measured on CBCT included CEJ-BD, the depth of the defect and the M-D width of the intrabony defect. All parameters above were measured as the same as on the periapical radiographs (Figs 1c to 1e). Additionally, the B-L width of the defect was measured on the axial plane of the CBCT. When the B-L width of the defect was measured, the innermost and the most coronal point for the buccal and lingual alveolar crest was chosen on the axial plane, and the horizontal distance of two points were measured. (Figs 2a and 2b)

Statistical analysis

One examiner measured CBCT and periapical radiographs twice, at an interval of 7 days or more. The operator for clinical measurements was not the same person for the measurements on the images. Intra-class correlation coefficients (ICC) were used to assess inter-examiner agreement for the linear measurement by CBCT and periapical radiographs. A paired t-test was used to determine whether a statistically significant difference existed between CBCT measurements and intra-surgical measurements, and also between the periapical radiograph measurements and intra-surgical measurements. A P value of < 0.05 was used for all statistical analyses.

Results

The general status of all intrabony defects before the surgery was displayed in Table 1. All lesions consisted of deep pockets and severe bone loss. The intra-surgical measurements of intrabony defects were shown in Table 3. The distance from CEJ to BD varied from 6 mm to 11 mm, and the depth of the defect had a range of 4 mm to 9 mm, which showed all the intrabony defects had heavy damage.

ICC for inter-examiner agreement for CBCT measurements and periapical radiograph measurements are shown in Table 2. The ICC for each parameter measured on CBCT was more than 98%, and the ICC for each parameter measured on the periapical radiographs was less than that on the CBCT.

Table 3 Difference amongst intra-surgical measurements, periapical measurements and CBCT measurements.

Parameters of intrabony defect	Intra-surgical (mean ± standard deviation) (mm)	PR		CBCT	
		Mean ± standard deviation (mm)	Difference [#]	Mean ± standard deviation (mm)	Difference ^{##}
CEJ-BD	8.90 ± 1.73	8.09 ± 1.50	0.81 ± 1.07*	8.14 ± 1.63	0.76 ± 1.40*
Depth of defect	5.52 ± 1.51	5.19 ± 1.41	0.33 ± 0.99*	4.90 ± 1.66	0.63 ± 1.67*
M-D width of defect	3.35 ± 0.64	3.20 ± 0.42	0.15 ± 0.65	3.52 ± 0.50	-0.17 ± 0.67
B-L width of defect	7.40 ± 1.49			7.65 ± 1.49	-0.16 ± 0.65

PR: periapical radiograph; BD: bottom of the defect; M-D: mesio-distal; B-L: buccal-lingual; difference[#]: difference between intra-surgical and periapical measurements; difference^{##}: difference between intra-surgical and CBCT measurements; * $P < 0.05$.

The M-D width of the defect measured on the periapical radiograph was similar to that measured in surgery (difference: 0.15 ± 0.65 mm, $P > 0.05$). However the distance of CEJ to BD and the depth of the defect measured on the periapical radiograph were less than those measured in the surgery, and the differences (0.81 ± 1.07 mm, 0.33 ± 0.99 mm, respectively) were statistically significant ($P < 0.05$) (Table 3).

CBCT measurements for the B-L width and M-D width of the defect were similar to the intra-surgical measurements (difference between CBCT measurements and intra-surgical measurements: -0.16 ± 0.65 mm, 0.17 ± 0.67 mm, respectively, $P > 0.05$). But CBCT measurements for the CEJ to BD and the depth of the defect were significantly underestimated in respect to the intra-surgical measurements (difference between CBCT measurements and intra-surgical measurements: 0.76 ± 1.40 mm, 0.63 ± 1.67 mm, respectively, $P < 0.05$) (Table 3).

Discussion

Periodontal intrabony defect is a common periodontal lesion clinically, which consists of 3-D structures. Besides the height and the mesio-distal (M-D) width of the defect, the buccal-lingual (B-L) width of the defect could not be measured on periapical radiographs. However, the information about the B-L width of the defect is useful for operators to make an appropriate treatment plan and reliable prognosis¹⁰. In the present study, the method for measuring the B-L width of the defect was described and the B-L width of the defect in enrolled cases was measured on CBCT. The result showed that the B-L width of the defect measured on CBCT was similar to that measured in the surgery. To our knowledge, so far there is no published literature on comparing the CBCT measurements with intra-surgical measurements for the B-L width of the intrabony defect. Vasconcelos

et al¹¹ reported CBCT measurements for the B-L width of the defect. In their study, they measured B-L width of the defect on CBCT, but did not compare CBCT with intra-surgical measurements. In addition, the measuring method for the B-L width was not described in detail in their report. The measuring method for the B-L width of the defect described in our study is useful for clinicians in their clinical work, which could improve the outcome of surgical planning and prognosis assessment.

The M-D width of the intrabony defect was also measured by CBCT in our study. The measurement result was similar to the intra-surgical measurements, which suggested that CBCT measurements for the M-D width of the defect could truly reflect the status of the M-D width of the defect. The relative research is quite scarce, and none of them compared CBCT measurements for the M-D width of the defect with intra-surgical measurements. One *in vitro* study measured the M-D width of the intrabony defects⁷. In their research, the M-D width of artificial intrabony defects was measured on dry skulls by CBCT. Accessory gutta-percha cones as landmarks were placed into the grooves which were created vertically at each line angle initially. The distance from the bone crest to the landmark was measured as the B-L width of the defect. The measuring method was quite different from ours, but the result was similar to that measured on the defect impression which was the gold standard in the *in vitro* study. Additionally, in our research, when compared to the intra-surgical measurements, periapical radiographs also reflected the true status of the M-D width of the defect. So for the M-D direction, both CBCT and periapical radiographs could offer accurate information on the M-D width of the defect.

In our study, when measuring the CEJ-BD and the depth of the defect, CBCT measurements both underestimated bone loss compared with the surgical measurements (8.14 mm vs 8.90 mm and 4.90 mm vs 5.52 mm).

To our knowledge, there was no research to measure the depth of the defect on CBCT. Most of the research with regard to the CEJ-BD measured by CBCT were *in vitro* studies^{8,12-14}. Grimard et al¹⁵ compared cone-beam volumetric tomography (CBVT) measurements for CEJ-BD of intrabony defects with intra-surgical measurements. They sequentially analysed several slices to locate the most apical point of the BD, then measured the CEJ-BD. We also used the same measuring method. In their research, CBCT measurements for CEJ-BD were underestimations compared to direct surgical measurements, which was consistent with our study. One possible factor which could explain the result was that there is a varying degree of demineralisation in the bottom of the bone lesion, which could be detected on the periapical radiographs and CBCT, but eliminated in the surgery by thorough debridement. Another factor was that the bases of intrabony defects are more cancellous in living man, which means the probe can penetrate deeper and more easily during the surgery. Moreover, the probe was obstructed by the interproximal contact point during the surgery, therefore the probe was inclined when probing the intrabony defect, which meant the measurement during the surgery was not the exact bone loss or the depth of the defect. Therefore CBCT measurements for CEJ-BD and the depth of the defect may reflect the status of the defect more precisely than the intra-surgical measurements.

For the defect depths, as shown by the numerical results, the periapical radiograph measurement was closer to the direct surgical measurement than CBCT (5.19 mm vs 4.90 mm), but without statistical significance. The possible reason was that the most apical point of the bottom of the defect and the most coronal point of the alveolar ridge usually was not in the same slice for the CBCT image, but in periapical radiographs because of the overlap of the anatomical structures; these two points can be seen in one of the radiographs. With this measuring method, CBCT did not show any advantages in comparison to the periapical radiographs. A modified method should be developed to measure the vertical measurements of periodontal intrabony defect more accurately in the future.

Conclusion

At present, the clinical research related to the quantitative linear measurement of periodontal intrabony defects by CBCT are lacking. The present study explored the relationship between CBCT measurements and direct measurements during the surgery. It was found that CBCT images could provide relatively accurate meas-

urements of the M-D width of the defect and additionally allowed accurate measurements of the B-L width of the defect, which periapical radiographs could not. However, for vertical measurements of the intrabony defect (CEJ to BD and the depth of the defect), when compared with measurements during the surgery, CBCT showed no advantage to periapical radiographs. A new method should be developed for accurately measuring periodontal intrabony defects using CBCT in the future.

References

1. Jeffcoat MK. Radiographic methods for the detection of progressive alveolar bone loss. *J Periodontol* 1992;63:367-372.
2. Aljehani YA. Diagnostic applications of Cone-Beam CT for Periodontal Diseases. *Int J Dent* 2014;2014:865079.
3. Qiao J, Wang S, Duan J, et al. The accuracy of cone-beam computed tomography in assessing maxillary molar furcation involvement. *J Clin Periodontol* 2014;41:269-274.
4. Dave M, Davies J, Wilson R, Palmer R. A comparison of cone beam computed tomography and conventional periapical radiography at detecting peri-implant bone defects. *Clin Oral Implants Res* 2013;24:671-678.
5. Pan HY, Yang H, Zhang R, et al. Use of cone-beam computed tomography to evaluate the prevalence of root fenestration in a Chinese subpopulation. *Int Endod J* 2014;47:10-19.
6. Stavropoulos A, Wenzel A. Accuracy of cone beam dental CT, intraoral digital and conventional film radiography for the detection of periapical lesions. An ex vivo study in pig jaws. *Clin Oral Investig* 2007;11:101-106.
7. Misch KA, Yi ES, Sarment DP. Accuracy of cone beam computed tomography for periodontal defect measurements. *J Periodontol* 2006;77:1261-1266.
8. Vandenberghe B, Jacobs R, Yang J. Detection of periodontal bone loss using digital intraoral and cone beam computed tomography images: an in vitro assessment of bony and/or intrabony defects. *Dentomaxillofac Radiol* 2008;37:252-260.
9. Eickholz P, Hausmann E. Accuracy of radiographic assessment of interproximal bone loss in intrabony defects using linear measurements. *Eur J Oral Sci* 2000;108:70-73.
10. Langen HJ, Fuhrmann R, Diedrich P, Gunther RW. Diagnosis of infra-alveolar bony lesions in the dentate alveolar process with high-resolution computed tomography. Experimental results. *Invest Radiol* 1995;30:421-426.
11. de Faria Vasconcelos K, Evangelista KM, Rodrigues CD, Estrela C, de Sousa TO, Silva MA. Detection of periodontal bone loss using cone beam CT and intraoral radiography. *Dentomaxillofac Radiol* 2012;41:64-69.
12. Vandenberghe B, Jacobs R, Yang J. Diagnostic validity (or acuity) of 2D CCD versus 3D CBCT-images for assessing periodontal breakdown. *Oral Surg Oral Med Oral Pathol Oral Radiol Endod* 2007;104:395-401.
13. Mol A, Balasundaram A. In vitro cone beam computed tomography imaging of periodontal bone. *Dentomaxillofac Radiol* 2008;37:319-324.
14. Pinsky HM, Dyda S, Pinsky RW, Misch KA, Sarment DP. Accuracy of three-dimensional measurements using cone-beam CT. *Dentomaxillofac Radiol* 2006;35:410-416.
15. Grimard BA, Hoidal MJ, Mills MP, Mellonig JT, Nummikoski PV, Mealey BL. Comparison of clinical, periapical radiograph, and cone-beam volume tomography measurement techniques for assessing bone level changes following regenerative periodontal therapy. *J Periodontol* 2009;80:48-55.