

Guidelines for Root Canal Therapy

Society of Cariology and Endodontology, Chinese Stomatological Association (CSA)

Root canal therapy is currently the main method to treat pulpal and periapical diseases. Root canal therapy consists of a series of complex procedures, requires specific equipments, instruments and materials, and should be performed by qualified stomatologists (clinicians). Complicated cases should be referred to endodontic specialists or the clinicians trained by intense endodontic courses.

In 2004, the Society of Cariology and Endodontology of Chinese Stomatological Association (CSA) published the 'Practices and evaluation criteria of root canal therapy (Discussion Version)'. Since then, opinions and comments regarding the 'Discussion Version' have been widely circulated within the society. The final version of the guideline was based on systematic reviews of scientific literature and requirements for the edit of technical guidelines, through several rounds of discussions, revisions and supplements. The society recommends this guideline for stomatologists (clinicians) to use during endodontic treatment.

Chin J Dent Res 2015;18(4):213–216; doi: 10.3290/j.cjdr.a35144

1. Introduction

Pulp infections could occur by a variety of causes, mainly by dental caries. When it is not possible to preserve vital pulp, the root canal therapy (non-surgical) would be the first choice to preserve the tooth. During the therapy, the canal system is cleaned and sealed in order to stop infection development and prevent more serious complications. The procedure, involving endodontic treatment and its related techniques, is known as root canal therapy. Root canal therapy consists of cleaning and shaping, irrigation and disinfection, obturation with biocompatible materials, and final restoration of the treated tooth. The objective of root canal therapy is

to prevent periradicular diseases via the canal system, or to promote healing of existing periradicular lesions.

For failure cases of non-surgical root canal therapy, endodontic surgery or extraction could be prescribed.

2. Indications

Indications include irreversible pulpitis, pulp necrosis, inner root resorption and apical periodontitis, and intentional pulp extirpation due to other dental treatment needs such as tooth transplantation, replantation etc.

3. Diagnosis and treatment planning

3.1 Examination and evaluation for general health and oral conditions: conditions relevant to general health, and in the oral and maxillofacial region, dentition and compromised teeth should be carefully inquired, examined and assessed. A primary treatment plan should be discussed with the patient and may be revised as the treatment progresses. The inquiries and examinations should be recorded.

3.2 Make a diagnosis, treatment plan, prognosis assessment and the procedure scheme of the compromised tooth: a diagnosis should be made for the compromised tooth, based on the patient's chief complaint, disease history and the results of clinical examinations. A treatment plan and the specific procedures involved should

Translated by Dr Zhi Chun ZHANG and Prof Xue Jun GAO, Department of Cariology and Endodontology, Peking University School and Hospital of Stomatology, Beijing, P.R. China.

Corresponding author: Dr Xue Jun GAO, Department of Cariology and Endodontology, Peking University School and Hospital of Stomatology, #22 Zhongguancun South Avenue, Haidian District, Beijing 100081, P.R. China. Tel: 86-10-82195523; Email: kqxjgao@126.com

This work is supported by Special Research Projects for Public Health Welfare, Ministry of Public Health 201002017.

This manuscript was first published in the Chinese Journal of Stomatology (Zhonghua Kou Qiang Yi Xue Za Zhi) 2014;49(5):272–274 (in Chinese), and this is the second publication translated completely using the same contents as the original publication.

be determined, with consideration given to the patient's general health and oral condition. Experts, other than endodontists, should be consulted when necessary. The choice of root canal therapy should follow the aforementioned indications. General assessments to the prognosis outcome, technical difficulties, risk factors, any subsequent treatments and the cost, should be discussed with the patient before the start of the therapy. The patient should be well-informed and must provide consent. A formal informed consent sheet could be signed when necessary. Make sure that the patient has fully understood and agreed to the treatment.

4. Radiography

As a matter of routine, well-angulated periapical radiography should be prescribed for the compromised tooth. The film frame should cover the full length of the compromised tooth and two neighbouring teeth and at least 2 mm of the surrounding apical regions. A paralleling projection principle is recommended. Multiple periapical films with different angulations may be prescribed, in order to figure out the number, orientation and geometric patterns of the root canals. In specific cases, cone beam computed tomography (CBCT) could help with the understanding of the three-dimensional structure of the tooth and its relationship with surrounding tissues.

Periapical radiographs should be prescribed before and after the root canal therapy. Additional radiographs relating to the specific needs of treatments could be prescribed during the therapy.

5. Pain control

5.1 Obtain good pre-communication with the patient and create a calm atmosphere, in order to console the patient's nervousness, anxiety and fear.

5.2 Perform effective local anesthesia for pain control, including inferior alveolar nerve block, and supraperiosteal, periodontal, and intrapulpal injections.

6. Infection control

6.1 Fully sterilise instruments: to prevent cross-infection, instruments used in root canal therapy must be steam sterilised before use, and only for an individual patient and for one-time use.

6.2 Perform field isolation: rubber dam isolation is an effective way to achieve an isolated operative field for better infection control. It is recommended that this is used throughout the entire procedure of root canal therapy.

6.3 To prevent the dentinal, pulpal debris and infections passively shifting in the apical direction, the 'outside-in' and 'step-by-step' principles of surgical debridement should be strictly followed. It is recommended that carious tissue is removed ahead of access opening, there is pre-flaring of the coronal portion of the canal for timely and effective irrigation, and there is use of rotary instruments.

6.4 Reduce operative and visiting times.

6.5 Seal the cavity: reliable coronal seals between appointments and post-operation are essential to prevent the canals from re-infection.

7. Tooth preparation

7.1 Check the occlusion and the extent of the carious lesion, and draft an outline of initial access opening.

7.2 Remove all carious tissue, ill-fitting fillings and unsupported enamel, avoiding tooth fracture during the therapy.

7.3 Use glass-ionomer cement or resin composite to restore the proximal surface of the tooth in order to facilitate usage of a rubber dam.

7.4 Assess the treatment outcomes for the tooth against microfracture, especially when cracks indicate the cause of pulpal pathosis. Before the root canal therapy, multiple methods such as band restoration, a temporary crown, adhesion restoration and occlusion adjustment, should be undertaken to prevent further propagation of the cracks.

8. Key points for root canal preparation

8.1 Tooth isolation is mandatory in complete procedures of root canal therapy.

8.2 The objectives of the canal preparation are to remove infectious tissues and to shape the canal systems, in order to facilitate further procedures, including access opening, initial preparation, orifice location, canal negotiation, working length determination, root canal cleaning and irrigation.

8.3 Access opening and initial preparation: the outline is determined by tooth anatomy and canal distribution, with maximum preservation of healthy hard tissue. Ultrasonic instruments are recommended for safe removal of reparative dentin or other calcified tissues surrounding canal orifices. An operating microscope and other optical magnification devices are recommended to achieve proper magnification and illumination, which helps to distinguish different tissues, enhance the precision of operations and reduce unintentional injuries.

8.4 Flaring the coronal portion of canals and removing the pulpal residues: after locating the orifices, the coro-

nal portion of canals could be pre-flared, to facilitate irrigants and ensure the fine instruments reach and remove pulpal residues from the apical third of the canals.

8.5 Canal negotiation and working length determination

8.5.1 During the entire preparation process, root canals should be filled with an irrigant, usually 2.5% sodium hypochlorite (NaOCl).

8.5.2 Negotiating the canals, in order to have a basic knowledge of the patency of the root canals, with the orientation and diameter in mind.

8.5.3 The working length should be determined using an electronic apex locator.

8.5.4 When the working length is difficult to determine with the apex locator, additional radiographs could be taken with a diagnostic file in the canal.

8.5.5 The determined working length would be a key reference throughout the process of root canal preparation, irrigation and obturation.

8.6 Root canal cleaning, shaping and irrigating: to avoid extrusion of the debris and irrigant out of the apex, the working length, patency, original direction and taper of the root canals should be maintained. Instructions for use of stainless or NiTi-rotary instruments should be strictly followed.

8.7 Ultrasonic irrigation: ultrasonic irrigation is recommended for the final irrigation of the prepared root canals.

8.8 Management of instrument separation: it is recognised that files and instruments may accidentally separate within the canals, due to the integrated effects of various factors, such as the canal anatomy, the complexity of the operation and defects in the instruments. To prevent the separation, therefore, the instruments should be carefully maintained and checked before use, and should be correctly applied, by following the manufacturer's instruction. Whether or not the separated fragment should be retrieved from the canal, should be determined according to the specific clinical situation, with consideration for both pros and cons. If the separated fragment remains in the canal, obturation should be completed for the rest of the space in the canal, and should be recorded in the medical records.

8.9 Procedures after root canal preparation: the root canal could be obturated immediately after the canal preparation. When the clinical situation does not support a single visit, the obturation could be finished in a separate visit. An interappointment canal dressing should be applied between two visits.

8.10 Coronal filling: reliable temporary coronal filling with proper materials is essential for interappointment infection control. Glass-ionomer cement or composite resin is suggested to obtain reliable sealing.

9. Intracanal irrigant and interappointment medicament

9.1 Intracanal irrigant: a root canal irrigant should possess both irrigating and disinfecting properties. However, the irrigant needle and irrigating solution should not be forced beyond the apex, avoiding damage of the periapical tissue. Sodium hypochlorite (0.50% to 5.25%) and chlorhexidine (0.2% to 2.0%) are recommended for clinical use.

9.2 Other agents for root canal preparation included ethylene diamine tetraacetic acid (EDTA) with effects of demineralisation and lubrication, resinifying-materials dissolving solution and chloroform for dissolving gutta-percha in re-treatment.

9.3 Interappointment innercanal medicament: calcium hydroxide agent is recommended for inner canal medicament, and alternatively, are antibacterial agents and bioactive materials. It should avoid the use of phenolic and formaldehyde products as canal dressing. For cases with persistent symptoms, it is suggested analysing the true cause instead of prolonging the time of canal medication.

10. Root canal obturation

10.1 Time for root canal obturation: the canal obturation can be either finished immediately after the canal preparation or selectively at another visit, based on the clinical situation. For patients suffering from apical periodontitis with inflammatory exudation or with severe clinical symptoms, the obturation could be postponed until the clinical symptoms are alleviated and the infections are fully controlled.

10.2 Essential targets of root canal obturation: to promote apex closure and healing of periapical lesions, by stopping infections via obturation of the cleaned canal system with biocompatible materials.

10.3 Materials for root canal obturation

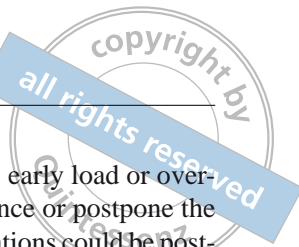
10.3.1 Core materials: gutta-percha, a mixture that contains natural gutta-percha and zinc oxide, is recommended as a core material.

10.3.2 Sealers: the sealers, which seal dentin tubules and small canal spaces, enhance the obturation effectiveness of core materials. Ideal sealers have biological properties for promoting growth of normal periapical tissues.

10.4 Key points for root canal obturation

10.4.1 The canals should be thoroughly cleaned, then dried with absorbent paper points before obturation.

10.4.2 A matched master gutta-percha cone should be selected and fitted.



10.4.3 Optimal amount of sealer should be placed.

10.4.4 A lateral or vertical compaction technique should be used to ensure density of the obturation, particularly in the apical one-third of the canal.

10.4.5 Removing extra materials from the chamber and filling the chamber securely.

10.5 Quality assurance of root canal obturation: a periapical radiograph should be taken to check the quality of obturation. Judged as 'adequate': filling materials occupy all canal spaces and end 0.5 to 2.0 mm from the apex, with the remaining canal images, which are non-radiolucent. 'Underfilling': the canal appears with less radiodensity, or the root fillings end greater than 2 mm from the apex. Underfilling is indicated for re-preparation and re-obturation. 'Overfilling' and 'overextending' are conditions in which the root canal fillings have been placed beyond the apical constriction. 'Overfilling' implies that a root canal system has been filled in three dimensions, but a surplus of filling material extrudes beyond the confines of the canal; 'overextending' implies that the filling materials have been placed beyond the confines of the canal but has not necessarily sealed the apical foramen. Overextending conditions are indicated for re-obturation.

10.6 Sealing the pulp chamber and temporary restoration: after canal obturation, the pulp chamber should be sealed up, in order to protect the root canal system from recontamination. For a short period (1 to 2 weeks) and a small access opening, zinc oxide cement is sufficient, but for a longer period of time or a larger defect, glass-ionomer cement or composite resin should be the choice, until a definite restoration is placed.

11. Final coronal restoration

11.1 The tooth should be restored soon after root canal therapy. A timely and optimal restoration is not only essential to function and aesthetics, but also prevents coronal leakage, which is essential to assure the effectiveness of the treatment.

11.2 Final coronal restorations include direct composite-resin restorations and indirect restorations like inlays, a full crown and a post-core crown. The amount of remaining sound tooth structures should be protected and carefully considered for retention and resistance. As to the posterior section, protective coverage of cusps is recommended.

11.3 Prevent recontamination of the root canal system during the restorations: the apical 5 mm-fillings should be kept well-sealed, in order to prevent coronal infections shifting towards the apex.

11.4 For large periradicular lesions, early load or overload on the treated tooth may influence or postpone the bone healing. Therefore, final restorations could be postponed until a certain extent of bone healing is apparent on the radiograph. Initial effects of bone healing can usually be identified on apical radiographs at 3 months after treatment.

12. Postoperative prescription and assessment of treatment outcomes

The patient should be informed about the importance of maintaining good oral health care, the necessity of regular oral examination and the time of the next visit. When necessary, the healing of the periradicular lesions can be dynamically followed up at 3, 6, 12 or 24 months, after root canal therapy. In the follow-up visits, symptoms and functional conditions of the treated tooth should be considered. Apical radiographs could be taken, in order to assess the healing condition of the periapical lesions. Meanwhile, oral health and plaque level could be systemically assessed, and advice could be given to the patient in a check-up visit.

13. Importance of keeping case records

The case records, including the root canal therapy, should be accurately kept, according to the medical service regulations. Complete and well-stored records are professional requirements as they demonstrate commitment to patients. Also, correct written and properly-stored records can provide sufficient evidence that clinical treatment was reasonable and acceptable.

References

1. AAE. Guide to clinical endodontics. Chicago: AAE, 2013.
2. European Society of Endodontology. Quality guideline for endodontic treatment: consensus report of the European Society of Endodontology. *Int Endod J* 2006;39:921-930.
3. Fan MW. Cariology and endodontology, ed 4 [In Chinese]. Beijing: People's Medical Publishing House, 2012.
4. Gao XJ, Yue L. Cariology and endodontology, ed 2 [In Chinese]. Beijing: Peking University Medical Press, 2013.
5. Hargreaves KM, Cohen S. Cohen's pathway of the pulp, ed 10. St. Louis: Mosby, 2010.
6. Ingle JI, Bakland LK and Baumgartner JC. Endodontics, ed 6. Hamilton: BC Becker, 2008.
7. Society of Cariology and Endodontology, Chinese Stomatological Association (CSA). Practices and evaluation criteria of root canal therapy [In Chinese]. *Hua Xi Kou Qiang Yi Xue Za Zhi (West China J Stomatology)* 2004;22:379-380.