

Int Poster J Dent Oral Med 2004, Vol 6 No 02, Poster 224

A New Approach in the Treatment of Oral Papillomatosis

Language: English

Authors:

Dr. Martin Horodko,
 Prof. Dr. Bernd d'Hoedt,
 Department of Oral Surgery, University of Mainz, Germany
 Prof. Dr. Helmut Schöfer,
 Department of Dermatology, University of Frankfurt/Main

Date/Event/Venue:

June, 19-22th, 2003
 Europerio 04
 Berlin/Germany

Introduction

Patient: This report describes the case of a 39-year-old male patient who had been infected with HIV (CDC stage B3) for 18 years. Under antiviral abacavir, lamivudine, and zidovudine therapy, the virus load dropped below the detection limit. The CD4 cell count increased to 250 cells per microliter. The patient initially presented at the dental clinic one year after detecting painless gingival hyperplasia.

Objectives

Clinical Findings: The lower jaw showed pronounced irregular granular (cauliflower-like) growth with a cleft surface between the first mandibular premolars on both sides (Figs. 1 and 2). Solitary papules approximately 6 mm in size were found on the edentulous alveolar ridge in the region of the right mandibular first molar, on the mucosa of the lower lip, and on the vestibular papilla in the region of the right maxillary lateral incisor.

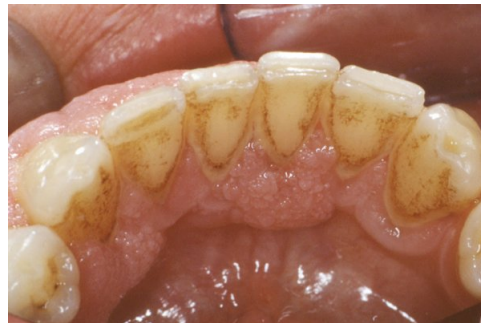
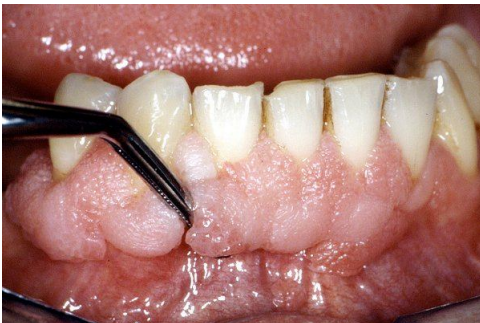
Figure 1: Vestibular view of the mandible, irregular granular growth with a rimose surface

Figure 2: Lingual view of the mandible

Material and Methods

Micromorphological Findings: To confirm the diagnosis, a mucosal biopsy was performed in the region of the right maxillary lateral incisor. Histopathologically, the overview (Fig. 4a) shows a pronounced acanthotically widened mucosal epithelium with parakeratosis and scattered lymphocyte infiltrates in the upper corium. The detailed view (Fig. 4b) shows ballooned keratinocytes and koilocytes, some of them with a parakeratotic keratinization pattern and keratohyaline granula of varying sizes. In summary, these findings are consistent with an HPV (human papillomavirus) infection (mucosal papillomatosis)

The DNA of HPV subtype 6 was demonstrated in two mucosal samples using a PCR-based test. This confirmed the clinical suspicion of an oral manifestation of condylomata acuminata, genital warts that usually occur in the genitoanal region.

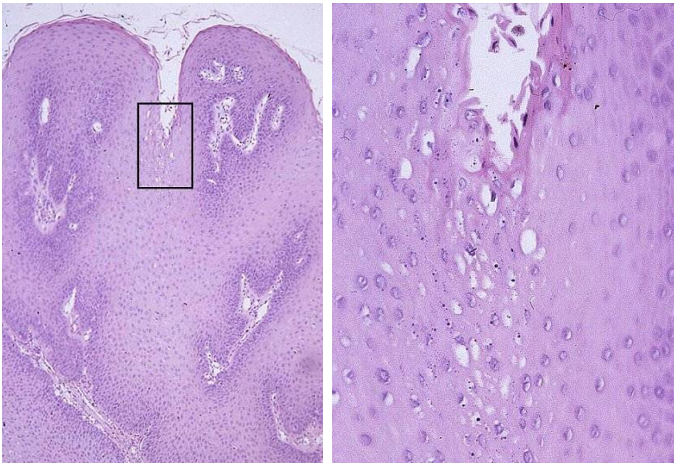


Figure 4: Histology of the mucosal biopsy

a. Overview

b. Detail

Results

Diagnosis: Oral papillomatosis/condylomata acuminata (HPV subtype 6), by genitoanal-oral transmission.

Discussion and Conclusions

Therapy: With the patient's informed consent, we treated the lesions using a 5% imiquimod cream (Aldara®, 3M Medica) approved for the treatment of genitoanal condylomata acuminata. This preparation was applied without ablative pre-treatment, twice to three times a week, over a period of eight weeks. No adverse effects were noted during the treatment course. The preparation was well tolerated. Full remission was observed after eight weeks of treatment. No recurrence was seen within the subsequent 24-month period (Fig. 3).

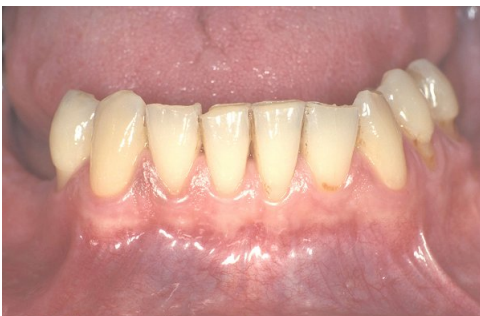

Figure 3: Vestibular view of the mandible, 24-month follow-up, complete remission

Discussion: Established invasive and traumatic therapeutic procedures, such as laser-assisted ablation, are characterized by high relapse rates, which in HIV-positive patients may reach 60 % to 70 %.

Imiquimod enhances the physiological immune reaction, releasing large amounts of interferon- α and tumor necrosis factor- α from monocytes, macro-phages, and dendritic cells.

Further observation will have to show whether the treatment result will remain stable over time.

Summary and Conclusion: After a total of eight weeks of applying the imiquimod cream, the oral condylomas showed complete regression. This substance offers new opportunities for the treatment of oral HPV infection even in immunocompromised patients.

We would like to thank the Senckenberg Institute for Pathology, Frankfurt/Germany (director: Prof. M.-L. Hansmann) for their histopathological evaluation and the Clinic for Dermatology and Venerology of the University of Rostock/Germany (director: Prof. G. Gross) for PCR virotyping.

This poster was submitted by Dr. Martin Horodko.

Correspondence address:

Dr. Martin Horodko

Poliklinik für Zahnärztliche Chirurgie

Augustusplatz 2

55131 Mainz

Germany

Poster Faksimile:

326

A New Approach in the Treatment of Oral Papillomatosis

M. Horodko¹, H. Schöfer², B. d'Hoedt¹

¹ Department of Oral Surgery, University of Mainz, Germany.

² Department of Dermatology, University of Frankfurt/M., Germany.



Patient:

This report describes the case of a 39-year-old male patient who had been infected with HIV (CDC stage B3) for 18 years. Under antiviral abacavir, lamivudine, and zidovudine therapy, the virus load dropped below the detection limit. The CD4 cell count increased to 250 cells per microliter.

The patient initially presented at the dental clinic one year after detecting painless gingival hyperplasia.

Clinical Findings:

The lower jaw showed pronounced irregular granular (cauliflower-like) growth with a cleft surface between the first mandibular premolars on both sides (Figs. 1 and 2). Solitary papules approximately 6 mm in size were found on the edentulous alveolar ridge in the region of the right mandibular first molar, on the mucosa of the lower lip, and on the vestibular papilla in the region of the right maxillary lateral incisor.

Micromorphological Findings:

To confirm the diagnosis, a mucosal biopsy was performed in the region of the right maxillary lateral incisor. Histopathologically, the overview (Fig. 4a) shows a pronounced acanthotically widened mucosal epithelium with parakeratosis and scattered lymphocyte infiltrates in the upper corium. The detailed view (Fig. 4b) shows ballooned keratinocytes and koilocytes, some of them with a parakeratotic keratinization pattern and keratohyaline granula of varying sizes. In summary, these findings are consistent with an HPV (human papillomavirus) infection (mucosal papillomatosis)

The DNA of HPV subtype 6 was demonstrated in two mucosal samples using a PCR-based test. This confirmed the clinical suspicion of an oral manifestation of condylomata acuminata, genital warts that usually occur in the genitoanal region.

Diagnosis:

Oral papillomatosis/condylomata acuminata (HPV subtype 6), by genitoanal-oral transmission.

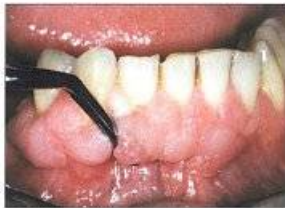

Figure 1: Vestibular view of the mandible, irregular granular growth with a rimose surface

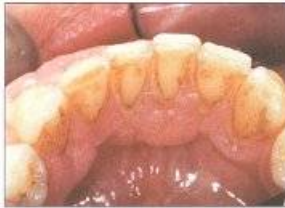

Figure 2: Lingual view of the mandible

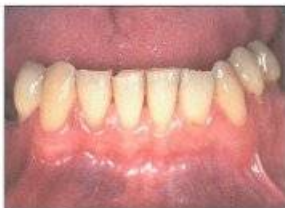

Figure 3: Vestibular view of the mandible, 24-month follow-up, complete remission

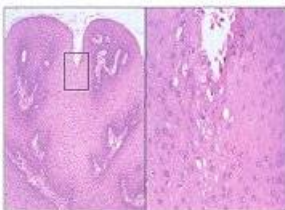


Figure 4: Histology of the mucosal biopsy
a. Overview
b. Detail

Therapy:

With the patient's informed consent, we treated the lesions using a 5% imiquimod cream (Aldara®, 3M Medica) approved for the treatment of genitoanal condylomata acuminata. This preparation was applied without ablative pre-treatment, twice to three times a week, over a period of eight weeks. No adverse effects were noted during the treatment course. The preparation was well tolerated.

Full remission was observed after eight weeks of treatment. No recurrence was seen within the subsequent 24-month period (Fig. 3).

Discussion:

Established invasive and traumatic therapeutic procedures, such as laser-assisted ablation, are characterized by high relapse rates, which in HIV-positive patients may reach 60% to 70%.

Imiquimod enhances the physiological immune reaction, releasing large amounts of interferon- α and tumor necrosis factor- α from monocytes, macrophages, and dendritic cells.

Further observation will have to show whether the treatment result will remain stable over time.

Summary and Conclusion:

After a total of eight weeks of applying the imiquimod cream, the oral condylomas showed complete regression. This substance offers new opportunities for the treatment of oral HPV infection even in immunocompromised patients.

For references, please contact the author:
horodko@uni-mainz.de

We would like to thank the Senckenberg Institute for Pathology, Frankfurt/Germany (director: Prof. M.-L. Hansmann) for their histopathological evaluation and the Clinic for Dermatology and Venerology of the University of Rostock/Germany (director: Prof. G. Gross) for PCR virotyping.