

Prevalence of symptoms of disturbed development of the dentition

Language: English

Authors:

Dr. Wibke Steffen, Dept. of Orthodontics, Hannover Medical School, Germany

Dr. med. dent. Johannes Röhling, Private Orthodontic Practice, Bielefeld, Germany

PD Dr. med. Dr. med.dent. Oskar Bauss, Dept. of Orthodontics, Hannover Medical School and Private Orthodontic Practice, Bielefeld

Date/Event/Venue:

June 7th to 11th, 2004

80th Congress of the European Orthodontic Society

Aarhus, Denmark

Introduction

Congenital hypodontia is one of the most frequent anomalies of the human dentition, representing an occasionally serious disturbance in its development. Several symptoms indicate a predisposition to disturbed development of the dentition with a genetic influence (1-3). The aim of the present study was to examine the prevalence of such symptoms in a group of patients undergoing orthodontic treatment.

Material and Methods

The pretreatment panoramic radiographs of 986 orthodontic patients (463 female, 505 male) treated at a private practice were evaluated retrospectively for nine symptoms of disturbed odontogenesis (hypodontia, delayed mineralisation of tooth buds, hyperodontia, atypical position of tooth buds, microdontia, displaced teeth, taurodontism, increased distance between molar tooth buds (only for permanent teeth) and infraposition of deciduous molars) (Fig. 1). The mean age of the patients was 11.8 years (range 6.9 to 15.8 years). Patients with a cleft lip and palate or syndromal diseases were excluded from this study.

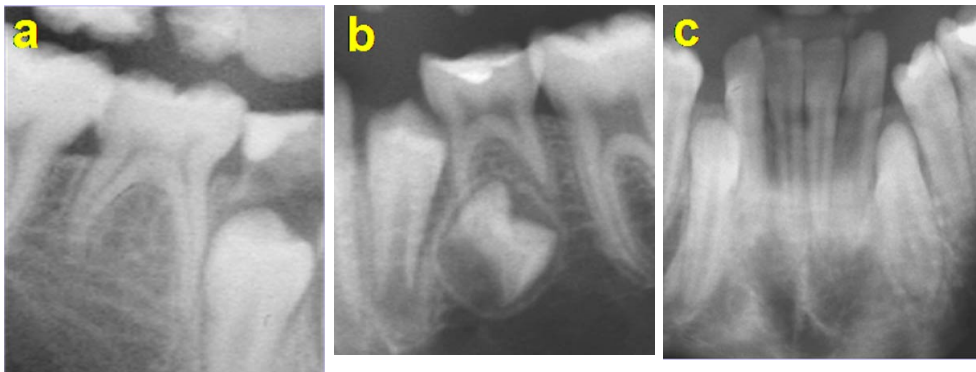


Fig. 1: Various symptoms of disturbed odontogenesis. (a) Missing tooth bud 45. (b) Atypical position of tooth bud 35. (c) Displaced teeth 33/43

Results

300 patients (31%) were found to have one or more symptoms of a disturbed development of the dentition. One single symptom was registered in 217 cases (22%), while two or more symptoms were found simultaneously in 83 cases (9%). 149 patients (16%) were recorded to have at least one permanent tooth bud in an atypical position (Fig. 2), with a total of 219 affected teeth. Atypical positions were most frequent with upper canines (30%), followed by lower second premolars (29%) and upper second premolars (18%). Table 1 gives a detailed survey of the atypical tooth positions.

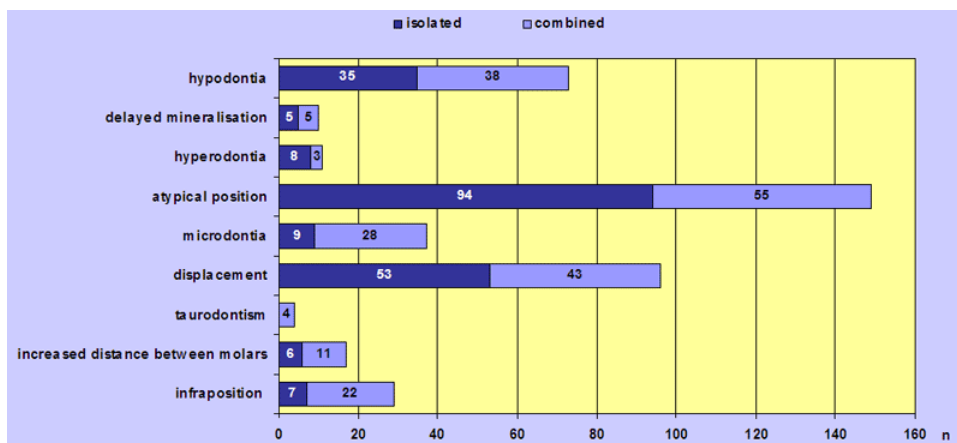


Fig. 2: Appearance of symptoms recorded isolated or in combination

Displacement of one or more teeth was observed in 96 cases with a total of 137 teeth (Fig. 2). Most frequently the displacement was recorded for upper canines (65%), followed by lower second premolars (7%) and upper second premolars (7%). In 43 patients (45%) displacement was observed in combination with other symptoms. The most frequent of these was atypical position of tooth buds, followed by microdontia and hypodontia (Fig. 3). Table 1 gives a detailed survey of all displaced teeth.

Hypodontia of at least one missing tooth was recorded in 89 patients (Fig. 2). 131 tooth buds were missing. The most frequent affected tooth was the lower second premolar (54%), followed by the second upper premolar (27%) and the upper lateral incisor (21%).

Tooth	A	B	C	Tooth	A	B	C
11	0	0	2	21	0	1	1
12	2	7	3	22	3	14	4
13	36	1	50	23	29	1	39
14	8	0	2	24	6	0	1
15	20	11	3	25	18	14	6
16	0	0	0	26	0	0	0
17	0	0	0	27	0	0	0
41	0	3	0	31	0	1	0
42	0	4	3	32	0	1	1
43	14	0	4	33	14	0	4
44	4	1	0	34	2	0	2
45	37	36	4	35	26	35	6
46	0	0	0	36	0	0	0
47	0	1	1	37	0	1	1

Table 1: Distribution of atypical positions of tooth buds (A), absent tooth buds (B) and displaced teeth (C).

In combination with other symptoms hypodontia appeared in 54 patients (70%). The most frequent combination turned out to be with atypical position of tooth buds, followed by displacement and microdontia (Fig. 3). Table 1 gives a detailed survey of all missing tooth buds.

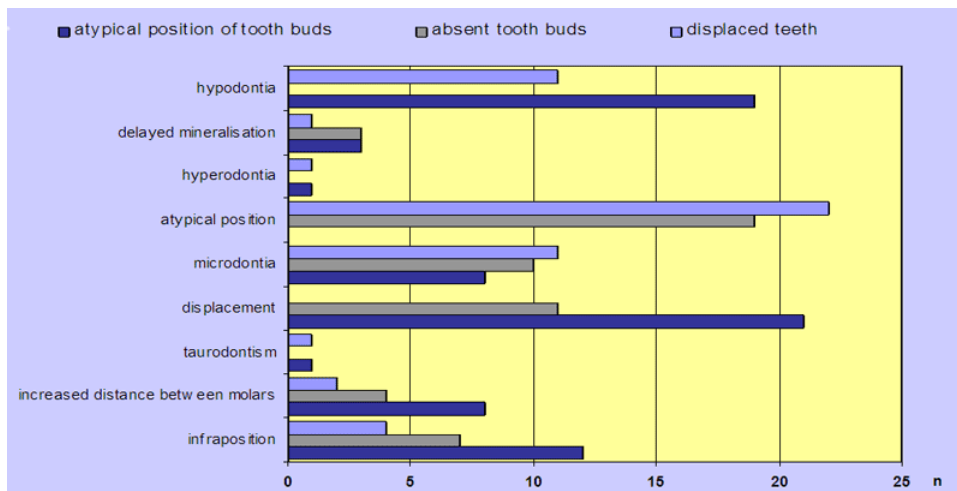


Fig. 3: Combination of 3 different symptoms of disturbed odontogenesis

Conclusions

The prevalence of symptoms of a disturbed development of the dentition presented in this study proves to be 31%. Stahl et al. (4) recorded this finding in a similar proportion of their orthodontic patients. The present findings emphasize the great epidemiological significance of these symptoms. Atypical position of tooth buds (16%), displacement of permanent teeth (10%) and absence of tooth buds of permanent teeth (9%) appeared to be the most frequent symptoms recorded in this study. The incidence of these symptoms is also in line with the findings reported by Stahl et al. (4).

The initial detection of symptoms of a disturbed development of the dentition suggests that further developmental disturbances are likely to be encountered to some degree. Early recognition of those symptoms allow early application of preventive orthodontic measures despite any predisposition.

Literature

- Baccetti T. Tooth anomalies associated with failure of eruption of first and second permanent molars. *Am J Orthod Dentofacial Orthop* 2000; 118: 608-10.
- Hoffmeister H. Microsymptoms as an indication for familial hypodontia, hyperdontia and tooth displacement. *Dtsch Zahnärztl Z* 1977; 32: 551-61.
- Steffen W, Bauss O, Röhling J, Schwestka-Polly R. Störungen der Gebissentwicklung bei Patienten einer kieferorthopädischen Fachpraxis. Eine radiologische Auswertung mit Hilfe von Panoramaschichtaufnahmen. *Quintessenz* 2004; 55: 1249-1258.
- Stahl F, Grabowski R, Wigger K. Epidemiological significance of Hoffmeister's Genetically determined predisposition to disturbed development of the dentition. *J Orofac Orthop* 2003; 64: 243-55.

This Poster was submitted by Dr. Wibke Steffen.

Correspondence address:

Dr. Wibke Steffen
 Dept. of Orthodontics
 Carl-Neuberg-Str. 1
 30625 Hannover
 Germany

Prevalence of symptoms of a disturbed development of the dentition

W. Steffen^{1,2}, J. Röhling¹, O. Bauss^{1,2}

¹Private Orthodontic Practice, Bielefeld, Germany

²Department of Orthodontics, Hannover Medical School, Hannover, Germany

Aim

Congenital hypodontia is one of the most frequent anomalies of the human dentition, representing an occasionally serious disturbance in its development. Several symptoms indicate a predisposition to disturbed development of the dentition with a genetic influence¹⁻³. The aim of the present study was to examine the prevalence of such symptoms in a group of patients undergoing orthodontic treatment.

Patients and Methods

The pretreatment panoramic radiographs of 986 orthodontic patients (463 female, 505 male) treated at a private practice were evaluated retrospectively for nine symptoms of disturbed odontogenesis (hypodontia, delayed mineralisation of tooth buds, hyperdontia, atypical position of tooth buds, microdontia, displaced teeth, taurodontism, increased distance between molar tooth buds (only for permanent teeth) and intraposition of deciduous molars) (Fig. 1). The mean age of the patients was 11.8 years (range 6.9 to 15.8 years). Patients with a cleft lip and palate or syndromal diseases were excluded from this study.

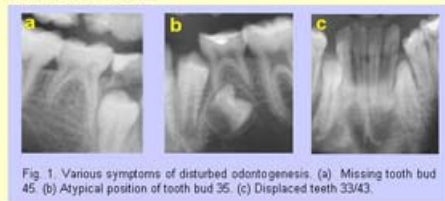

Fig. 1. Various symptoms of disturbed odontogenesis: (a) Missing tooth bud 45. (b) Atypical position of tooth bud 35. (c) Displaced teeth 33/43.

Results

300 patients (31%) were found to have one or more symptoms of a disturbed development of the dentition. One single symptom was registered in 217 cases (22%), while two or more symptoms were found simultaneously in 83 cases (9%). 149 patients (16%) were recorded to have at least one permanent tooth bud in an atypical position (Fig. 2), with a total of 219 affected teeth. Atypical positions were most frequent with upper canines (30%), followed by lower second premolars (29%) and upper second premolars (18%). Table 1 gives a detailed survey of the atypical tooth positions.




Fig. 2. Appearance of symptoms recorded isolated or in combination

Displacement of one or more teeth was observed in 96 cases with a total of 137 teeth (Fig. 2). Most frequently the displacement was recorded for upper canines (65%), followed by lower second premolars (7%) and upper second premolars (7%). In 43 patients (45%) displacement was observed in combination with other symptoms. The most frequent of these was atypical position of tooth buds, followed by microdontia and hypodontia (Fig. 3). Table 1 gives a detailed survey of all displaced teeth. Hypodontia of at least one missing tooth was recorded in 69 patients (Fig. 2). 131 tooth buds were missing. The most frequent affected tooth was the lower second premolar (54%), followed by the second upper premolar (27%) and the upper lateral incisor (21%).

Tooth	A	B	C	Tooth	A	B	C
11	0	0	2	21	0	1	1
12	2	7	3	22	3	14	4
13	36	1	50	23	29	1	39
14	9	0	2	24	6	0	1
15	20	11	3	25	18	14	6
16	0	0	0	26	0	0	0
17	0	0	0	27	0	0	0
41	0	3	0	31	0	1	0
42	0	4	3	32	0	1	1
43	14	0	4	33	14	0	4
44	4	1	0	34	2	0	2
45	37	36	4	35	26	35	6
46	0	0	0	36	0	0	0
47	0	1	1	37	0	1	1

Table 1. Distribution of atypical positions of tooth buds (A), absent tooth buds (B) and displaced teeth (C).

In combination with other symptoms hypodontia appeared in 54 patients (70%). The most frequent combination turned out to be with atypical position of tooth buds, followed by displacement and microdontia (Fig. 3). Table 1 gives a detailed survey of all missing tooth buds.

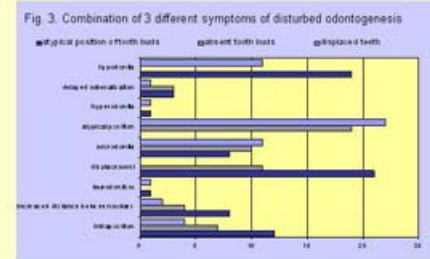


Fig. 3. Combination of 3 different symptoms of disturbed odontogenesis

Discussion

The prevalence of symptoms of a disturbed development of the dentition presented in this study proves to be 31%. *Stahl et al.*⁴ recorded this finding in a similar proportion of their orthodontic patients. The present findings emphasize the great epidemiological significance of these symptoms. Atypical position of tooth buds (16%), displacement of permanent teeth (10%) and absence of tooth buds of permanent teeth (9%) appeared to be the most frequent symptoms recorded in this study. The incidence of these symptoms is also in line with the findings reported by *Stahl et al.*⁴

Conclusion

The initial detection of symptoms of a disturbed development of the dentition suggests that further developmental disturbances are likely to be encountered to some degree. Early recognition of those symptoms allow early application of preventive orthodontic measures despite any predisposition.

References

1. *Baccetti T.* Tooth anomalies associated with failure of eruption of first and second permanent molars. *Am J Orthod Dentofacial Orthop* 2000; 118: 608-10.
2. *Hoffmeister H.* Microsymptoms as an indication for familial hypodontia, hyperdontia and tooth displacement. *Dtsch Zahnärztl Z* 1977; 32: 561-61.
3. *Steffen W, Bauss O, Röhling J, Schweska-Polly R.* Störungen der Gebissentwicklung bei Patienten einer kieferorthopädischen Fachpraxis. Eine radiologische Auswertung mit Hilfe von Panoramaschichtaufnahmen. *Quintessenz* 2004; 55: 1249-1258.
4. *Stahl F, Grabowski R, Wigger K.* Epidemiological significance of Hoffmeister's „Genetically determined predisposition to disturbed development of the dentition. *J Orofac Orthop* 2003; 64: 243-55.