

Int Poster J Dent Oral Med 2009, Vol 11 No 1, Poster 438

Mucormycosis – A case report

Language: English

Authors: Dr Naik Shantala Ramdas, Prof Dr Ashok Lingappa
Department of Oral Medicine and Radiology, Bapuji Dental College and Hospital, Davangere, India

Date/Event/Venue:
4th and 5th July 2007
Tripple O National symposium
Belgaum, Karnataka, India

Poster Award

Best poster in infection category

Introduction

A 58 year old male patient came to our department with a chief complaint of pain in the upper front teeth region since 15 days. Patient gave a history of peanut sized swelling which appeared in the upper front teeth region and ruptured in 1-2 days to form an ulcer. It was associated with pain which was gradual in onset, throbbing, severe, continuous, radiating to temporal region and aggravating on bending down. Patient also gave a history of nasal obstruction and difficulty in breathing since 15 days and a history of fever since 15 days and more during night hours. There was mobility of the upper teeth region and which were extracted during the course 3 months back.

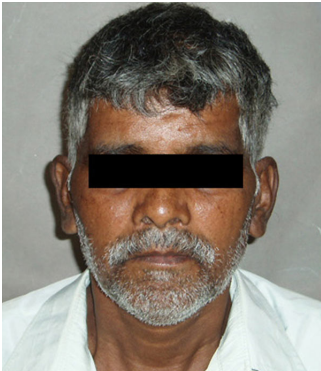

Fig 1

Objectives

Patient was a known diabetic since 1 year and was on diet control. He was hospitalized 3 months back for the same complaint and was diagnosed as having infection and was treated for the same and endoscopic guided debridement was done. General physical examination revealed moderately built and nourished patient with pallor of conjunctiva and nails with a temperature of 98.6° Farenhite, blood pressure was 138/80 mm of Hg and submandibular lymphadenopathy was present. Extraorally tenderness was present over right and left maxillary sinus area and halitosis of fishy odor was present. Intra orally necrotizing ulcer was present involving the 2/3rd of palate and covered by black / brownish yellow slough, completely deprived of soft tissues, exposing the naked bone with irregular borders and erythematous mucosa, slough was scrapable and no bleeding was evident. So we gave a provisional diagnosis of deep fungal infection and differential diagnosis of, chronic non healing ulcer, mucormycosis and midline lethal granuloma were thought of.

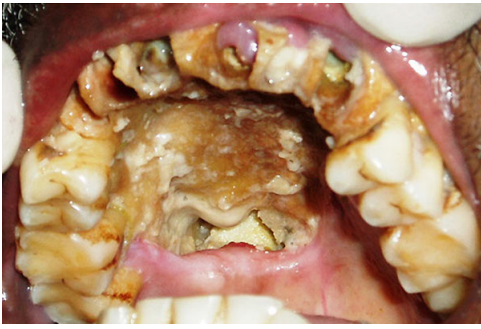

Fig 2: intra oral necrotizing ulcer

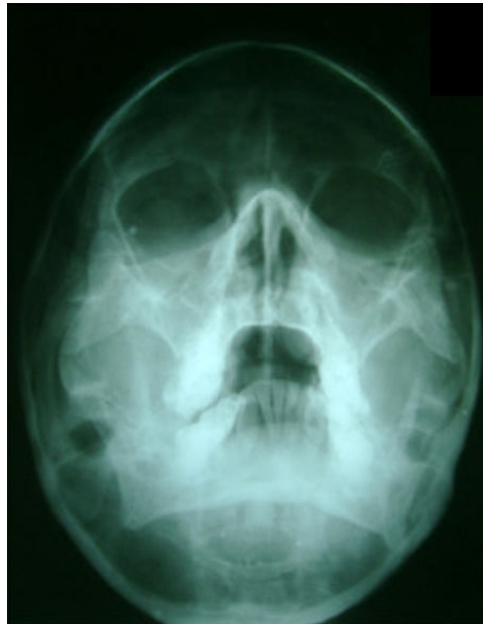

Fig 3: 30° occipito mental view showing complete opacification of maxillary sinuses

Material and Methods

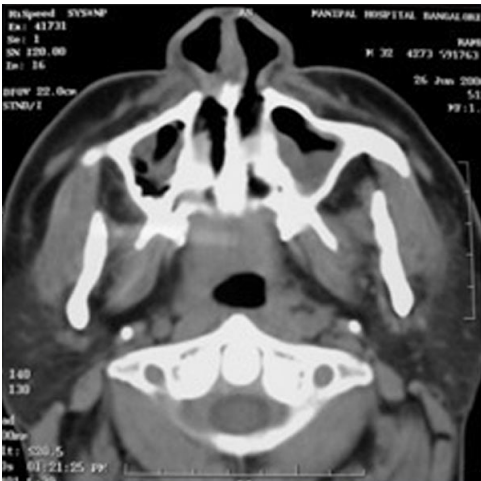

Fig 4: CT scan showing thickening of the sinus lining of soft tissue density (axial view)

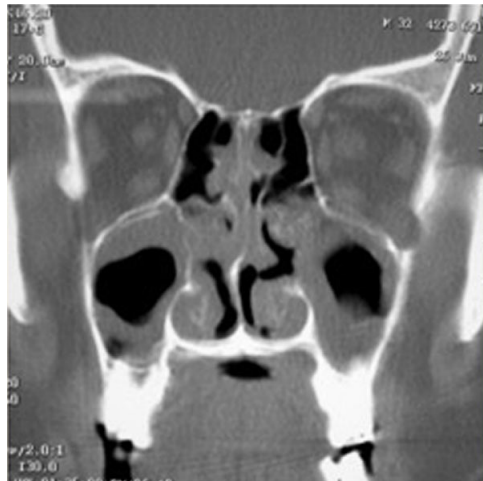

Fig 5: CT scan showing thickening of the sinus lining of soft tissue density (coronal view)

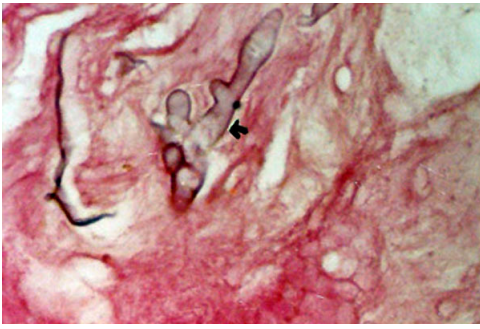


Fig 6: Histopathologically numerous fungal hyphae were seen invading the connective tissue associated with chronic inflammatory cells

Later the patient was subjected to following investigation like fasting blood sugar which was 95mg%, hemoglobin was 11.2gm%, total count was 8000 cells/cubic mm. Later a 30° occipital mental projection was taken which showed complete opacification of maxillary sinuses. Computed tomography revealed thickening of the sinus lining of soft tissue density. Biopsy was done from the palatal mucosa which revealed numerous fungal hyphae invading the connective tissue associated with chronic inflammatory cells.

Results

A final diagnosis of mucormycosis of the maxilla was given.

Conclusions

Patient was treated as in patient. During this course he had received the following treatment. It included, injection gentamycin 80mg bid, tab sparfloxacin 200mg od, tab amphoterecin B 25mg, tab fluconazole 150mg od and tab Dolo 650 tid. Patient was later followed up and after 3 months post treatment an obturator was constructed and patient was asked to continue the previous medication. Following this the patient came for a regular check up and healing was uneventful.

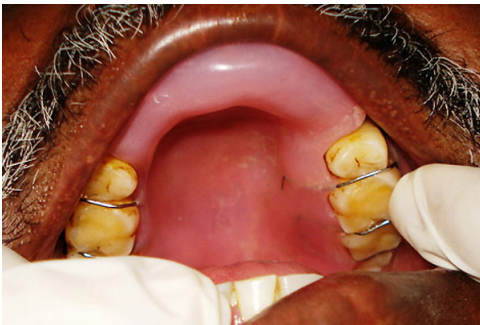

Fig 7: Post treatment

This Poster was submitted by [Dr Naik Shantala Ramdas](#).

Correspondence address:

[Dr Naik Shantala Ramdas](#)
Rajiv Gandhi University of Health Sciences
Post Graduate Department of Oral Medicine and Radiology
Bapuji Dental College and Hospital
Davangere, 577004
India

Mucormycosis

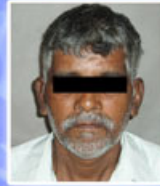Authors :

Naik Shantala R¹, Lingappa Ashok.²

¹: Post Graduate, ²: Professor and HOD,
Dept of Oral Medicine & Radiology, Bapuji Dental College & Hospital, Davangere

A Case Report

Mucormycosis is a opportunistic fungal infection more commonly seen in immuno compromised host, more commonly in uncontrolled diabetic individuals. Herewith presenting a similar case involving the maxillary sinus where in a 58 year old male patient complained of pain in the upper front teeth region since 15 days



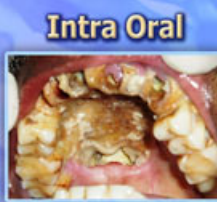Patient gave a history of peanut sized swelling which appeared in the upper front teeth region which ruptured in 1-2 days to form an ulcer, and was associated with pain which was gradual in onset, throbbing, severe, continuous, radiating to temporal region and aggravating on bending down. Patient also gave a history of nasal obstruction and difficulty in breathing since 15 days. Patient also gave history of fever since 15 days and more during night hours. There was mobility of upper front teeth region and which were extracted during the course 3 months back

Patient was a known diabetic since 1 year and was on diet control. Patient was hospitalized 3 months back for the same complaint and was diagnosed as having infection and was treated for same and endoscopic guided debridement was done.

Extra orally tenderness was present over right & left maxillary sinus area and halitosis (Fishy Odor) was present

general physical examination revealed moderately built & nourished patient with palloriness of conjunctiva and nails, with a temperature of 98.6°F BP=138/80mm Hg and Submandibular lymphadenopathy was present

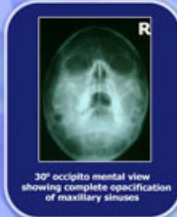Intra orally necrotizing ulcer was present involving the 2/3rd of the palate covered by black/brownish yellow slough, completely deprived of soft tissue, exposing the naked bone with irregular borders and erythematous mucosa, slough was scrapable and no bleeding was evident.



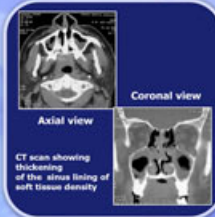P/D : Deep fungal infection
D/D : Chronic non healing ulcer, Mucormycosis and Midline lethal granuloma

Investigations

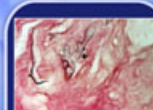FBS: 95mg%
Hb: 11.2gm %
Total count: 8000 cells/mm³



30° occipito mental view showing complete opacification of maxillary sinuses



CT scan showing thickening of the sinus lining of soft tissue density



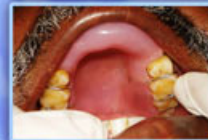histopathologically numerous fungal hyphae were seen invading the connective tissue associated with chronic inflammatory cells.

Final Diagnosis
Mucormycosis of maxilla

Treatment Given

Inj Gentamycin 80mg bid
Tab Sparfloxacin 200mg od
Tab Amphoterecin B 25mg
Tab Fluconazole 150mg od
Tab Dolo 650 tid

Post Treatment



3 months post treatment obturator was constructed & patient was asked to continue the previous medications. Following that patient came for a regular checkup & healing was uneventful

Bapuji Dental College & Hospital
Davangere, Karnataka, INDIA