

# Non-Invasive Stereolithographic Implant Treatment Of A Severely Resorbed Edentulous Maxilla: A Case Report

INTERNATIONAL SYMPOSIUM  
**OSTEOLOGY  
MONACO**  
MAY 2-4, 2013

Ayşe Sümeyye Akay\*, Volkan Arısan\*\*

\* PhD Student, Med. Dent. Department of Oral Implantology, Faculty of Dentistry, Istanbul University.

\*\* Ass. Prof. Dr. Department of Oral Implantology, Faculty of Dentistry, Istanbul University.

**ISTANBUL UNIVERSITY**  
Faculty of Dentistry  
Department of Oral Implantology



## Abstract

**Objectives:** Application of a stereolithographic (SLA) technique for the non-invasive treatment of a severely resorbed maxilla that conventionally requires a major bone grafting & sinus lifting surgery was presented in this case report.

**Methods:** A 56 year old female patient with a severely resorbed maxilla was referred to the Department Oral Implantology, Faculty of Dentistry, Istanbul University. Iliac and sinus grafting was indicated in previous consultations due to the lack of sufficient bone height. The panoramic radiograph revealed a bone height of 6-8 mm in the anterior maxilla. The residual bone height under the sinuses was also below 1mm. Initially, the patient underwent cone-beam CT imaging by using the existing prosthesis, which was used as a scanning appliance. A total of six implants (8mm length and 3.75mm diameter) were planned and a corresponding SLA template was produced. The implants were inserted in a flapless fashion and left for osseointegration for 4 months.

**Results:** All procedures were uneventful and all implants were clinically osseointegrated. The patient was restored with a metal-ceramic fixed restoration. The follow-up examination after six month revealed normal peri-implant conditions and optimal function. The patient was satisfied because of having avoided a major surgery.

**Conclusions:** In selected cases, SLA techniques may help bypassing major surgical procedures required in the classic treatment approach.

## Introduction

Along with the improvements in implantology, the conventional treatment approaches may not fulfill the expectations of patients and seem to be relatively 'traumatic'. Especially in cases which multiple numbers of fixtures required, and many patients are asked to undergo excessive surgeries with considerable risks and post-operative morbidity. A compromise in the complete understanding of the underlying anatomy and vital structures further complicates the extensions of the surgery when combined with severely horizontal and vertical bone resorption. The use of allogeneic bone grafts inherits the risk of disease transfer and infection whereas autografts leave a second wound with additional patient morbidity. To overcome these aspects, alloplastic materials were used, however they cause a limited healing as compared to allogenic and autogenous resources (1, 2). In the posterior maxilla, sinus lifting surgery has its own limitations and risks and furthermore the overall treatment time is usually over one year due to the slow bone healing (3).

Usually, removable prosthetic restorations are offered for such patients due to the extreme difficulty of matching the positions of multiple implants for a fixed restoration (4).

Stereolithographic surgical techniques enable planning implants in optimum locations, angulations and length before the surgery by using advanced radiological techniques (5, 6). Computer software is used for combining the computed tomography images and the virtual plans within the stereolithographic surgical procedures (5). While giving respect to the prosthetic goals, the clinicians may execute a virtual surgery placing the implants in available bone volume. Thanks to the advanced imaging technologies, clinicians and patients are more likely to facilitate this treatment technique. For instance, the Cone-Beam Computed Tomography (CBCT) is widely used because of its advantages such as low-dose radiation and low-cost when compared with conventional computed tomography (6).

Software applications are being used in order to determine proper implant locations by using radiographic templates. These templates can be prepared either by duplication of an existing prosthesis or by manufacture from a new tooth setup. These radiographic templates are kept inside the mouth while CBCT is being performed and they represent the final prosthetic outline on the navigational 3D images easily. Each technique has its own advantages and disadvantages in term of accuracy, ease of manufacturing and required number of visits (7, 8, 9).

In this case report, application of a stereolithographic technique for the non-invasive treatment of a severely resorbed maxilla that requires a major bone grafting and sinus lifting surgery with reference to two-dimensional radiography was presented.

## Case

A 56 year old female patient with a totally edentulous maxilla was referred to the Department Oral Implantology, Faculty of Dentistry, Istanbul University with complaints of insufficient retention and compromised chewing ability of the prosthesis.

On previous consultations, the patient was regarded unsuitable for dental implant treatment with conventional surgical methods due to the excessive bone resorption and lack of vertical bone height in the maxilla. Implant insertion could only be possible after sinus lifting and iliac grafting. In view of this, guided implant surgery with computer-aided planning was determined. Adequate alveolar bone thickness and attached mucosa width for the flapless surgery was observed (Figure 1) on primary clinical examination by determining with a surgical clipper.

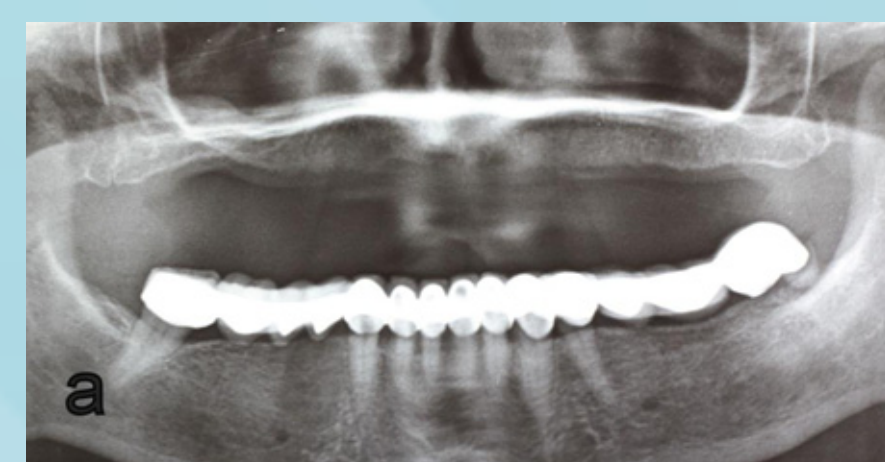


Figure 1: a) Preoperative panoramic radiography. b) Intraoral view on clinical examination. c) The existing prosthesis.

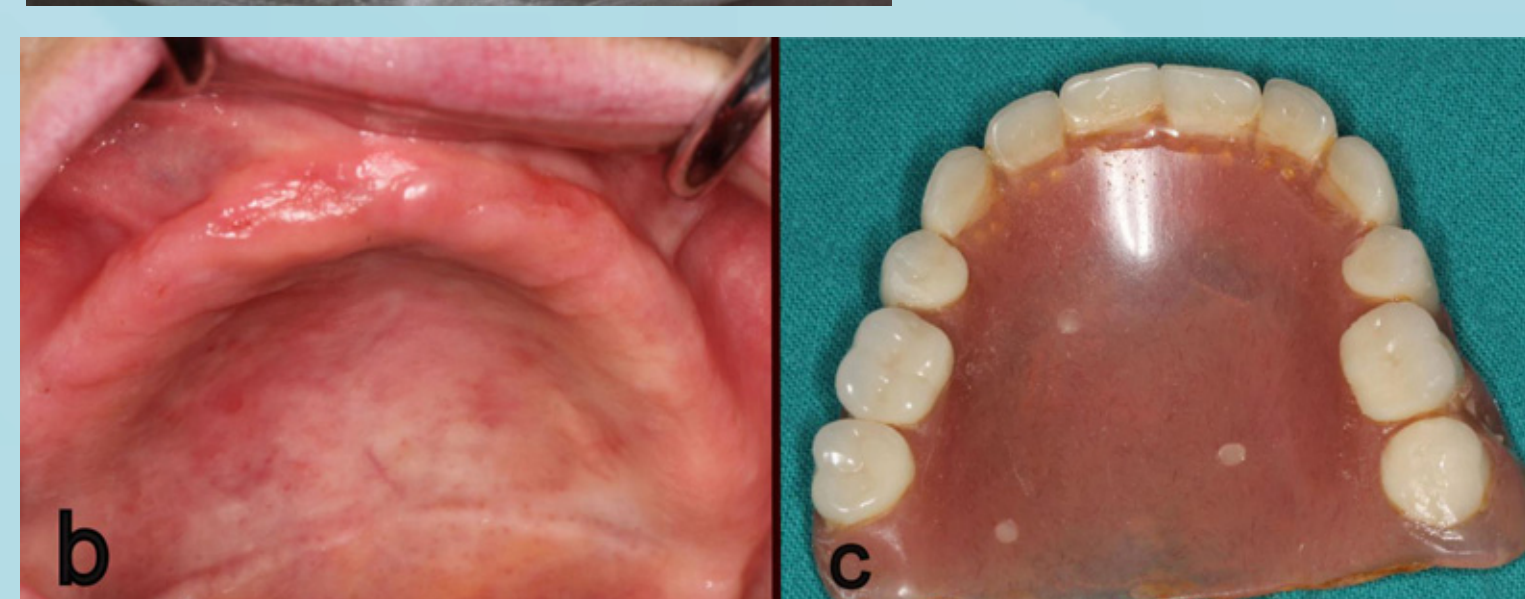


Figure 2: a) Stereolithographic guide. b) Obtaining of the bite-registration.

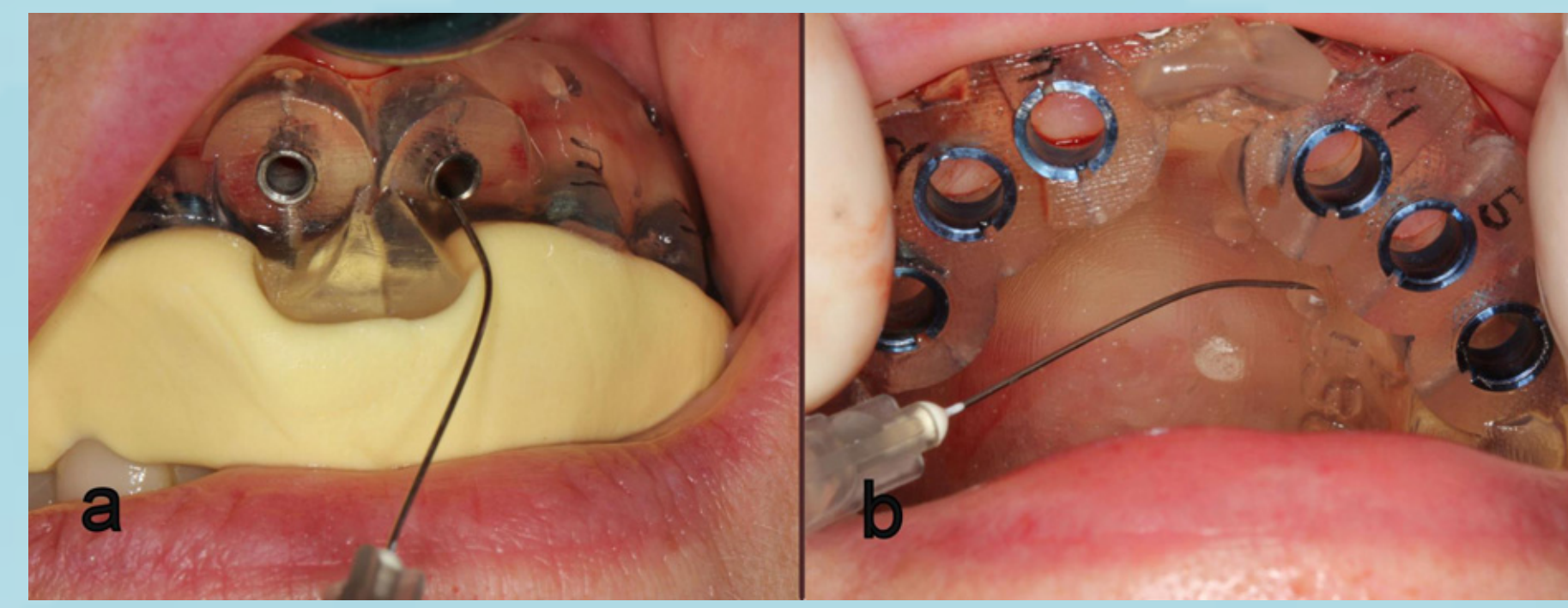


Figure 3: Injection of local infiltration anesthesia.

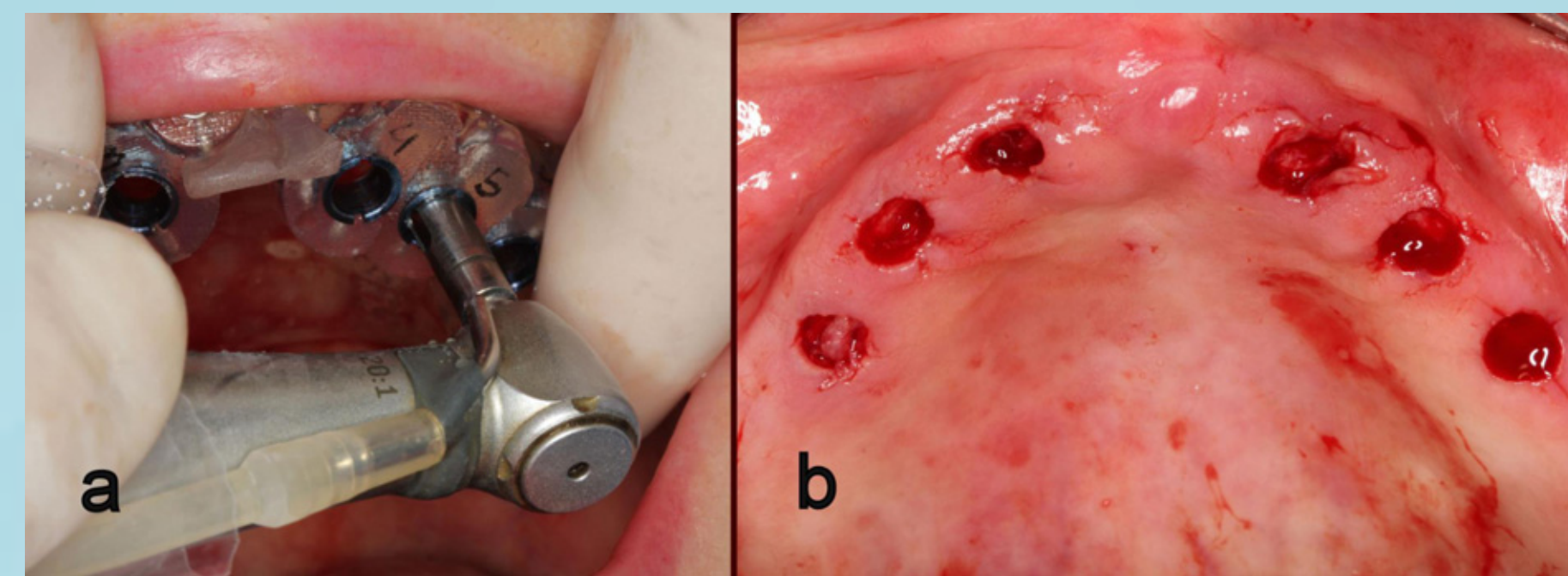


Figure 4: Flap elevation with the soft tissue punches.

Having acceptable esthetic characteristics, the existing prosthesis was used as radiographic template. After relining, radiopaque markers (Radio-opaque composite, Coltene, Switzerland) were placed onto the prosthesis base with three different axes in order to intersect the template with the proper position inside the mouth. Then the patient underwent double-scan protocol via a CBCT device. First, the patient was scanned while the denture was inside the mouth. Second, just the denture was scanned in the same axis. The data transferred to the software in DICOM format. Then, the radiographic template and edentulous jaw intersected by reference of the radiopaque markers. The axial, sagittal and frontal sections of implant recipient areas were evaluated on the software. Gray density was measured on the CBCT, a mean of 386 HU. Short-length implants were evenly distributed in the region between the maxillary sinuses giving respect to the proper prosthetic alignment. Then, the planning file was sent to the manufacturer for the production of stereolithographic guide (Materialise Dental, Belgium).

**Surgical stage:** Bite registration was obtained preoperatively while the stereolithographic guide was at the centric occlusion and exact positioning of the SLA guide was ensured. After sterilizing with povidon iodine, the guide was placed inside the mouth with the guidance of the bite registration, before the surgery (Figure 2). Local infiltration anesthesia was injected in the corresponding area of the fixation screws (Figure 3). The soft tissue punches were used in accordance with manufacturer's instructions (Figure 4). Then, the fixation screws were placed through the grooves in the guide. Finally, the cortical perforator drills and shaping drills were used respectively, and the osteotomy was completed (Figure 5).

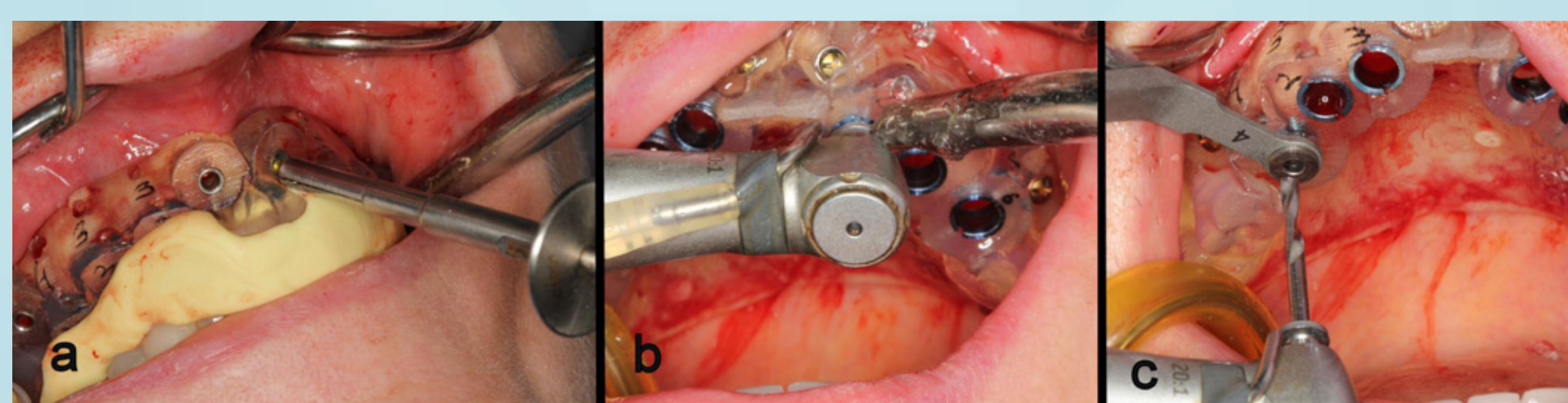


Figure 5: a) Fixation of the guide by using fixation screws. b) Performing of the cortical perforator drills. c,d,e) Osteotomy procedures, the use of sequential drills.

Implants were placed with a tripod fashion on the surgical guide to obviate the compression forces -produced by excessive stress-. Initially, no. 14, 24, 22 implants were inserted, respectively. Later, one implant mount removed and one another implant was inserted one by one (Figure 6). After the procedure was completed in this way, the guide was removed and perimucosal screws were screwed on (Figure 7). Implants inserted with mean of 40 N/cm insertion torque value.

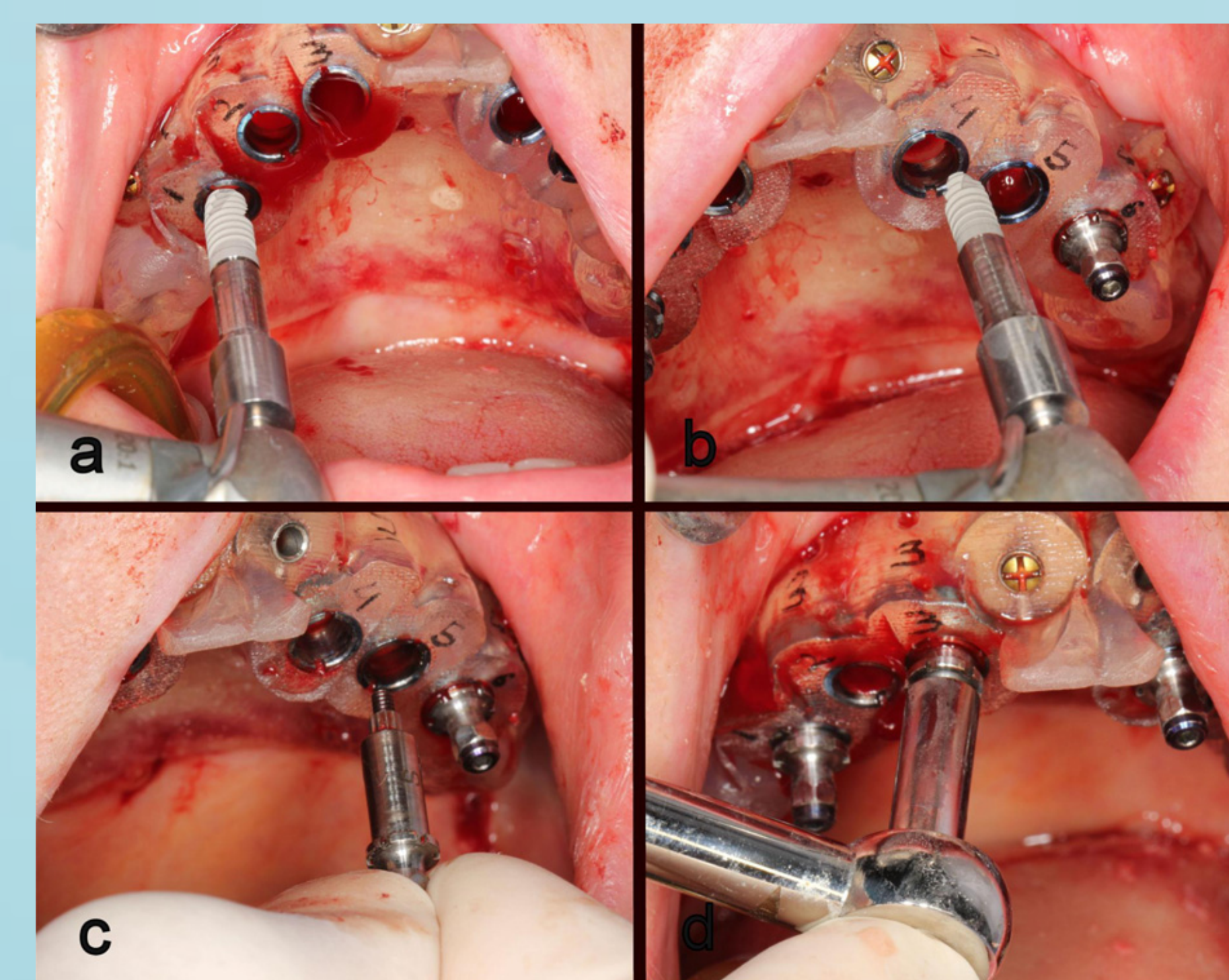


Figure 6: a) Insertion of no.14 implant. b) Insertion of no.24 and no.22 implants. c) Removing of the no.22 implant mount. d) Placing of the implants tripodally.

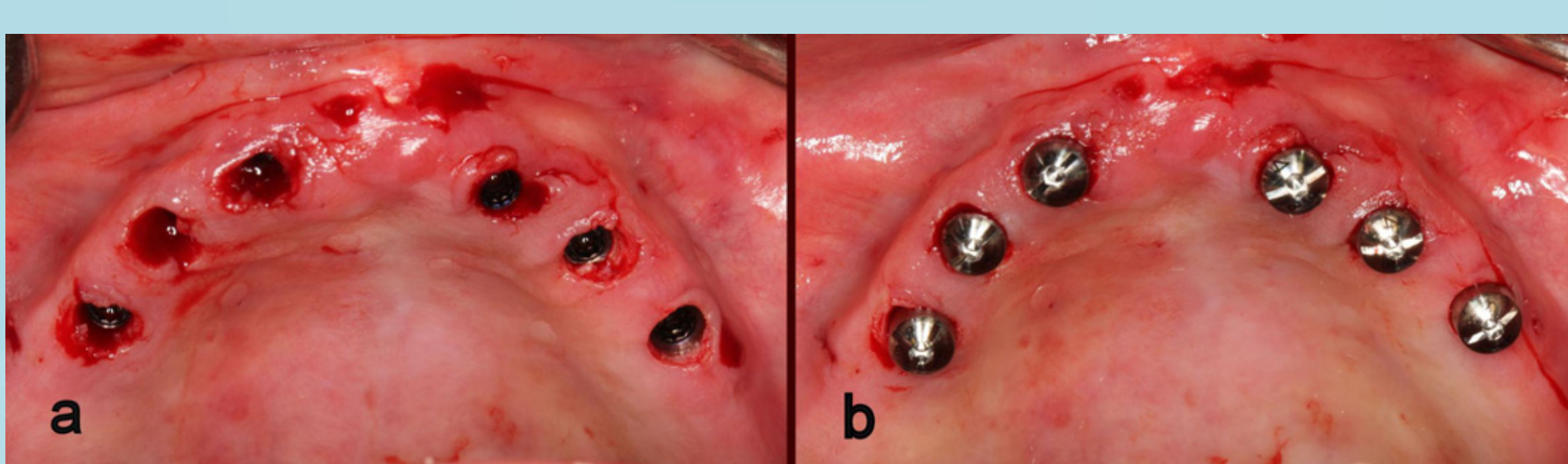


Figure 7: Removing the guide away and screwing the perimucosal healing caps on.

## Results

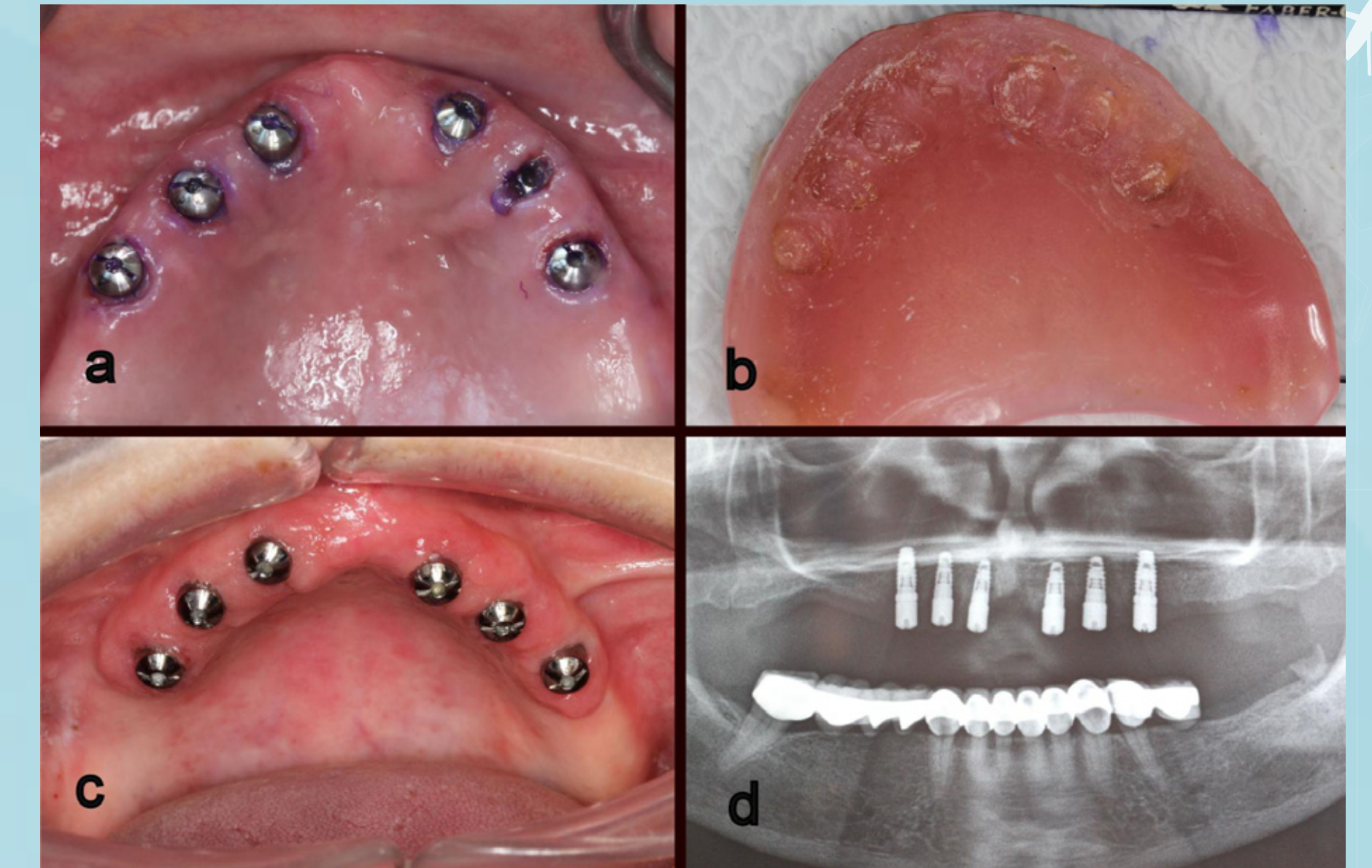


Figure 8: a) Replacing the no.23 healing cap with the proper one. b) Excluding the existing prosthesis from any contact with implants and surrounding mucosa. c) Intraoral view after the osseointegration period. d) Panoramic view after the osseointegration period.

Surgery was completed in 38 minutes and all implants were placed as planned in the software. The patient consumed two analgesic tablets (Parol, IMSAN, Istanbul, Turkey) during the post-operative period. No persistent anesthetic or paresthetic area was observed. Because of the lack of incision and suture, soft tissue recovery was considerably fast. Perimucosal healing cap in No 23 which was covered by soft tissue was replaced with the proper one. After relining and excluding any contact with implants and surrounding mucosa, the existing prosthesis was used as interim prosthesis during the osseointegration period. After the healing period of 4 months, all implants were radiographically examined and found clinically osseointegrated (Figure 8).

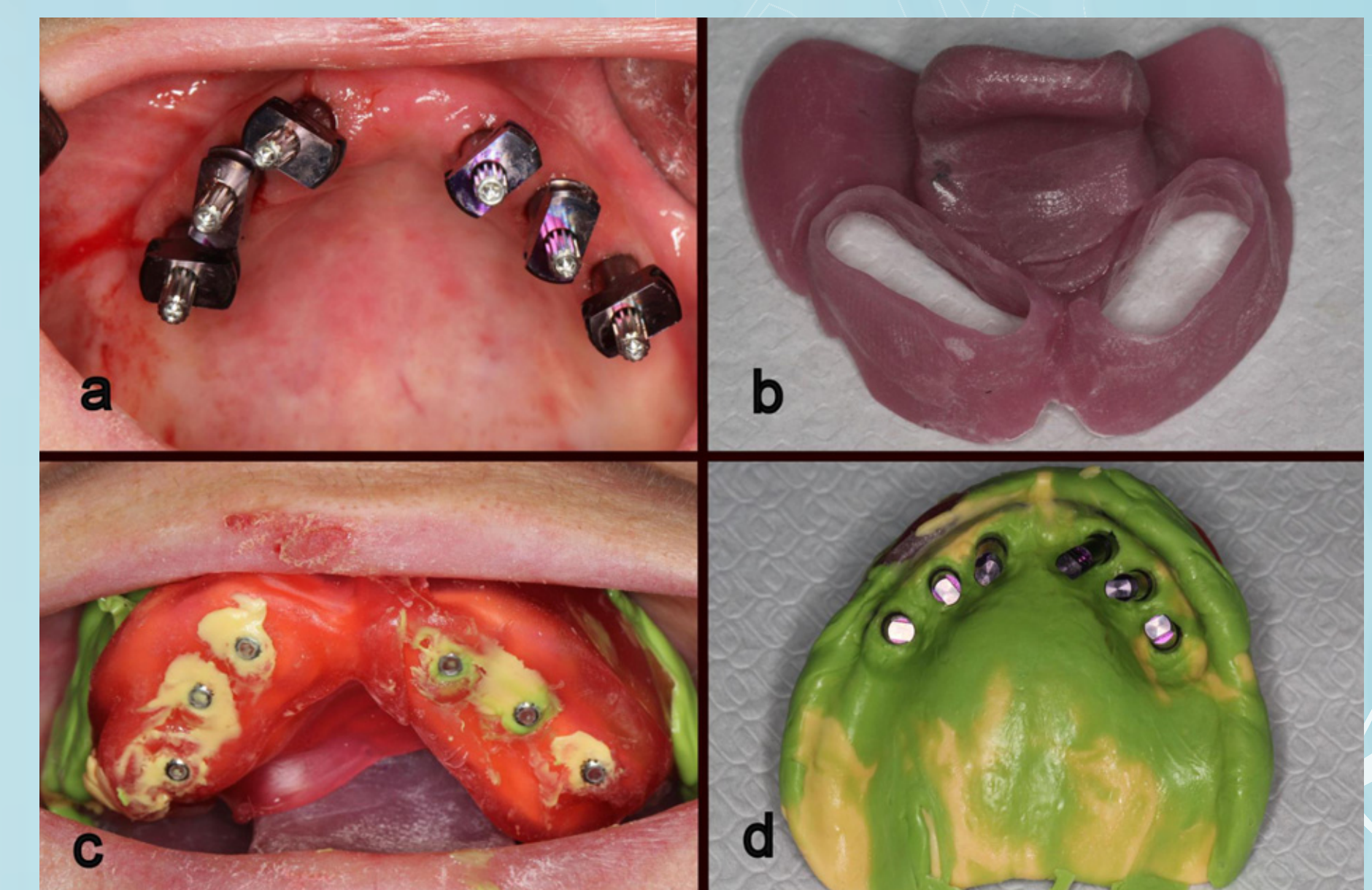


Figure 9: Obtaining of open-tray impression by using the individual impression tray.

Open-tray impression was obtained using an individual impression tray (Figure 9). A one piece metal-fused-ceramic work was planned with two distal cantilevers to provide a full arch occlusion. Metal-ceramic fixed prosthetic procedures were executed and completed uneventfully as the positions of the implants were of no constraining (Figure 10).

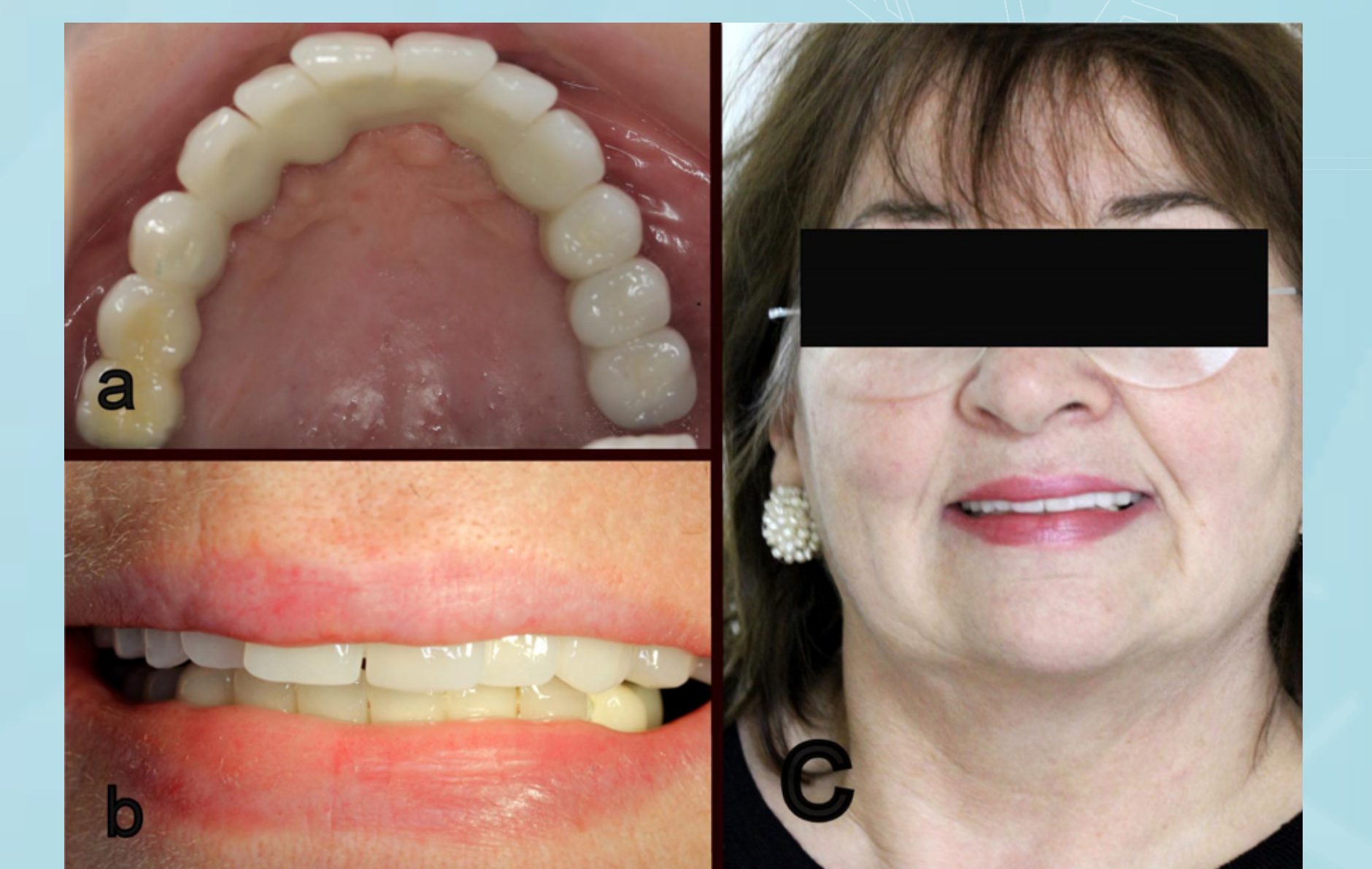

Figure 10: a, b, c) The views of the final restoration.

## Conclusions

In the classic treatment approach, abundance of the alveolar bone volume is a prerequisite when a fixed prosthesis is considered for a totally edentulous jaw. With the help of the tomography based stereolithographic techniques, major surgical procedures (a bi-lateral sinus lifting procedure and an autogenous bone transfer for the presented case) can be avoided in selected cases.

## References

1. Arisan V, Ozdemir T, Anil A, Jansen JA, Ozer K. Injectable calcium phosphate cement as a bone-graft material around peri-implant dehiscence defects: a dog study. *Int J Oral Maxillofac Implants.* 2008 Nov-Dec;23(6):1053-62.
2. Arisan V, Anil A, Wolke JG, Ozer K. The effect of injectable calcium phosphate cement on bone anchorage of titanium implants: an experimental feasibility study in dogs. *Int J Oral Maxillofac Surg.* 2010 May; 39(5):463-8.
3. Karabuda C, Arisan V, Ozyuvaci H. Effects of sinus membrane perforations on the success of dental implants placed in the augmented sinus. *J Periodontol.* 2006 Dec;77(12):1991-7.
4. Arisan V, Karabuda CZ, Mumcu E, Ozdemir T. Implant positioning errors in freehand and computer-aided placement methods: a single-blind clinical comparative study. *Int J Oral Maxillofac Implants.* 2013 Jan-Feb;28(1):190-204.
5. Rosenfeld, A.L., Mandelaris, G.A. & Tardieu, P.B. Prosthetically directed implant placement using computer software to ensure precise placement and predictable prosthetic outcomes. Part I: diagnostics, imaging, and collaborative accountability. *International Journal of Periodontics and Restorative Dentistry.* 2006; 26: 215-221.
6. Arisan V, Karabuda ZC, Avsever H, Ozdemir T. Conventional Multi-Slice Computed Tomography (CT) and Cone-Beam CT (CBCT) for Computer-Assisted Implant Placement. Part I: Relationship of Radiographic Gray Density and Implant Stability. *Clin Implant Dent Relat Res.* 2012 Jan 17. doi: 10.1111/j.1708-8208.2011.00436.x.
7. Arisan V, Karabuda ZC, Ozdemir T. Accuracy of two stereolithographic guide systems for computer-aided implant placement: a computed tomography-based clinical comparative study. *J Periodontol* 2010; 81:43-51.
8. Basten CH. The use of radiopaque templates for predictable implant placement. *Quintessence Int.* 1995 Sep;26(9):609-12.
9. Zahran MH, Fenton A. A radiopaque implant template for partially edentulous patients. *J Prosthet Dent.* 2010 Jun;103(6):390-2.

**Correspondance:** Ass. Prof. Dr. Volkan Arısan, Department of Oral Implantology, Faculty of Dentistry, Istanbul University, 34390, Capa, Istanbul, Turkey [varisan@istanbul.edu.tr](mailto:varisan@istanbul.edu.tr)