

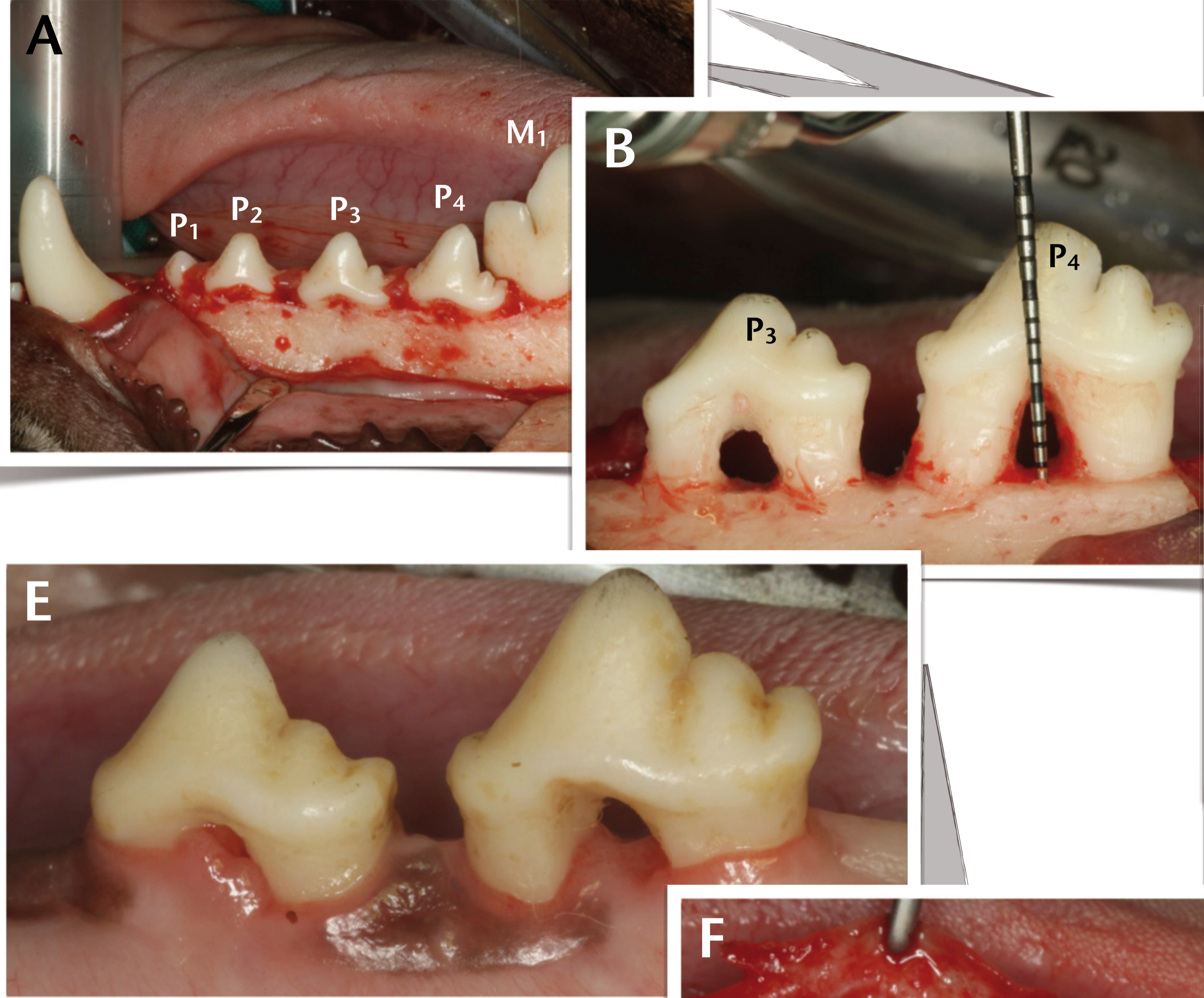


Chronified critical-size supra-alveolar periodontal defects: model description and characteristics for the study of periodontal regeneration by means of cell therapy in the beagle dog.

Luca Ferrantino¹, Ignacio Sanz Martin¹, Nerea Sánchez Pérez¹, Fernando Luengo¹, Fernando Muñoz², Mariano Sanz¹.
1 Faculty of dentistry, Universidad Complutense de Madrid - Spain; 2 Faculty of veterinary, Universidade de Santiago de Compostela - Spain.

1 INTRODUCTION

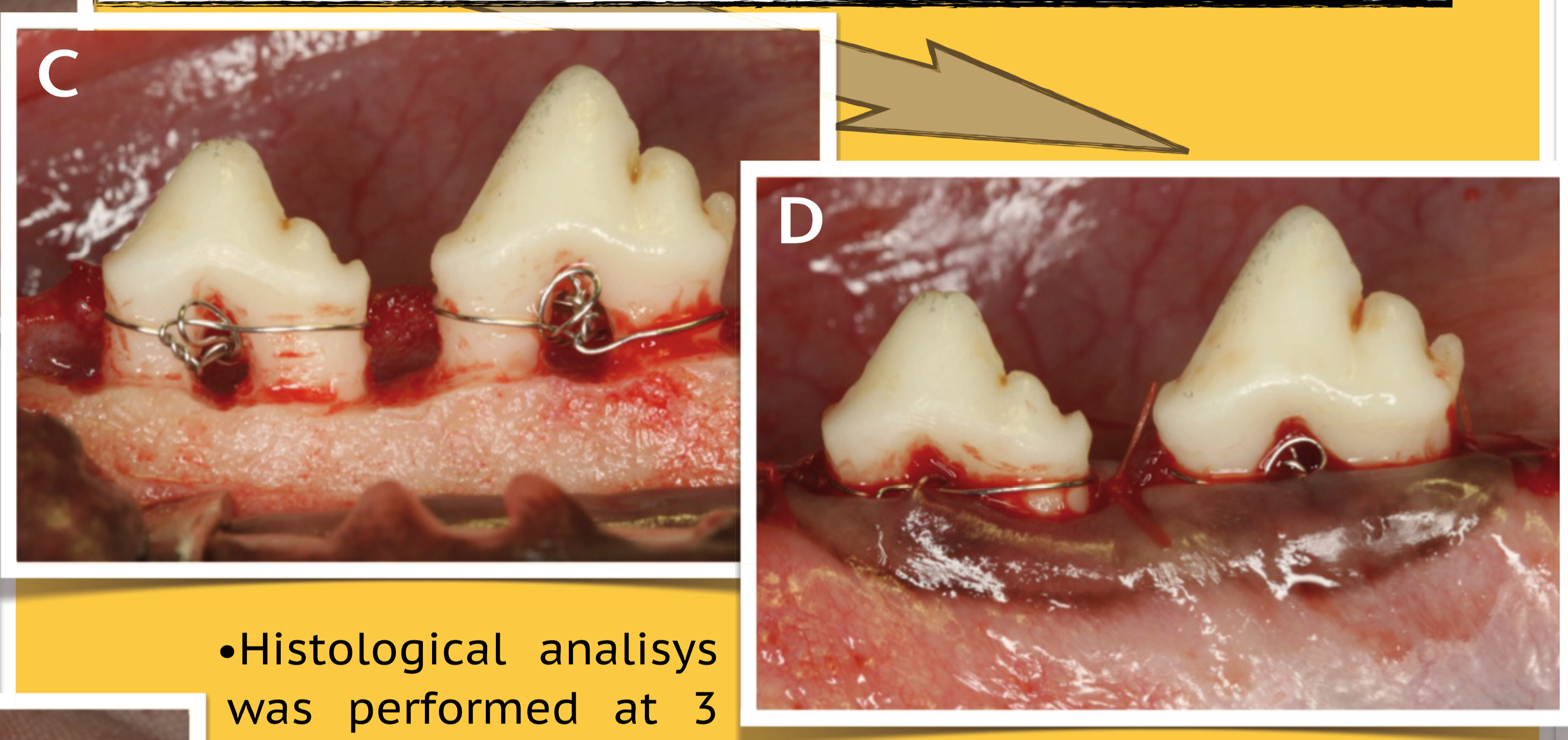
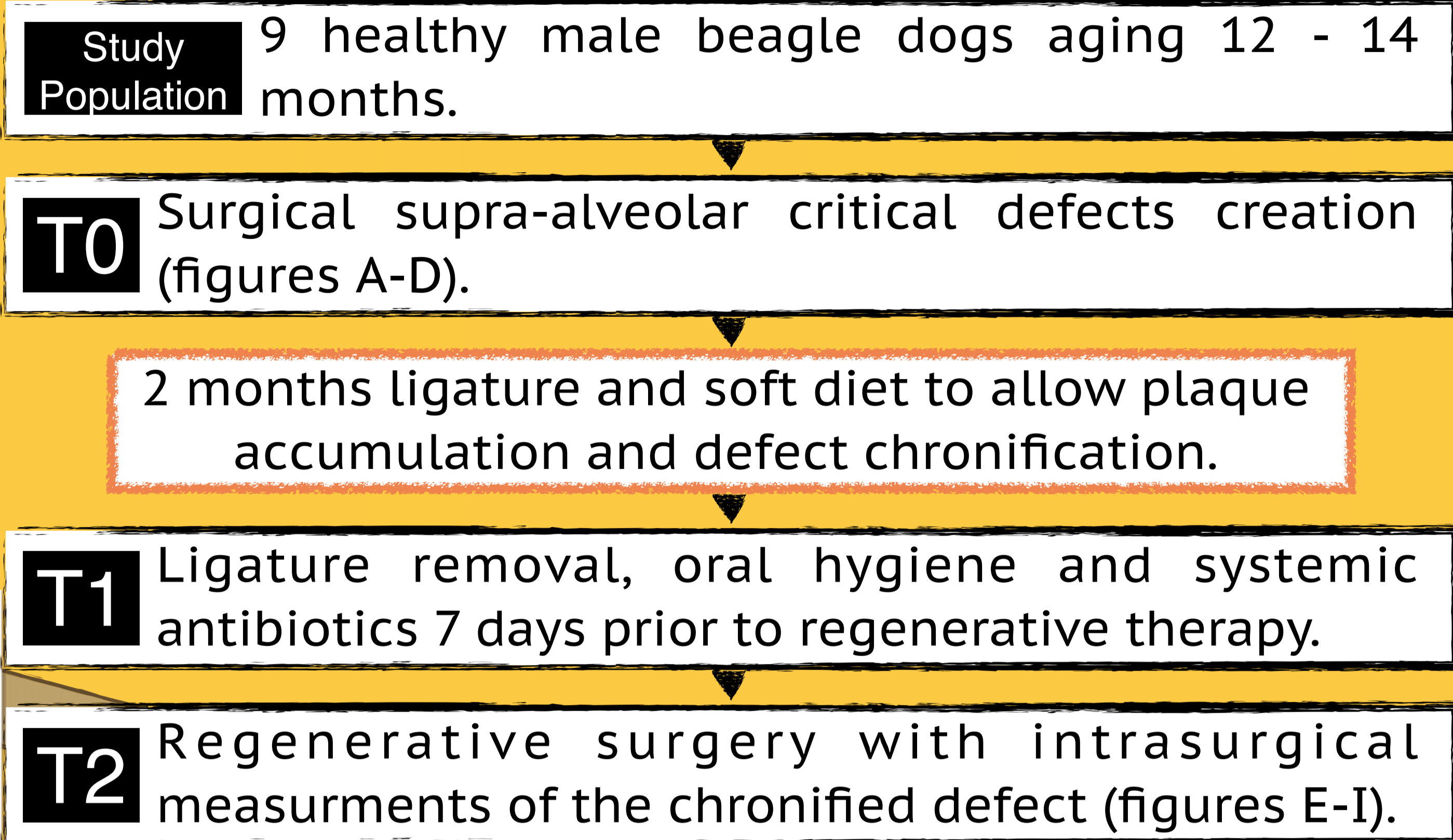
- Critical-size defect models have been developed to assess the biologic potential, efficacy and safety of new regenerative approaches prior to their use in humans. The objective of this report is to describe the animal model used to study the regenerative potential of periodontal mesenchymal cells.



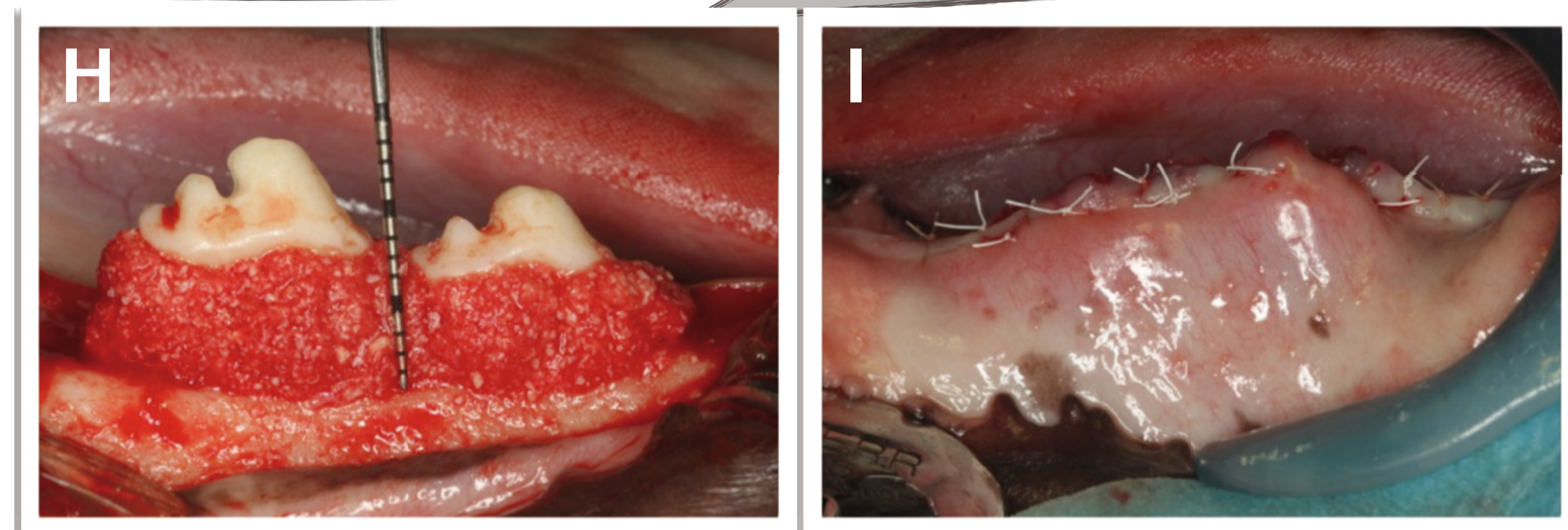
Figures A-D Surgical defect creation
(A) Surgical site after full thickness flap elevation. (B) P₁, P₂ and M₁ were extracted and circumferential horizontal defects were surgically created around P₃ and P₄. Defects were standardized to have 4 mm from the bone to the furcation fornix and 6 mm from bone to the CEJ mesial and distal. (C) Ligature fixation. (D) Suturing.

Figure E-I Regenerative therapy
(E) Clinical aspect after 2 months. (F) Defects were degranulated and periosteal incision were performed to allow coronal displacement of the flap. (G) Graft material (Bioss-Collagen®) with canine periodontal mesenchymal cells. (H) Graft material positioned. (I) Primary intention wound closure.

2 MATERIALS AND METHODS




- Histological analysis was performed at 3 months.
- Regeneration was performed with a xenogeneic bone substitute (Bioss-Collagen®) with or without canine periodontal mesenchymal cells (Figure G).



3 RESULTS AND CONCLUSIONS

- As showed in the histogram and table, periodontal defects remained with evident loss of attachment and furcation exposure after chronification (figure E). There was no statistically significant differences in the parameters analyzed (CEJ-AB, F-AB) between T0 and T2 (Paired t test, p>0,05).

	CEJ - AB	F-AB
Defect creation T0	5,19 (± 0,38)	3,65 (± 0,47)
After chronification T2	4,64 (± 2,8)	3,99 (± 0,67)
Distance in mm		mean (±SD)
CEJ = Cemento Enamel Junction; AB = Alveolar Bone crest; F = Furcation Fornix		



Conclusions : The chronified supra-alveolar periodontal defect induced in the beagle dog closely resembles challenging periodontal defects in humans and proved to be a valid model for the study of periodontal regeneration with cell therapy.