

# Differential diagnosis of a cervical cystic neoplasia



## Introduction

In differential diagnosis of cystic neoplasia of the neck cystic degenerated lymph nodes or lymphomas have to be considered. Genuine branchiogenic carcinoma, which means carcinoma in lateral cysts of the neck, are rare and it has to be assumed that in most cases they are cystic metastases of squamous cell carcinoma.

## Case presentation

A 51 year old patient presented at our hospital with a 4-week history of a progressive swelling postero-inferior to the right mandibular angle. There were no pathological intraoral and nasopharyngoscopic findings. Ultrasound of the neck showed a well defined, smoothly shaped and homogenous cystic mass without hilus sign, 4cm in diameter, attached to another structure, 2cm in diameter, with visualised hilus (fig. 1 and 2). A computed tomography scan of the head and neck revealed a 40mm hypodense mass in Level IIa (according to the American Society for Head and Neck Surgery), most likely a central necrotic lymph node metastasis, close to another 15mm hypodense structure, most likely an enlarged lymph node (fig. 3 and 4). An  $^{18}\text{F}$ FDG PET-CT scan revealed a rounded, metabolic active mass with central hypodensity in the right carotid triangle, most likely a lateral cyst of the neck, differential diagnosis lymphangioma (fig. 5). A bilateral slightly increased FDG-uptake in Waldeyer's Ring was interpreted as of inflammatory origin (fig. 6). There was no clinical or radiographic sign for any primary cancer. The mass was excised under general anesthesia.

## Result

Microscopic examination revealed a branchiogenic carcinoma, resp. a squamous carcinoma of the neck developed in a lateral cyst of the neck, with an adherent inflammatory modified lymph node. We applied a functional neck dissection on the right side and a bilateral tonsillectomy. No further pathological lymph nodes were identified. The left tonsil contained no abnormalities whereas on the right side a 2,2cm squamous cell carcinoma infiltrated almost the whole tonsil (pT2, pN2a, M0). Subsequently we applied a functional neck dissection on the left side without pathological lymph nodes. The patient declined an adjuvant radio- and chemotherapy.

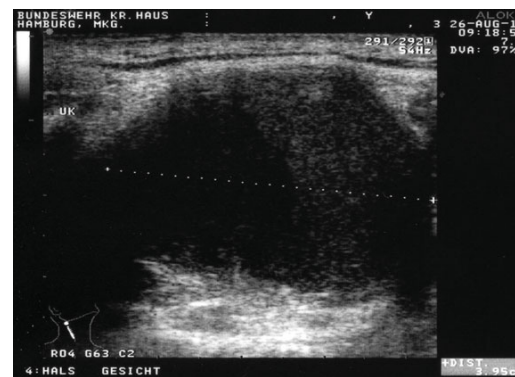


Fig. 1: Ultrasound right neck, cranial

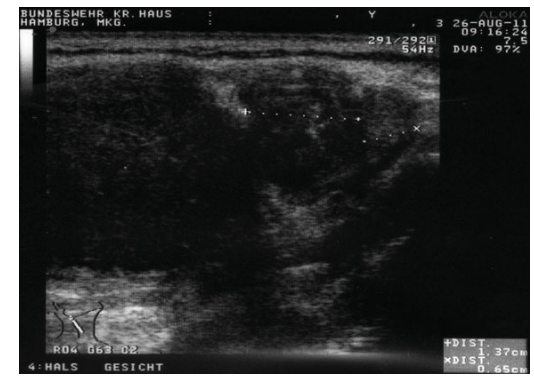


Fig. 2: Ultrasound right neck, caudal

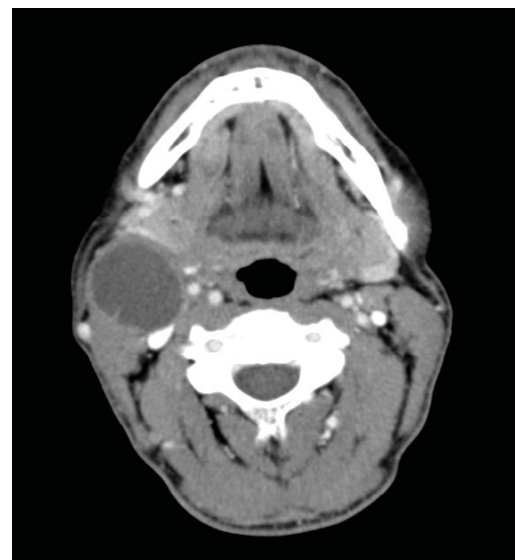


Fig. 3: CT scan, neck, axial

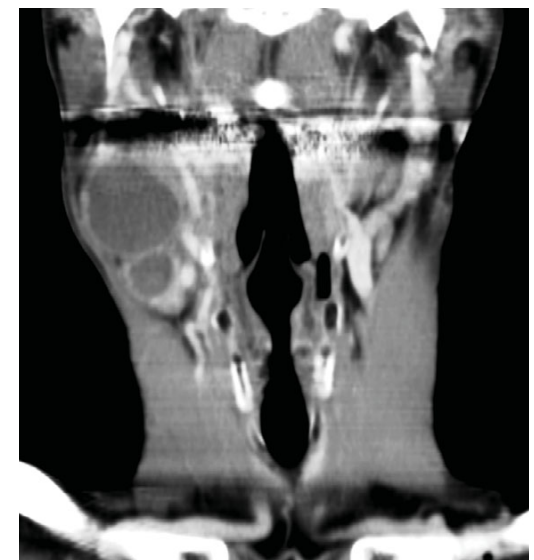
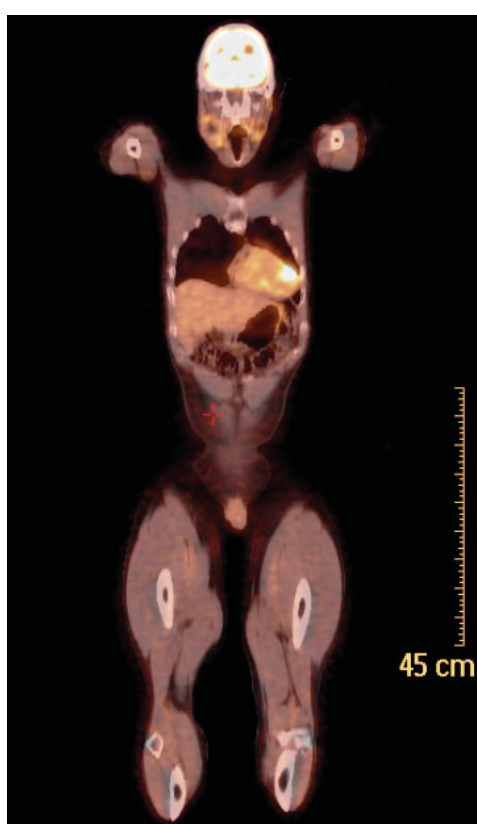
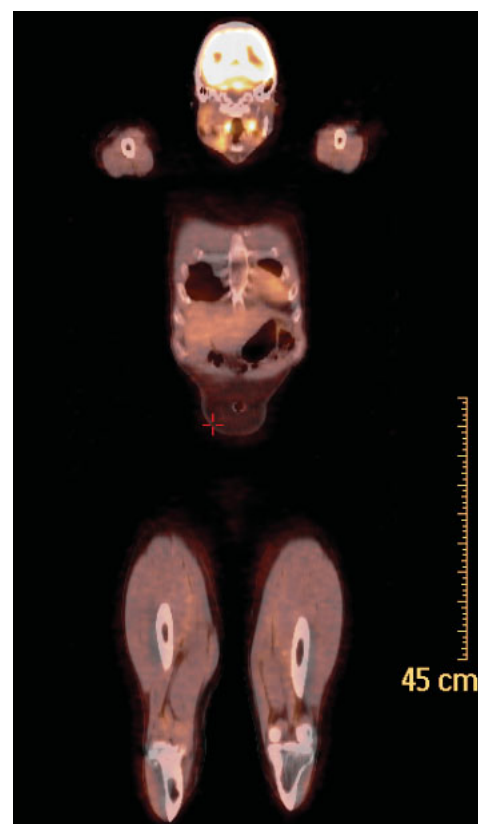Fig. 4: CT scan, neck, coronal

Fig. 5:  $^{18}\text{F}$ FDG-PET-CT scan,, coronal, sectional plane cervical massFig. 6:  $^{18}\text{F}$ FDG-PET-CT scan,, coronal, sectional plane tonsil

## Discussion and Conclusion

Differential diagnostics of cystic cervical neoplasia is sometimes difficult. On assumption of a CUP (Cancer of unknown primary) we performed a PET-CT scan, which is clearly superior to single PET, CT or MRI [1]. Despite the size of 2,2cm the primary cancer could not clearly be determined. Therefore an early excision of suspicious cystic masses of the neck is recommended [2]. First histologic examination revealed a carcinoma in a lateral neck cyst, a branchiogenic carcinoma, which would be a rarity considering the criteria of Martin et al. [3]. Older assumptions are that lateral cervical cysts already evolve during embryonal development and they manifest in any age, a newer approach is that they develop through cystic transformation of cervical lymph nodes as a result of migration of lymphogenic epithelial cells after tonsillitis [4]. This could have been a reason for the FDG-uptake in PET-CT. Although it is the way to explain the metastasis method of the tonsil cancer in this case. Proof was given through diagnostic tonsillectomy, which is recommended for cancer of unknown primary of the head and neck in the guidelines of the German Society for Hematology and Oncology but not in so-called branchiogenic carcinoma [5]. We subscribe to the opinion that every cystic neoplasia of the neck in people exceeding 40 years of age has to be treated as metastasis of squamous cell carcinoma unless there is evidence to the contrary [6]. It has still to be clarified whether carcinoma in lateral neck cyst is a unique entity.

## Literature

- Keller, F., Psychogios, G., Linke, R., Lell, M., Kuwert, T., Iro, H., Zenk, J., Carcinoma of unknown primary in the head and neck: comparison between positron emission tomography (PET) and PET/CT. *Head Neck*, 2010. 33(11): p. 1569-75.
- Hossfeld, D.K., C. Wittekind, Metastasen bei unbekanntem Primärtumor: Das CUP-Syndrom. *Dtsch Arztebl*, 2005. 102(13): p. 904-907.
- Martin, H., Morfit, H.M., Ehrlich, H., The case for branchiogenic cancer (malignant branchioma). *Ann Surg*, 1950. 132(5): p. 867-87.
- Abbruzzese, J.L., Abbruzzese, M. C., Hess, K. R., Raber, M. N., Lenzi, R., Frost, P., Unknown primary carcinoma: natural history and prognostic factors in 657 consecutive patients. *J Clin Oncol*, 1994. 12(6): p. 1272-80.
- Hübner, G., Bokemeyer, C., CUP-Syndrom – Tumorerkrankung mit unbekanntem Primärtumor. Leitlinie CUP-Syndrom der Deutschen Gesellschaft für Hämatologie und Onkologie. 2005.
- Gourin, C.G., Johnson, J.T., Incidence of unsuspected metastases in lateral cervical cysts. *Laryngoscope*, 2000. 110(10 Pt 1): p. 1637-41.