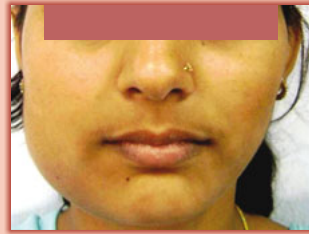

ODONTOGENIC CYST OR TUMOUR?

(CALCIFYING CYSTIC ODONTOGENIC TUMOUR Vs ODONTOAMELOBLASTOMA)

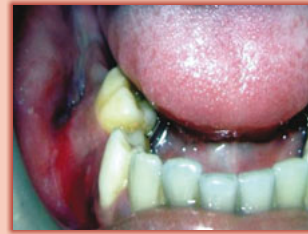THE DIAGNOSTIC DILEMMA

CLINICAL PRESENTATION

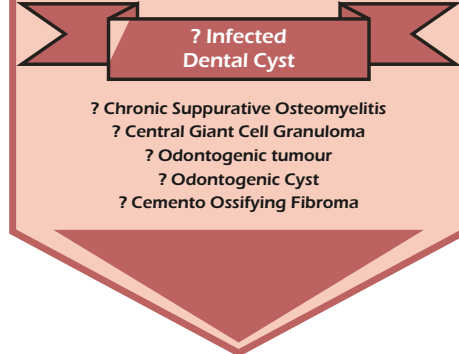


Extra-Oral

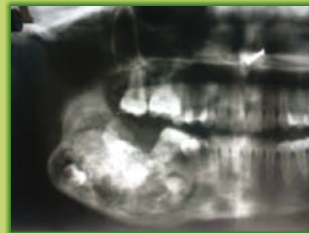15-year-old female presented with painful swelling of the right lower back region of the jaw
Swelling developed following trauma seven years ago and associated with increase in size and intermittent dull-aching pain since three to four years
Extra-orally, an oval swelling of bony-hard consistency, measuring 5x7 sq. cm., observed in the right body of the mandible, extending antero-posteriorly from angle of mandible to angle of mouth, inferiorly up to lower border of the mandible, and superiorly to the level of tragus
Corresponding intra-oral swelling obliterating right lower buccal vestibule
Pus draining sinus opening at the buccal vestibule posterior to 46 and at the alveolar mucosa of 44; Teeth 45, 47 missing; Lingually inclined 46



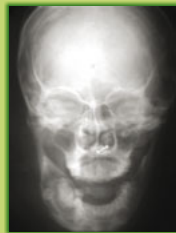Intra-Oral



RADIOLOGICAL FEATURES

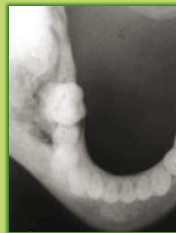

OPG

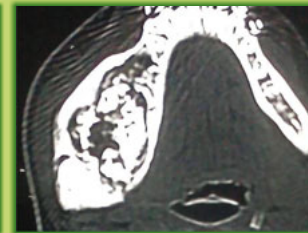


PA View

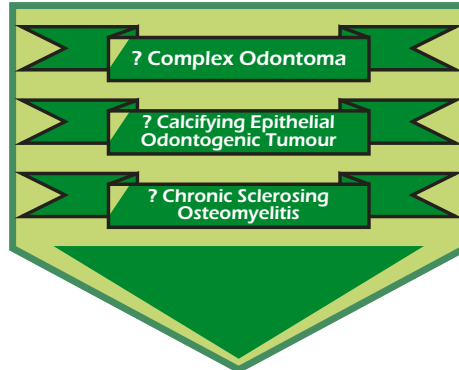
Mixed radiopaque-radiolucent lesion on the right side of the mandible, extending from tooth 44 to the ramus of mandible
Scattered masses of calcification throughout the radiolucency
Tooth 47 displaced to the inferior border of mandible
Tooth 48 absent
Lingual and buccal cortical plate expansion



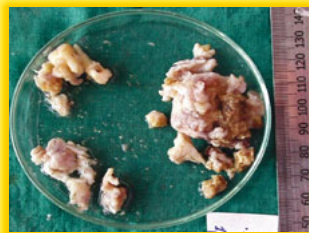Occlusal



CT Scan



GROSSING/PROCESSING/STAINING PARTICULARS

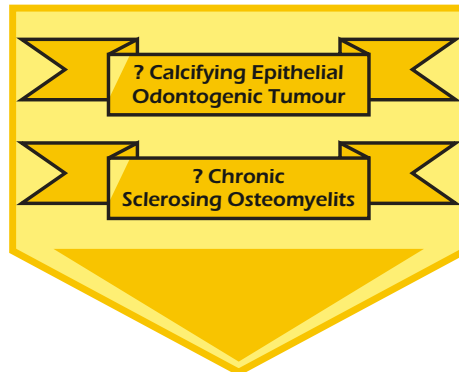


Biopsy Specimen

Two teeth; Four bits of soft tissue; Ten bits of mixed tissue
Creamish white in colour; Soft to bony hard in consistency; Irregular surface
Radiological examination revealed the presence of calcified tissue in the specimens
Specimens subjected to decalcification followed by routine tissue processing
Hematoxylin and Eosin staining; Van Gieson staining to assess the ghost cells



Radiograph



HISTOPATHOLOGY

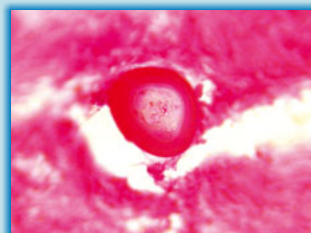


Fig. 1

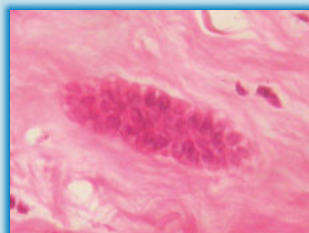

Fig. 2

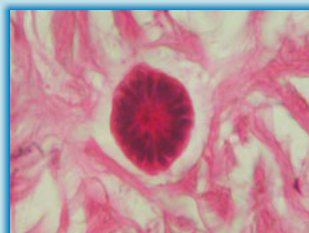


Fig. 3

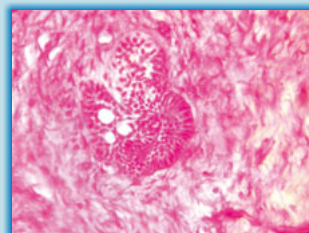


Fig. 4

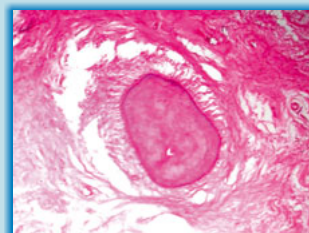


Fig. 5

Dense fibrous connective tissue stroma with numerous calcifications resembling 'Liesegang rings' (Fig. 1) and areas of odontogenic epithelial cells, led to the diagnosis of calcifying epithelial odontogenic tumor (CEOT)

Serial sections prepared to identify more representative areas revealed:

Odontogenic cells arranged in the form of nests (Fig. 2), cords, rosettes (Fig. 3) and odontogenic follicles lined by ameloblast-like cells with central stellate reticulum-like cells and cystic spaces (Fig. 4)

Calcified structures simulating dentinoid (Fig. 5), enamel spaces, ectomesenchymal tissue, and globular cementum-like masses (Fig. 6)

Dentinoid, enamel spaces, and primitive connective tissue gave the appearance of complex composite odontoma (Fig. 7)

Numerous ghost cells (Fig. 8) with a central nuclear halo associated with dentinoid

Staining with van Gieson stain confirmed the presence of ghost cells by staining them yellow (Fig. 9) in contrast to the red colour of the dentinoid

Cystic lining consisting of two to three layers of odontogenic cells (Fig. 10), with associated ghost cells and dentinoid

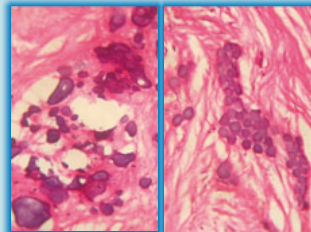


Fig. 6

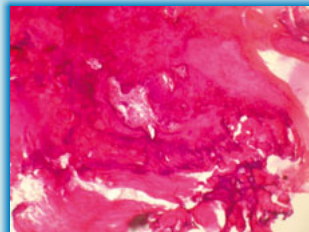


Fig. 7

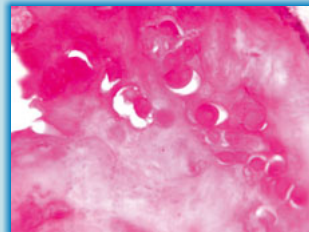


Fig. 8

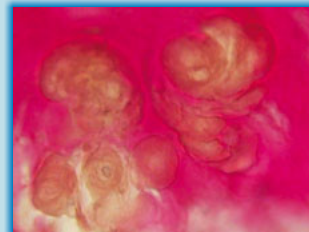

Fig. 9

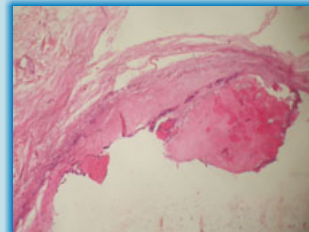
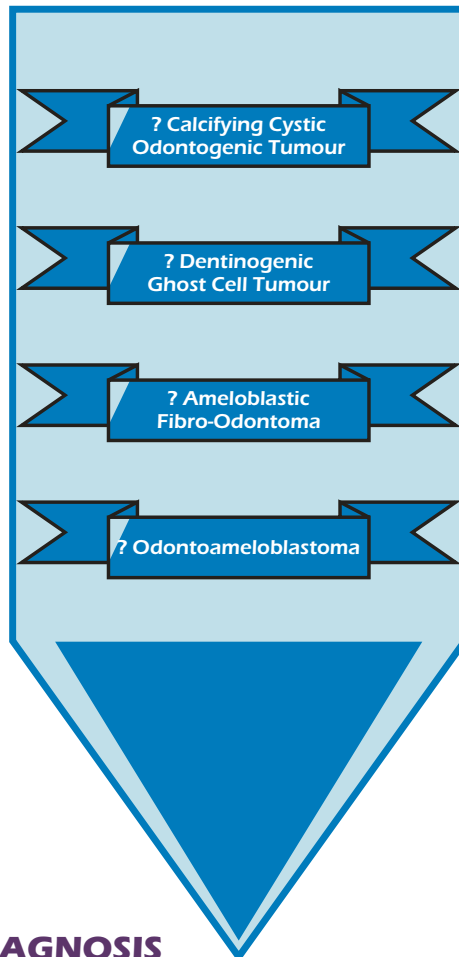


Fig. 10



FINAL DIAGNOSIS <<< HISTOLOGICAL DIFFERENTIAL DIAGNOSIS

CALCIFYING CYSTIC ODONTOGENIC TUMOUR WITH ODONTOAMELOBLASTOMA

CCOT is a probable candidate **except** for the absence of odontogenic epithelial lining, which could be explained by the probable conversion of odontogenic epithelium into ghost cells or dentinoid.

OA is a probable candidate **except** for the presence of a cystic lining, which could be accepted if the possibility of a hybrid of OA and an odontogenic cyst (dentigerous cyst, CCOT) is considered. Dentigerous cyst does not show ghost cells or dentinoid and is thus ruled out.

REFERENCES
1. Chindasombatcharoen J, et al. Calcifying cystic odontogenic tumor associated with other lesions: case report with cone-beam computed tomography findings. Oral Surg Oral Med Oral Pathol Oral Radiol 2012; 113(3):414-20
2. Peron JM, Hardy H. Mixed odontogenic tumours. Rev Stomatol Chir Maxillofac 2009; 110(4):212-20
3. Mosqueda-Taylor A, et al. Odontoameloblastoma. Clinicopathologic study of three cases and critical review of the literature. Oral Oncol 2002; 38(8):800-5

AGAINST	FOR	Histological DD
Absence of ameloblast-like and stellate reticulum-like cells in the epithelial lining	Presence of definitive Cystic Lining; Ghost Cells; ameloblastomatous follicles; and odontome-like areas	CALCIFYING CYSTIC ODONTOGENIC TUMOUR (CCOT)
Presence of cystic lining and odontome-like areas	Presence of ameloblastomatous follicles; dentinoid; and ghost cells	DENTINOGENIC GHOST CELL TUMOUR
Presence of ameloblastomatous follicles and mature connective tissue stroma	Presence of cords and nests of odontogenic epithelium, odontoma-like areas	AMELOBLASTIC FIBRO-ODONTOMA
Presence of cystic lining	Presence of unequivocal ameloblastoma; mature stroma; odontome-like areas	ODONTOAMELOBLASTOMA (OA)