

# Oral Squamous Cell Carcinoma – one case, one argument to support PIPCO

<sup>1</sup>Bessa\*, B.D.; <sup>2</sup>Soares, I.; <sup>2</sup>Paula, A.L.; <sup>3</sup>Pacheco, J.; <sup>4</sup>Monteiro, L.



1 – Oral Medicine and Oral Pathology Post-graduated Student (ISCSN); Dentist, Ms.; PIPCO Collaborator

2 – Oral Medicine and Oral Pathology Post-graduated Student (ISCSN); Dentist Ms.

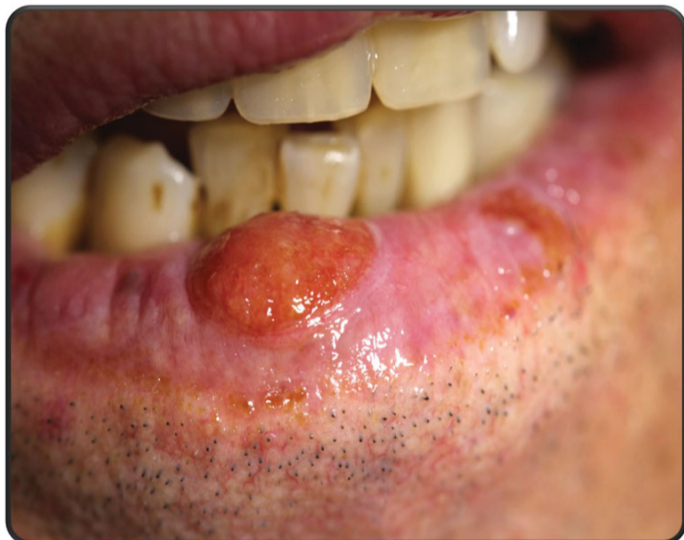3 – Oral Surgery and Oral Medicine Department, ISCSN, Associated Teacher, Post-Graduation Collaborator; Physician PhD.

4 – Oral Surgery and Oral Medicine Department, ISCSN, Associated Teacher; Post-Graduation Coordinator; Dentist, PhD.

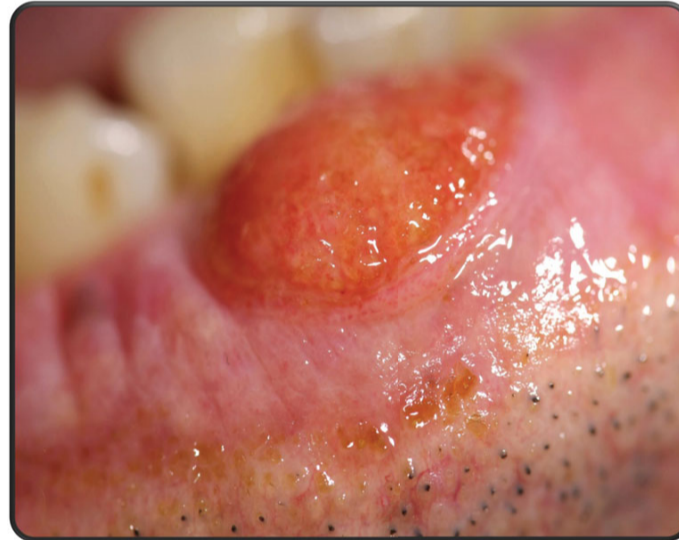


## Clinical Case

Man, 64 years old, retired (former doorman), come in office through the early intervention oral cancer (Portuguese) project [PIPICO] due to a lower lip lesion with 3 months of evolution without trigger or cure. He has no relevante medical history including beeign a non-smoker and very low alchool consumption. Throughout the clinical examination is observed a slightly elevated eliptic lesion, vegetating aspect, well defined limits, measuring about 0,9x07cm, hard at touch but not stone and non-bleeding despite the higly redish colour. No cervical adenopathy. The major lesion was excised (full excision). The suspicious diagnosis was oral squamous cell carcinoma. It was confirmed in the histological exam: squamous cell oral carcinoma moderately differenciaded without vascular ou nerve invasion. HPV infection was also tested and it was negative. After cirurgical intervention (cirurgical ward) in order to enlarge lower lip margins free of neoplasm cells was obtained samples free of malignant cells. The patient was redirected to the Family Phisician and apointed to regular follow-up routine.



Photograph 1 – Vegetating aspect of the major and minor lesions



Photograph 2 – Macro vision of the vegetating aspect

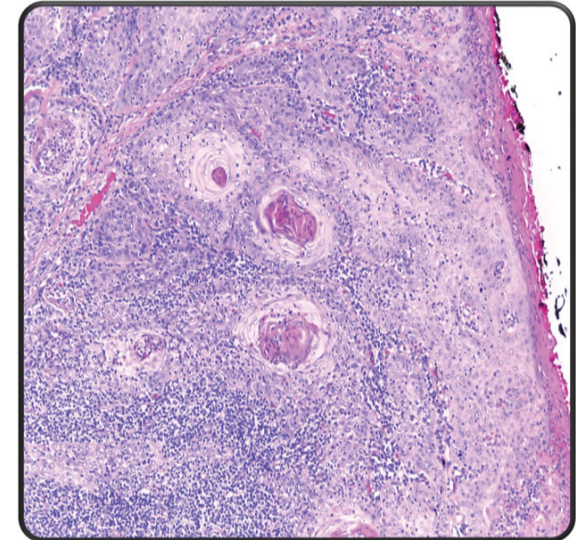


Figure 1 – specimen obtained, stain HE, 40x ampliation

## Discussion

Concerning all the oral cancer the squamous cell oral carcinoma represent about 90% of them all, those are also the most prevelente. The early detection in this case is synonymous of a raised expectation of survival above 94% for man at 5 years (84% for women). Regarding still this case only with 3 months of evolution the histological exam revealed “moderated differentiation”. So nevertheless the type of biopsy the most important is do it to achive the statment of the clinical diagnosis and the respective staging (TNM) to calculate the survival outcome.

## Conclusion

The oral cancer is raising in prevelence and incidence troughout all Europe, thus as seen in this cases is urgent to detect the most early as possible this type of lesions. The outstanding fact that, in the PIPICO Portuguese Project, the diagnosis (clinical and histological) is settled within few days, is the most valuable argument to support this type of National Public Health Project. This present case is, until now, one of the 14 oral cancer detected and intervened cases which supports all the arguments to extend widely this project to Portuguese population as seen in other medical specialities.

## Acknowledgements

The credits of the specimen figure in this paper belongs to the pathologist ward of IPATIMUP, in the person of the Chief director Catarina Leoy, Phd, and specially to the pathologist Dra Helena Baldaia and Dr. António Polónia

## Bibliography

1. Yardimci G, Kutlubay Z, Engin B, Tuzun Y - Precancerous lesions of oral mucosa. *World J Clin Cases*. 2014 Dec 16;2(12):866-72.
2. Shirani S, Kargahi N, Razavi SM, Homayoni S - Epithelial dysplasia in oral cavity. *Iran J Med Sci*. 2014 Sep;39(5):406-17.
3. Wikner J, Gröbe A, Pantel K, Riethdorf S - Squamous cell carcinoma of the oral cavity and circulating tumour cells. *World J Clin Oncol*. 2014 May 10;5(2):114-24
4. Gupta K, Metgud R - Evidences suggesting involvement of viruses in oral squamous cell carcinoma. *Patholog Res Int*. 2013
5. Jadhav KB, Gupta N - Clinicopathological prognostic implicators of oral squamous cell carcinoma: need to understand and revise. *N Am J Med Sci*. 2013 Dec;5(12):671-9
6. Vargas-Ferreira F, Nedel F, Etges A, Gomes AP, Furuse C, Tarquinio SB. - Etiologic factors associated with oral squamous cell carcinoma in non-smokers and non-alcoholic drinkers: a brief approach. *Oral Oncol*. 2013 Apr;49(4):287-92
7. Vieira RA, Minicucci EM, Marques ME, Marques SA. - Actinic cheilitis and squamous cell carcinoma of the lip: clinical, histopathological and immunogenetic aspects. *An Bras Dermatol*. 2012 Jan-Feb;87(1):105-14.