

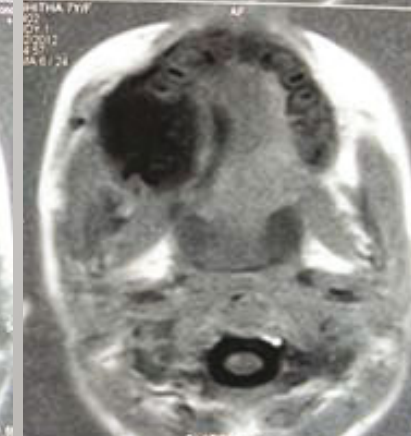
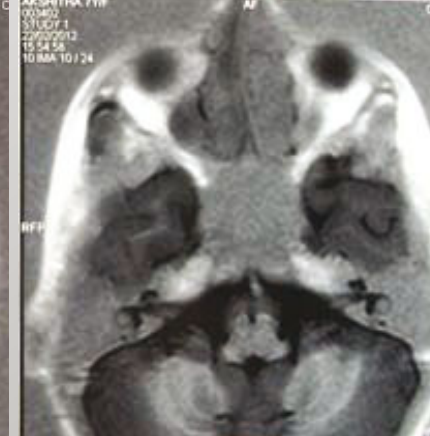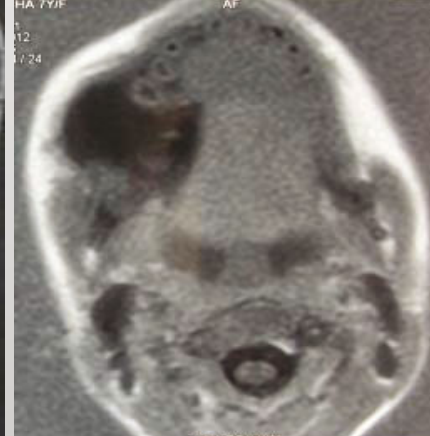
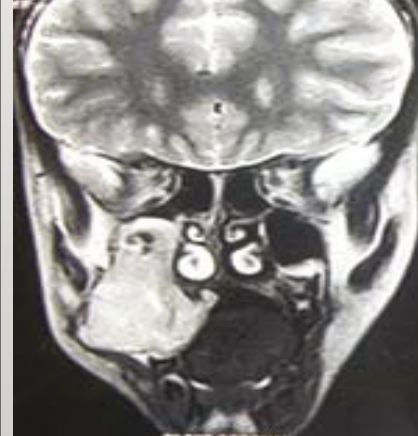
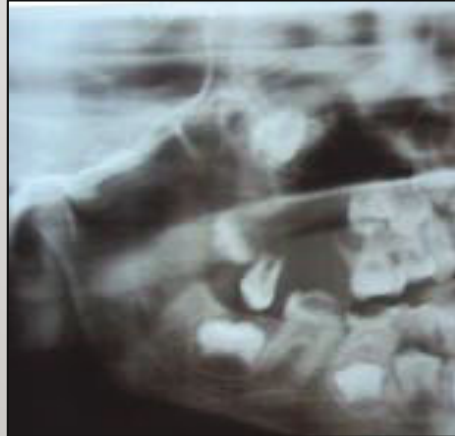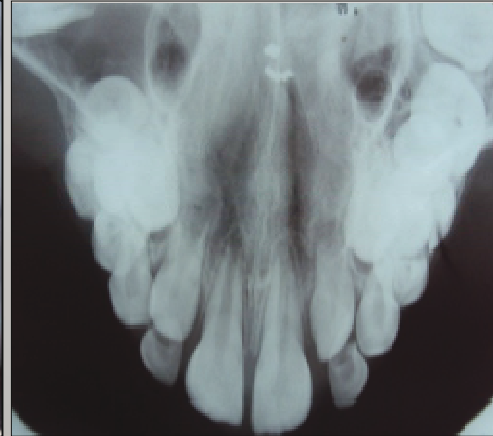
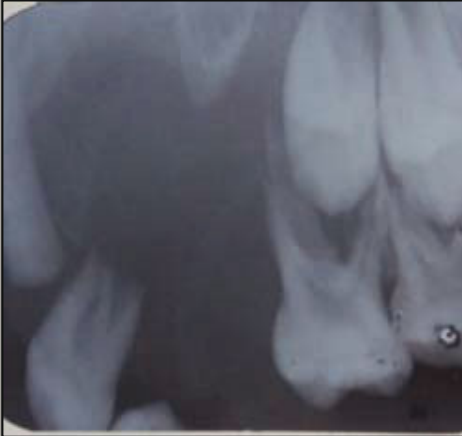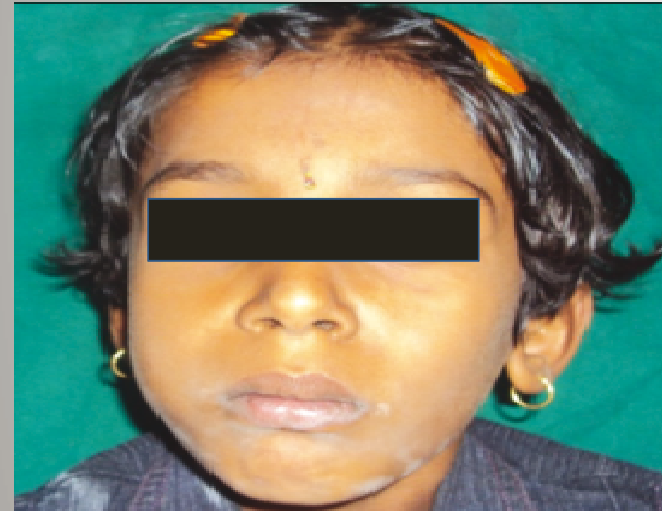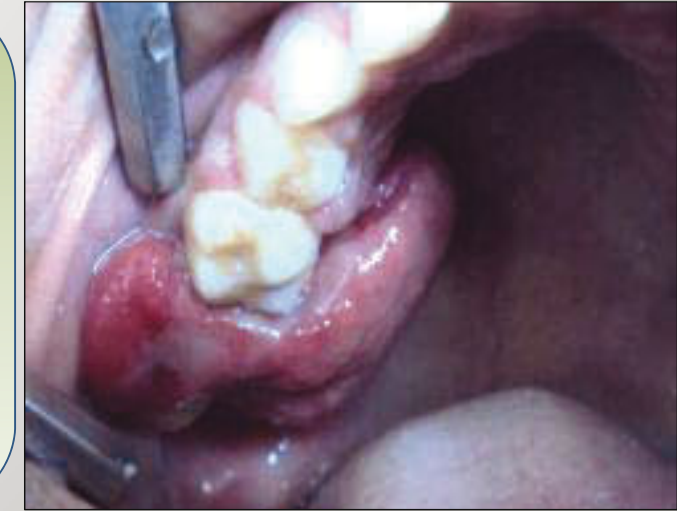Nodular Fasciitis-Report of a rare case

INTRODUCTION

WHO defines Nodular Fasciitis as a benign proliferative myofibroblastic lesion (Martínez-Blanco et al.,2002). First described by Konwaler (1955), it is also known as pseudosarcomatous fasciitis/, proliferative/infiltrative fasciitis. Commonly seen on forearms, head and neck (7-15%) and trunk. Although pathogenesis remains unknown, it appears to be a self-limiting lesion, reactive or inflammatory in nature, rather than a true neoplasm. It is often mistaken for a sarcoma due to its rapid growth, rich cellularity and relatively high mitotic activity.

CASE REPORT

A 7 yrs old female patient presented with one month history of pain and swelling in the upper right back tooth region. She gave no preceding history of trauma or bleeding. Intraorally, a lobulated erythematous mass noted involving the intraoral right alveolus of maxillary right posterior teeth extending up to midline of palate across the maxillary ridge. It was firm, sessile, tender without any bleeding tendency. Associated first molar was displaced and grade II mobile



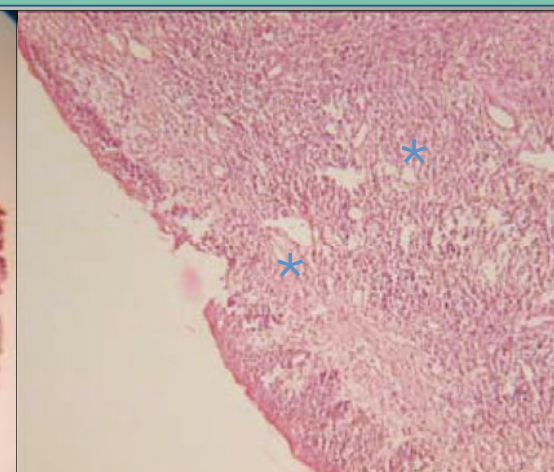
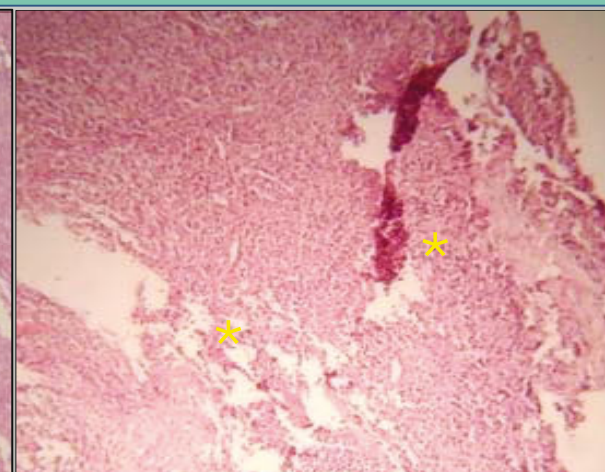
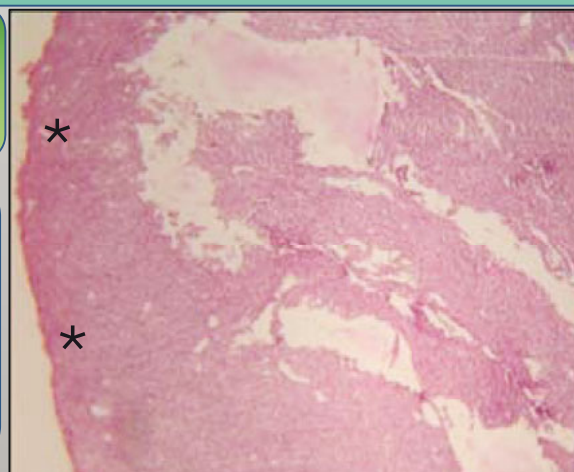
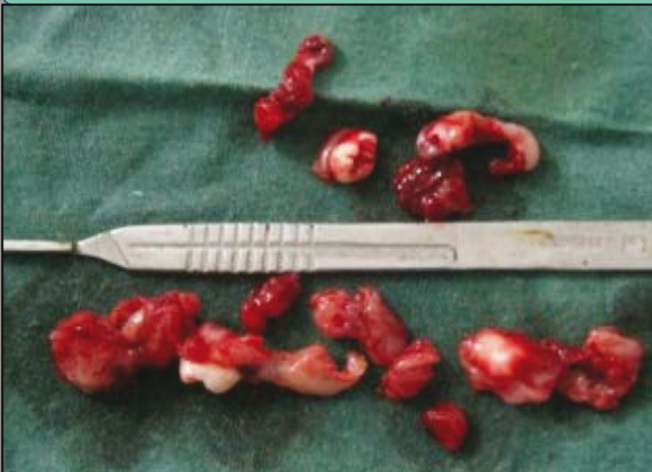
MRI reveals well defined expansile cystic mass of right maxilla

MANAGEMENT

Surgical excision with extraction of associated teeth

H/P-

- Squamous epithelium
- * Myxoid degeneration
- * Fascicular arrangements around microcystic spaces



DISCUSSION

Nodular fasciitis arises from the muscle fascia and extends into the subcutaneous tissues or the underlying muscle. The lesion typically is well-circumscribed, nonencapsulated and firmly adherent to the adjacent structures. Differential diagnoses included myxoid neurofibroma, myxoid dermatofibroma, Ewing's sarcoma, eosinophilic granuloma, fibrosarcoma, leiomyosarcoma etc. Sometimes it regresses spontaneously. Recurrence rare 1-2%

CONCLUSION

Due to deceptive features, special caution is imperative in order to obtain accurate diagnosis and appropriate treatment of Nodular Fasciitis and although somewhat rare, it should be considered in the differential diagnosis of oral soft-tissue tumorous masses