

Horizontal and vertical alveolar bone augmentation in the posterior maxilla with ReOss® and GEM 21 S® - a case report.

KRESA I. ADAMIEC M. WOJTOWICZ A.

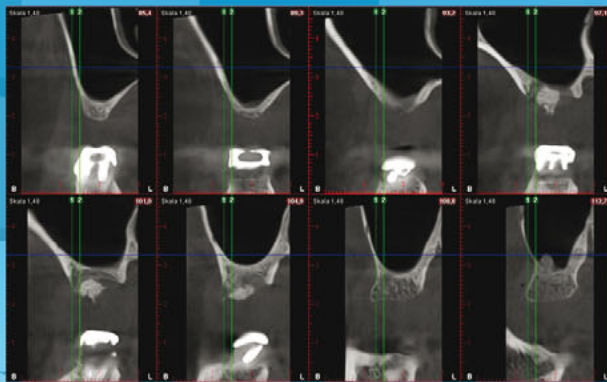
Department of Oral Surgery, Medical University of Warsaw, Poland

Head of the Department: prof. dr hab. n. med. Andrzej Wojtowicz

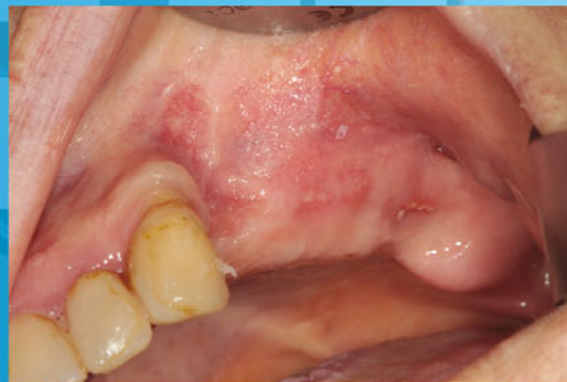

Introduction

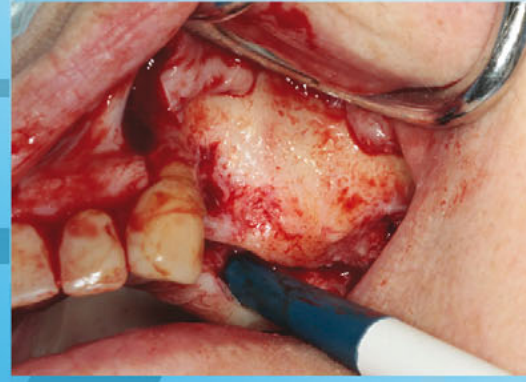Bone defects present after tooth extraction can often make implantation impossible, without prior guided bone regeneration. Usually horizontal and vertical bone augmentation is required. In this case report maxillary alveolar process augmentation, with individual titanium mesh ReOss® and GEM 21S® material containing PDGF-BB growth factor and alloplastic material - β -TCP, is described.



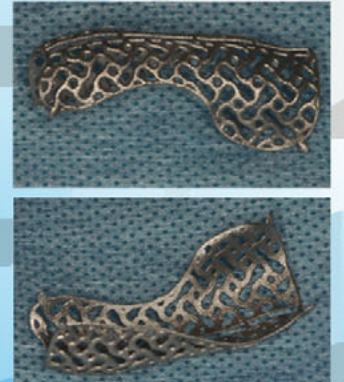
CBCT record prior to surgery



Clinical view prior to surgery



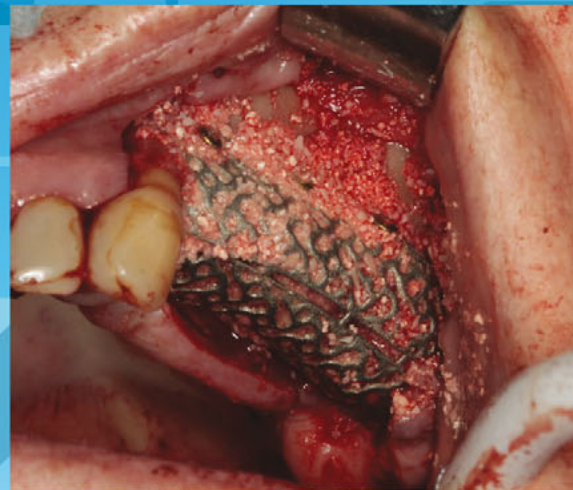
Clinical view after flap retraction



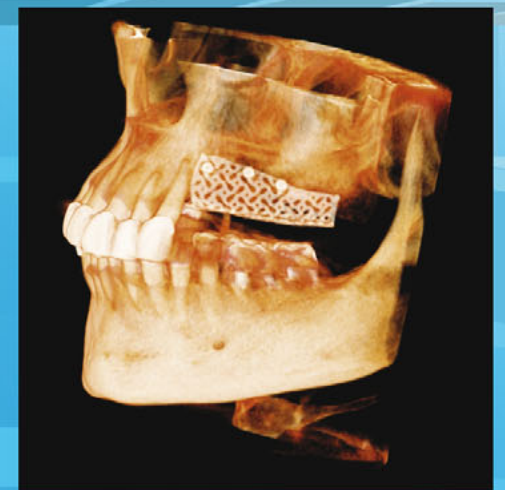Titanium mesh

Materials and Methods

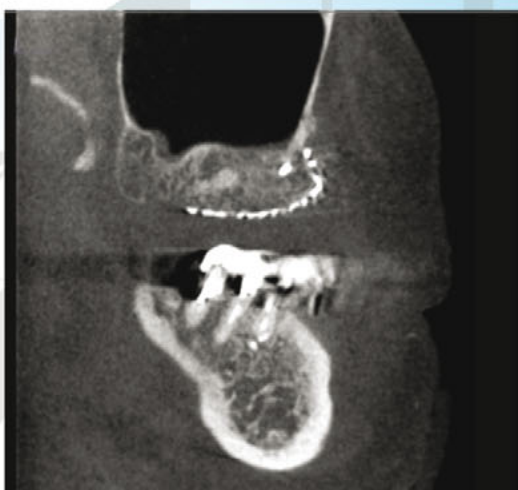
71-year-old patient presented to the dental office. In clinical examination lateral teeth in maxilla was noted. Previous vertical augmentation procedure was unsuccessful. On the basis of a CBCT record an individual ReOss titanium mesh was designed. It was filled with autogenous material, xenograft Osteonexon and GEM 21S. After titanium mesh placement, it was covered with collagen membrane Bio-Guide. After 5 months, ReOss was removed and new bone was obtained. Measurements revealed 8,7 mm of augmented bone, what is sufficient for dental implant placement.



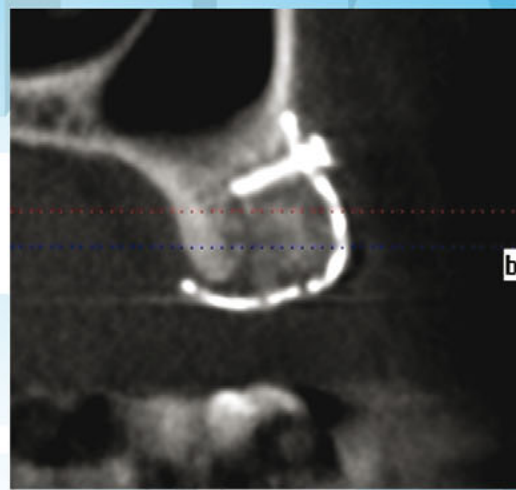
Titanium mesh and bone augmentation material placement



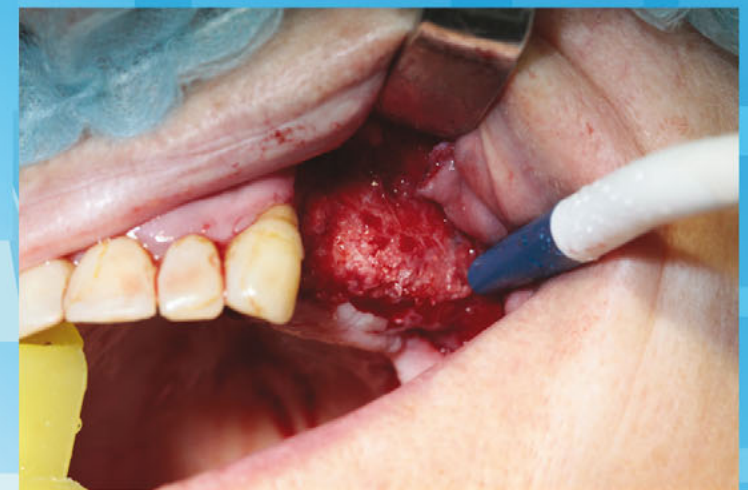3D reconstruction after titanium mesh placement



CBCT record 5 months after to surgery



CBCT record 5 months after to surgery



Clinical view during a second visit, prior to implant placement

Discussion.

Guided bone regeneration is widely described in the literature. Although horizontal augmentation is usually a predictable procedure, vertical augmentation is prone to resorption of the augmentation material. It is caused by two limitations – firstly, inadequate bone volume, precluding graft coverage without exposition or excessive soft tissue tension. Moreover, revascularisation of the graft is also a problem, because it decreases with vertical dimension of the grafted material.

The use of growth factors, autogenous bone and alloplastic material gives excellent clinical effects. It may help to increase the predictability of vertical augmentation procedures. Due to the use of growth factor PDGF-BB the process of angiogenesis is intensified, while individually designed titanium mesh allows for precise and three-dimensional reconstruction of bone conditions in the intended manner.