

# Squamous Cells Carcinoma: Case Report



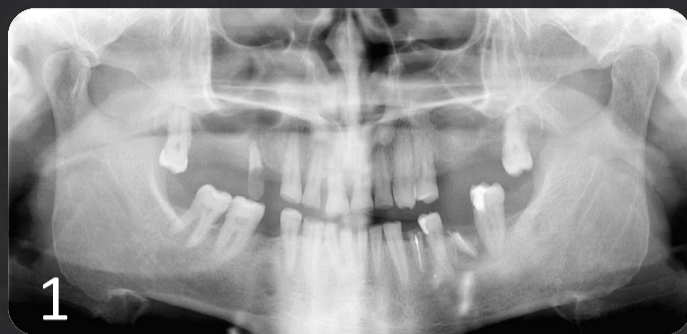Autors: Gil Fernandes Alves<sup>1</sup>, João Pedro Azevedo<sup>1</sup>, Henrique Alves<sup>3</sup>, Margarida Alves<sup>2</sup>, Duarte Gil Alves<sup>4</sup>

gilalves@sapo.pt

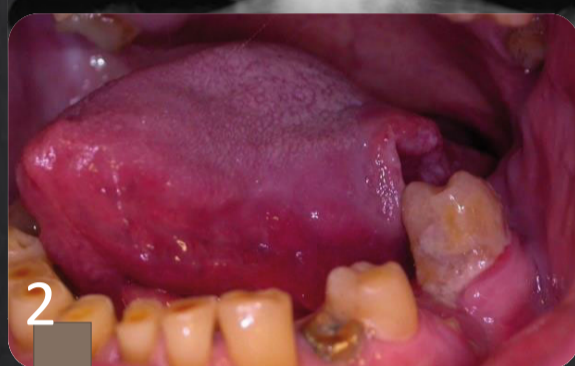<sup>1</sup>Dentist, <sup>2</sup>Student FMUP, <sup>3</sup>Student UFP, <sup>4</sup>Doctor



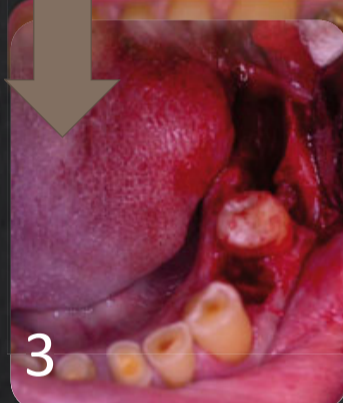## Clinical Case



57 year old smoker male, referred by a colleague, came to the office complaining of the presence of an “ulcer” for about 1 year.. He reported “feeling of having a spine permanently in the throat especially when swallowing”. Patient was medicated with CLOPIDOGREL and PERINDOPRIL being followed up by his cardiologist (ASA II patient).



After oral examination it was possible to observe the existence of a lesion on the left lateral border of the tongue and the oropharynx. Probable cause would be trauma caused by the tooth 37.



The patient was treated by removing the traumatic factor (Fig. 2, 3, 4) and medicated with AMOXICILLIN 875mg + AC. CLAVULANIC 125mg, ETORICOXIB 90mg, CLONIXINE 300mg and CLOROHEXIDINE gel.

An incisional biopsy was performed for later anatomopathological analysis (Fig. 5, 6, 7, 8, 9). Histopathological diagnosis was as follows:

- Well defined spinal-cell (epidermoid) carcinoma
- Acanthose

The analysis also revealed that the lesion was already in the T5 stage and was referred to the Otorhinolaryngologist Service of the Hospital Central do Funchal.

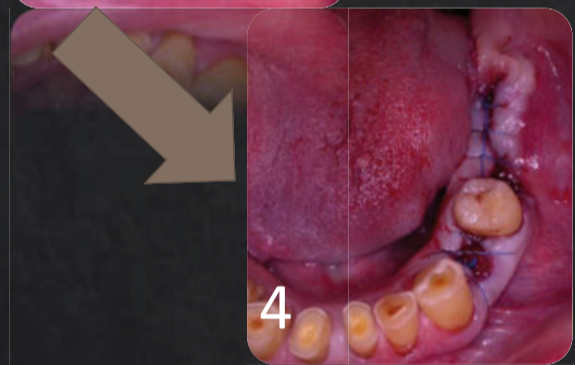
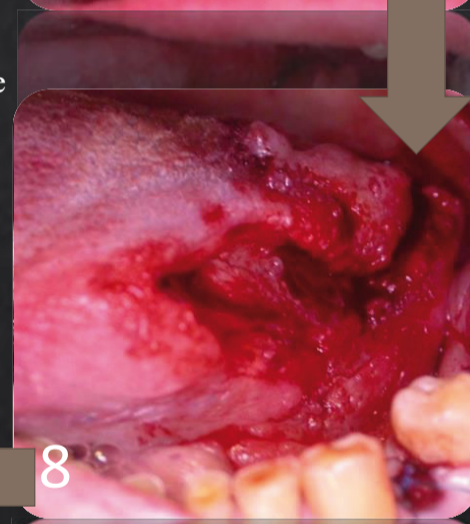
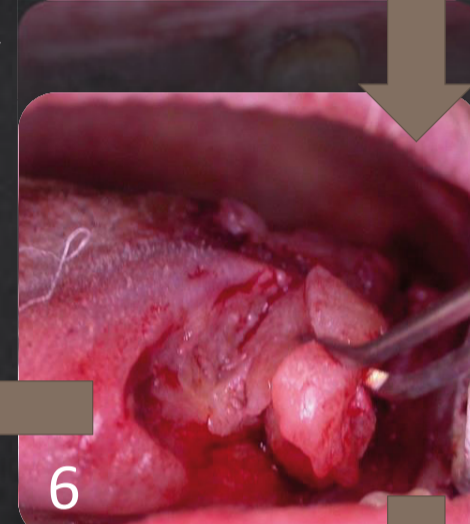
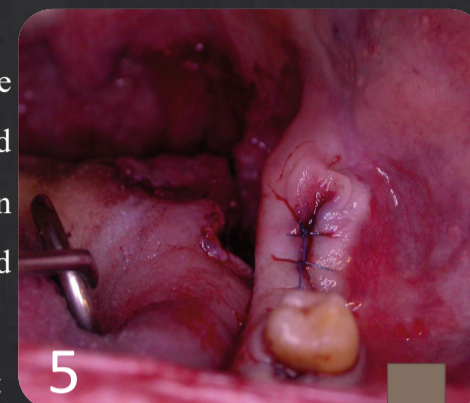
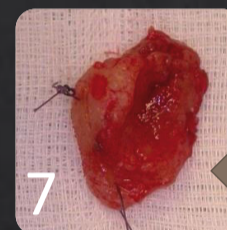
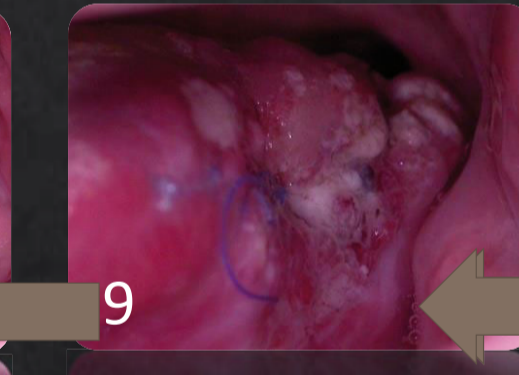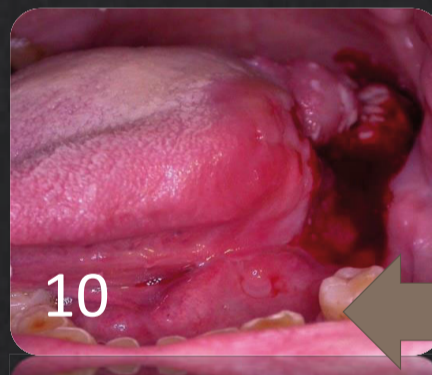


Fig. 10 – Control 14 days after biopsy.



## Discussion

Over 90% of neoplasias of the oral cavity and oro-pharynx, are squamous cell carcinomas. Its most common location is in the floor of the oral cavity, lateral edge of the tongue and the soft palate. They can progress from an *in situ* carcinoma to invasive squamous cell carcinoma, and at this stage there is already penetration of the deeper areas of the oral cavity and / or oropharynx and may lead to the death of the affected individual.

The main risk factors for this type of carcinoma are smoking and alcoholism, but may also be the result of chronic trauma such as dental caries, maladaptive dentures. HPV may also play a role in the progression of the lesion.

The survival rate depends of the state of the carcinoma and its location. If it presents in the tongue, and does not have a lymph node, its survival rate at 5 years is greater than 50%, whereas if it is detected on the floor of the mouth it is already 65%. If lymph node incidence already occurs, these percentages are reduced by half.

## Conclusion

Depending on its extent and location, squamous cell carcinoma has different types of treatment. It includes surgery, in cases identified early on, or radiotherapy, in cases where the lesion has already reached deeper layers. In lingual lesions, the treatment involves surgery and sometimes it's necessary surgical reconstruction in order to minimize postoperative oral sequelae. Speech therapy may be needed in more severe cases. Due to the asymptomatic nature of most of these lesions, proper screening by dentists is an important weapon in the fight against oral cancer.