

Bucco-lingual Orientation of the Inferior Alveolar Canal for Implant Osteotomy: A CBCT-based Study in a Malaysian Population



Michelle Chua Kher Wei, Koh Wen Jiong, Pravinkumar G. Patil
School of Dentistry, International Medical University, Kuala Lumpur, Malaysia



Introduction

The inferior alveolar nerve (IAN) can be subjected to iatrogenic injury during surgical procedures. It is interesting to know that the IAN is one of the most commonly injured nerve (64.4%), followed by the lingual nerve (28.8%).¹ Moreover, up to 40% of the incidence rate are implant-related IAN injuries.¹

Hence, the location and course of the IAN are important landmarks during implant placement in the mandible. The best way to minimize these damages is to have a clear three-dimensional vision of the jaw. This can be achieved by combining the practical knowledge of basic mandibular anatomy and the data obtained from clinical and radiological examination.

Objective

- To determine the bucco-lingual orientation of the IAN in mandibular premolar and molar regions in a Malaysian population
- To evaluate the variations associated with ethnicity, side, gender and age in bucco-lingual orientation of the IAN

Materials and Methods

A total of 121 CBCT-DICOM files were selected using a simple stratified random sampling method. Among 121 participants, 40 were Malay, 40 were Indian, and 41 were Chinese, including 60 females and 61 males. The participants were also divided into 3 age groups (18-39, 40-59 and 60-80 years old) based upon the general prosthetic needs.

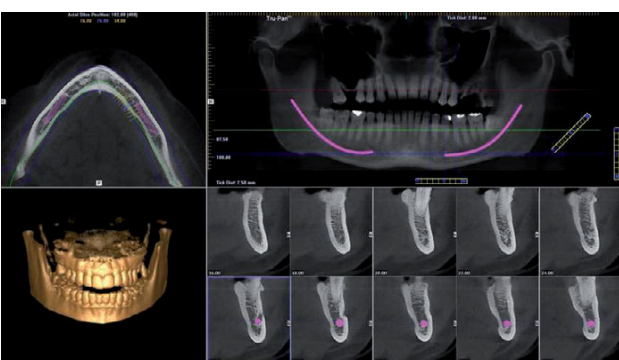Inclusion criteria

- Dentate or edentulous patients of three ethnicities.
- Between the ages of 18 and 80 years.
- Healthy, medically compromised or even those previously radiated patients but not involving the interforaminal mandible region.

Exclusion criteria

- Patients of mixed racial origins.
- History of trauma, pathology, or surgical intervention to the mandible.
- Patients with an existing pathological disorder at the mandible.
- Unclear CBCT images.

The anatomy of the entire mandible was assessed first in the axial, coronal cross-sectional, and panoramic views.

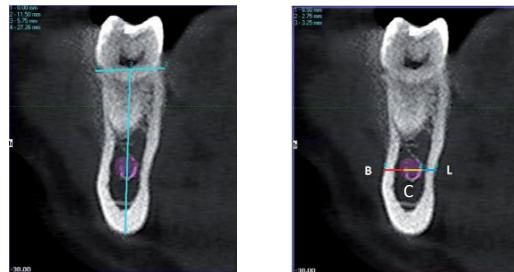


Two types of parameters were measured:

- Bucco-lingual positioning of the IAN
- Buccal bone width (B), canal thickness (C), lingual bone width (L) in millimeters (mm).

Materials and Methods

Measurements were done in cross-sectional views:

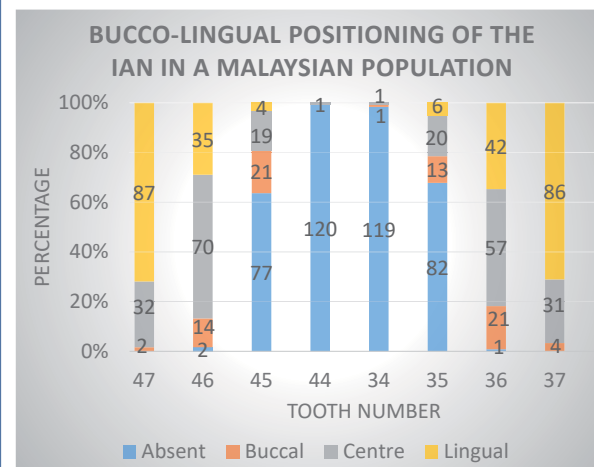


The bucco-lingual positioning of the IAN was determined by the vertical line while the values of B, C, and L were measured at the horizontal canal levels.

Various statistical tests were carried out to evaluate the variations, such as the Kruskal Wallis h test, Friedman test, one-way ANOVA, independent t test, and paired sample t test.

Results

Bucco-lingual positioning of the IAN



Tables showing variations in bucco-lingual positioning

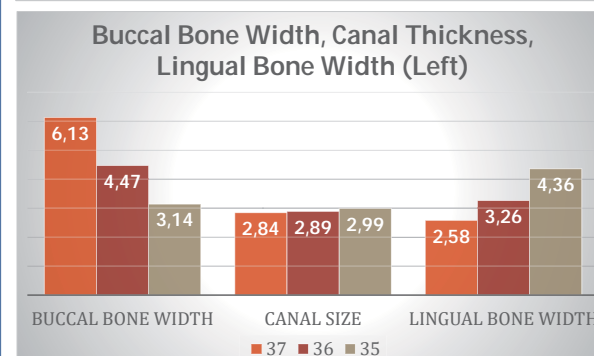
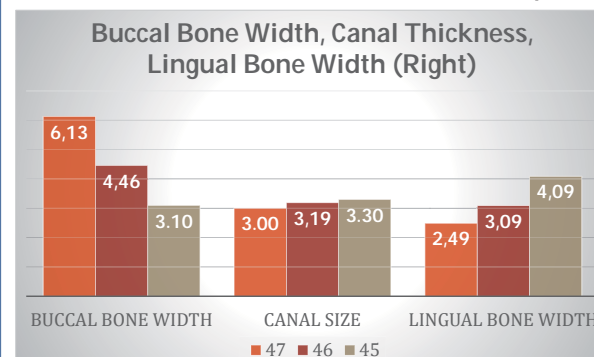
	47	46	45	37	36	35
ETHNIC						
GENDER			√			
AGE	√			√		

	2 nd MOLAR	1 st MOLAR	2 nd PREMOLAR
SIDE			

√ indicates statistically significant difference

Age – In 2nd molar regions, the IAN was located less on the lingual side in age-group 3 compared to age-groups 1 and 2.

Overall Mean Values of B, C and L (mm)



Results

Tables showing variations in mean values

	47B	47C	47L	46B	46C	46L
ETHNIC		√	√		√	√
GENDER				√		
AGE		√	√			

	37B	37C	37L	36B	36C	36L
ETHNIC		√	√			√
GENDER						
AGE		√				

SIDE	2 nd MOLAR			1 st MOLAR		
	B	C	L	B	C	L
		√			√	

* Premolars were omitted due to small sample size.

- Ethnicity – Chinese > Malay > Indian
- Gender – Male > Female
- Age – Age-group 3 > 2 > 1
- Side – Right > Left

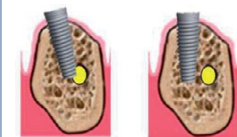
Discussion

- CBCT was used for this study as it provides clear and accurate images of structures and is useful for assessing the bone component.
- Comparing variations between literatures:

	Ethnic	Gender	Age	Side
Our Study	√	√	√	√
Mirbeigi ²	N/A	X	N/A	N/A
Nagadia ³	N/A	X	√	N/A
Balaji ⁴	N/A	X	N/A	√

- Limitation - dentition status of the samples was not taken into consideration. As well, in edentulous ridges, the tooth area was determined by estimation.

Clinical Implication



IAN is an important landmark during implant placement. With the knowledge of the bucco-lingual positioning of

IAN and the available bone width buccal and lingual to the IAN, the safe zone for implant placement can be determined. This variation should also be taken into consideration prior to implant placement.

Conclusion

- The IAN extended from the lingual side in the 2nd molar to the centre in the 1st molar and exited before the 2nd premolar through the mental foramen.
- The buccal bone width decreased from the 2nd molar regions to the 2nd premolar regions, while the lingual bone width increased.
- In regards to the bucco-lingual positioning of the IAN, there are gender- and age-related variations in specific tooth regions.
- There are ethnicity-, age-, and side-related variations in the canal thickness. Variation of the buccal bone width is also noted between genders. In regards to lingual bone width, there is also variation associated with age.

References

- Juodzbaly G, Wang HL, Sabalys G. Injury of the Inferior Alveolar Nerve during Implant Placement: a Literature Review. J Oral Maxillofac Res. 2011;2(1).
- Mirbeigi S, Safaee A, Ezoddini F, Khojastepour L, Navab-Azam A. Buccolingual course of the inferior alveolar canal in different mental foramen locations: A cone beam computed tomography study of an Iranian population. International Journal of Applied and Basic Medical Research. 2016;6(4):262.
- Nagadia R, Tay ABG, Chan LL, Chan ES. The spatial location of the mandibular canal in Chinese: A CT study. Int J Oral Maxillofac Surg. 2011;40(12):1401-5.
- S. M. Balaji, N. R. Krishnaswamy, S. Manoj Kumar TR. Inferior alveolar nerve canal position among South Indians: A cone beam computed tomographic pilot study. Ann Maxillofac Surg. 2012;2(1):51