

Comparison of Two Post Preparation Methods in Mandibular Second Molars with a C-shaped Root Canal Configuration

Si Yu LI¹, Yi Hong LIU¹, Ke Yi HAO², Jie PAN¹

Objective: To compare the reduction of residual dentine thickness of two different post preparation methods on the mandibular second molars with a C-shaped root canal configuration.

Methods: A total of 26 extracted right mandibular second molars with a C-shaped root canal configuration were selected and paired based on similar canal morphology. Each of the paired teeth was randomly allocated to the heat and ultrasonic instruments group (HU group) or Peeso Reamer (Mani, Utsonomiya, Japan) group (PR group) ($n = 13$) and received post preparation with different instruments after the same endodontic treatment. The reduction of residual dentine thickness and the minimal remaining dentine thickness at the apical sections at 4 or 7 mm below the cemento-enamel junction (CEJ) were recorded. The data were analysed using an independent samples t test ($\alpha = 0.05$).

Results: The reduction of residual dentine thickness for the HU group was less than that for the PR group in the two sections. Moreover, at the section 7 mm below the CEJ, the teeth reduction of the distolingual wall in the HU group (0.022 ± 0.007 mm) was significantly lower than that in the PR group (0.101 ± 0.013 mm) ($P < 0.01$).

Conclusion: Using heat and ultrasonic instruments to perform post preparation could follow the original canal configuration to save more tooth structure in the remaining root canal wall, minimise the reduction of residual dentine thickness and decrease the incidence of root canal perforation.

Key words: C-shaped canal, mandibular second molars, post preparation, teeth reduction
Chin J Dent Res 2021;24(2):125–132; doi: 10.3290/j.cjdr.b1530527

C-shaped canals are mostly found in mandibular second molars^{1,2}. The incidence of C-shaped canals in mandibular second molars varies greatly among different populations, with a mere 2.7% seen in Americans³ but much more frequently in Asians⁴⁻⁷. No correlation has been found between sex or age and the prevalence of C-shaped canals in mandibular second molars⁸. The frequency of C-shaped canals in the Lebanese and Chi-

nese populations is 19.14%⁴ and 31.5%⁵, respectively. In Koreans, the prevalence of C-shaped canals in mandibular second molars was 32.7% to 45.5%^{6,7}.

The defining feature of a C-shaped canal is the connection of the mesiobuccal and distal canals by a continuous trough. Sometimes these two canals may even be connected to the mesiolingual canal that comprises a ribbon-shaped structure with many lateral canals⁹; this structure displays the “C” configuration at the cross-section of the root canal¹⁰. The accessory and lateral canals varied considerably¹¹⁻¹³. Moreover, the specific isthmus structure not only posed challenges for thorough cleaning and compact obturation of the canals, but also made it difficult to carry out the following post-core crown procedure.

The use of a dental microscope, ultrasonic vibratory instruments and warm vertical condensation technique make it possible to optimise root canal therapy in C-shaped canal systems. On the one hand, more teeth with C-shaped canals can be preserved, whereas on

1 Department of General Dentistry, Peking University School and Hospital of Stomatology & National Clinical Research Center for Oral Diseases & National Engineering Laboratory for Digital and Material Technology of Stomatology & Beijing Key Laboratory of Digital Stomatology, Beijing, P.R. China.

2 Department of Oral Implantology, Peking University School and Hospital of Stomatology, Beijing, P.R. China.

Corresponding author: Dr Jie PAN, Department of General Dentistry, Peking University School and Hospital of Stomatology, 22# Zhong-guancun South Avenue, Haidian District, Beijing 100081, P.R. China. Tel: 86-10-82195586; Fax: 86-10-62170009. Email: panjie72@sina.com

the other, there are more strict requirements to follow during prosthetic procedures. The mechanical method has become a universally accepted routine post preparation technique that involves the sequential use of rotary enlarging and shaping instruments such as Peeso Reamer (Mani, Utsonomiya, Japan) to prepare the root canals according to root length, morphology and diameter. It has been proven that the amount of residual dentine is a determining factor for fracture resistance in endodontically treated teeth¹⁴⁻¹⁶. Any operation that potentially reduces the dentine thickness, such as the use of rotary instruments, may cause future vertical root fractures. Thus, preservation of the internal tooth structure provides maximum fracture resistance^{17,18}. For C-shaped canal systems in particular, the complexity and irregularity of the root canal drastically increases the difficulties and risks of post preparation.

However, how can post preparation be performed safely for a C-shaped canal system? There is no relevant research in the previous literature. This study demonstrated a modified method that used heat and ultrasonic instruments for post preparation and aimed to compare the different effects of the two methods on the reduction of residual dentine thickness and canal morphology.

Materials and methods

Teeth

The study protocol was approved by the Peking University Hospital of Stomatology Biomedical Institutional Review Board (PKUSSIRB-2013041).

Twenty-six right mandibular second molars with fused roots were selected from a random collection of extracted teeth originating from a native Chinese population and subjected to NewTom VGi CBCT examination (Quantitative Radiology, Verona, Italy). All specimens were required to be intact without any defects, cracks, caries or external resorption. The inclusion criterion was the presence of a C-shaped root canal, as defined by Cooke and Cox¹. Only teeth with a C1, C2 or C3 configuration, as defined by the modification by Fan et al¹⁹ of the original classification by Melton et al²⁰, were included. Teeth with canals presenting C4 and C5 configurations, namely those with a single round or oval canal and those with no patent canal space, were excluded from the study. All teeth were cleaned carefully with curettes to remove any soft tissue remnants and were stored in saline solution.

Experimental design

All teeth were scanned using the aforementioned CBCT system, tube voltage was fixed at 110 kVp and the mAs was determined through a type of automatic exposure control based on a 2D scout image. The teeth were initially paired based on similar canal morphology. One tooth from each pair was randomly allocated to one of the two projected treatment groups, and the second was assigned to the other group. After the groups were formed, a coin toss was used to define which group would be treated with either the heat and ultrasonic instruments or Peeso Reamer instruments. One experienced endodontist served as the operator for endodontic treatment and one experienced prosthodontist served as the operator for post space preparation. The operators had access to regular buccolingual radiographic images of the teeth but no access to the CBCT 3D images of the teeth.

Root canal preparation and obturation

All the endodontic procedures were performed under a surgical microscope (Carl Zeiss Meditec, Oberkochen, Germany) by the same endodontic specialist in both groups. The working length (WL) was established at the apical foramen. The teeth were then fixed into the corresponding right mandibular molar site in a standard model with polyether impression material (Impregum Penta Soft, 3M ESPE, St Paul, MN, USA). The C-shaped root canals were prepared using ProTaper Universal nickel-titanium rotary files (Dentsply Maillefer, Ballaigues, Switzerland) to F2 file according to the manufacturer's instructions in a dental simulation training system (Nissin Dental Products, Kyoto, Japan). During preparation, the root canal was irrigated with 2 ml 2.5% sodium hypochlorite (NaOCl) solution after use of each instrument. After instrumentation, the root canals were dried with paper points, then the root canals were obturated using the warm vertical condensation technique (B&L Biotech, Ansan, Korea). The specimens were kept in saline at 37°C for 1 week.

Specimen preparation

A line was drawn on the cervical area according to the method outlined by Chai and Thong²¹ to identify the plane perpendicular to the longitudinal axis of each tooth. This was done by marking the mesial, distal, buccal and lingual crests of the cemento-enamel junction (CEJ). A horizontal line was then drawn to join the midpoints of all the crests marked on the four surfaces. The second

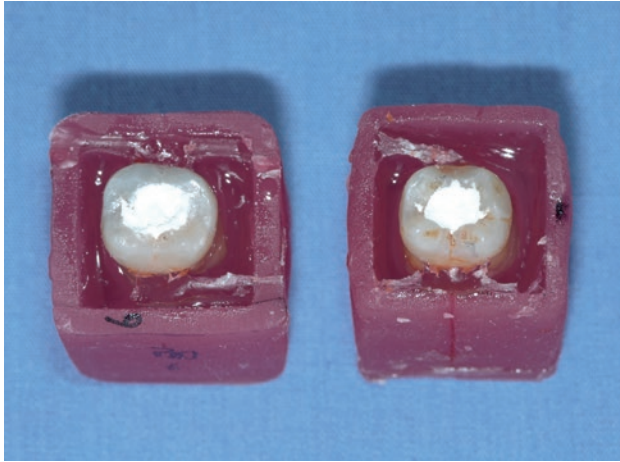


Fig 1 The roots of the extracted teeth were embedded in photocuring models.

and third lines, which were parallel with the first line, were drawn 4 mm and 7 mm below the CEJ immediately.

During the mounting procedure, each tooth was positioned with wax in a hole cut in a piece of Perspex to allow the first line on the tooth surface to be level with the Perspex surface²¹. The obturated roots were then embedded using a transparent epoxy resin (Kafuter, Guangdong Hengda New Materials Technology, Guangzhou, China) in the precut light-curing urethane acrylate moulds (Dreve, Unna, Germany) (Fig 1). Retention grooves were made on the inner surface of the mould to increase retention and facilitate subsequent replacement. After setting, all specimens were removed from the moulds and were sectioned with a 0.3-mm Kerf diamond blade (IsoMet Low Speed Saw, Buehler, Lake Bluff, IL, USA) from the lines located 4 and 7 mm below the CEJ. Post preparation was performed after fixing the dissected parts into the mould and checking that they had adapted well.

Post preparation

The moulds were fixed to the standard models using Type V gypsum (Royal Rock, Garreco, Heber Springs, AR, USA) in the right mandibular second molar site and all the procedures were performed by the same prosthodontic specialist in the dental simulation training system under operating microscopy.

To preserve the apical seal, 4 mm of the root filling material was retained at the apical level. After post preparation, passive ultrasonic canal irrigation was performed for 1 minute (20 seconds repeated 3 times) with distilled water to remove the canal debris.


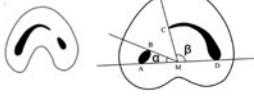
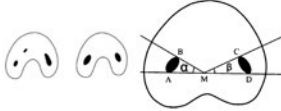
C1		The canal shape is an uninterrupted "C" with no separation or division.
C2		The canal shape resembles a semicolon resulting from a discontinuity of the "C" outline, but angles α and β should be no smaller than 60° .
C3		There are two or three separate canals and both angles α and β are smaller than 60° .

Fig 2 Classification of C-shaped canal system.

In the HU group, post preparation was carried out in two steps. First, a heat carrier (Alpha II, B&L Biotech, Ansan, South Korea) was used to remove the gutta-percha from the root canals until expected post preparation length, leaving 4 mm of remaining filling. A hand endodontic plugger (B&L Biotech) was used to condense the residual gutta-percha seal, then an ET 20D ultrasonic working tip (Satelec, Mérignac, France) and ultrasonic device (Suprasson Newtron P5, Satelec) were used to remove residual gutta-percha and undercut from the inner canal wall as much as possible throughout the post space length.

In the PR group, the post space was prepared using sequential size 2 Peeso Reamers leaving 4 mm gutta-percha in the apical section.

Final assessment and statistical analysis

According to the classification method outlined by Fan et al¹⁹ in 2004, the C-shaped canals were identified as C1 (consecutive C-shaped canal), C2 (semicolon-shaped canal, angle α or β minimum 60°) or C3 (two or three separated canals, angle α and $\beta < 60^\circ$) (Fig 2). The canal morphology at the levels measured as 4- and 7-mm cross-sections below the CEJ were observed and recorded by one estimator who was blinded to the groupings.

The minimal dentine thickness of the buccal, mesial, mesiolingual, distolingual and distal root walls in the two groups was measured using a Kestrel Elite Dynascope (Vision Engineering, Woking, UK) at 4 and 7 mm before post preparation by the estimator. The distance between the internal and external dentine surfaces was recorded as the minimal residual dentine

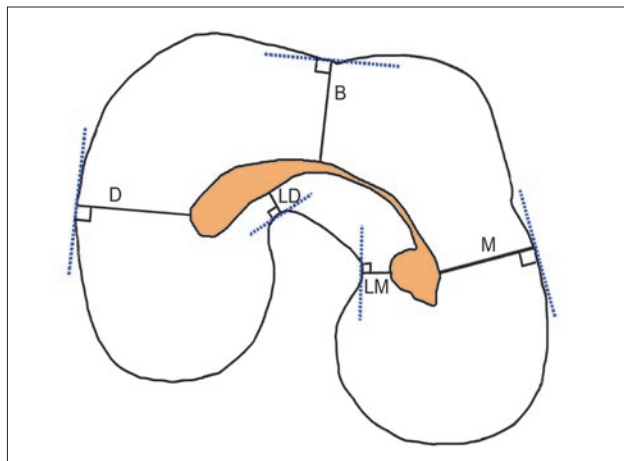


Fig 3 Schematic diagram of residual dentine thickness.

thickness. Further, the specific measured points were marked on the external dentine surface to ensure accuracy and repeatability of measurements (Fig 3). After post preparation, the second measurement was performed in strict accordance with the pre-marked points using the dynascope by the same estimator. The reduction of residual dentine thickness was obtained by subtracting the two minimal dentine thickness values before and after post preparation. All the cross-sectional photographs were obtained using a Nikon E995 Digital Camera (Nikon, Tokyo, Japan).

Statistical analyses were performed using SPSS (version 25.0, IBM, Chicago, IL, USA). The difference between the two groups was compared using an independent-samples *t* test. Two-sided *P* values < 0.05 were accepted as statistically significant. All values were expressed as mean ± standard deviation (SD).

Results

The morphology of C-shaped root canals in mandibular second molars varies greatly along the root length. The evaluation results of the cross-sectional canal morphology for both groups are shown in Tables 1 and 2.

The minimal values for the residual dentine thickness of the canal wall before and after post preparation are shown in Tables 3 and 4, respectively. The mean minimal dentine thickness of all specimens before post preparation at the 7 mm cross-section below the CEJ was 0.662 ± 0.149 mm in the distolingual dentine wall and 0.706 ± 0.142 mm in the mesiolingual dentine wall. These two regions were most at risk of lateral perforation.

The reduction of residual dentine thickness for the two groups is shown in Figs 4 and 5. The reduction of

residual dentine thickness in the HU group was less in both sections than in the PR group. At the 4-mm cross-section below the CEJ, the total reduction of residual dentine thickness in the HU group was significantly less than that in the PR group, whereas at the 7-mm cross-section below the CEJ, the reduction of residual dentine thickness in the mesiolingual and distolingual dentine walls in the HU group was significantly less than that in the PR group. The thinnest canal wall was also the region most vulnerable to canal perforation.

In the HU group, the modified post preparation method did not change the original morphology of the canal and thus did not reduce too much of the remaining dentine wall thickness (Fig 6). However, owing to the limitations of mechanical rotary instruments, the Peeso Reamers destroyed the canal's original morphology (Fig 7) and considerably increased the risk of canal perforation (Fig 7d).

Discussion

Recent studies on C-shaped canal systems have focused on incidence, anatomical morphology, radiographic features and identification. There is a lack of research about the specific clinical procedure. For the Chinese and Korean populations, the incidence of C-shaped canal systems in the mandibular second molars is around 31.5%⁵ and 32.7%⁶, respectively. Thus, this study is important for clinical application.

Thirteen samples were included in each group in this study. The number of samples was calculated according to the formula, and was approximately equal to 10. It was also based on previous studies^{15,22,23}.

The mean lengths of the dental crown and the root of the mandibular second molars among the Chinese population are 7.6 mm and 12.3 mm, respectively²⁴. Subtracting the 4- to 5-mm length of apical seal, the residual 7- to 8-mm root length is available for post preparation. The deeper the post preparation approach to the apex, the higher the risk of canal perforation. Thus, cross-sections at 4 and 7 mm below the CEJ were selected to investigate the middle and lower parts of the root canals, respectively.

The teeth with C-shaped canals were divided into two groups according to the canal morphology to guarantee consistency of treatment difficulty. There were six C1-shaped teeth and four C2-shaped teeth at the canal orifice level in each group. Nevertheless, the middle and lower parts of the canals varied greatly. The HU group expressed slightly more variation and complexity. In the middle part (4 mm below the CEJ), more C2- and C3-shaped canals were encountered. C2 and

Table 1 Number of canal types at different sections.

Cross-sectional level	Canal type	HU group	PR group	Total
Canal orifice	C1	7	7	14
	C2	6	6	12
4 mm below CEJ	C1	6	6	12
	C2	5	6	11
	C3	2	1	3
7 mm below CEJ	C1	2	2	4
	C2	6	6	12
	C3	5	5	10

Table 2 Variation in canal morphology at different cross-sections along the length of the canal to guarantee the same treatment difficulty (N = 13).

Treatment difficulty	HU group		PR group	
	OL-CEJ + 4-CEJ + 7	n	OL-CEJ + 4-CEJ + 7	n
Easy	C1-C1-C1	2	C1-C1-C1	2
Medium	C1-C1-C2	1	C1-C1-C2	2
	C1-C1-C3	3	C1-C1-C3	2
Difficult	C1-C2-C2	1	C1-C2-C2	1
	C2-C2-C2	4	C2-C2-C2	3
	C2-C3-C3	2	C2-C2-C3	2
			C2-C3-C3	1

CEJ + 4, 4 mm below CEJ; CEJ + 7, 7 mm below CEJ; OL, orifice level.

Table 3 Mean ± SD of minimal dentine thickness before post preparation at different cross-sections (mm).

Cross-section	Location	HU group	PR group	P value	All specimens
CEJ + 4	DL	1.851 ± 0.172	1.967 ± 0.231	0.922	1.914 ± 0.150
	D	1.840 ± 0.078	2.009 ± 0.131	0.595	1.908 ± 0.098
	B	2.148 ± 0.081	2.156 ± 0.098	0.720	2.152 ± 0.071
	M	1.736 ± 0.072	1.798 ± 0.120	0.729	1.764 ± 0.087
	ML	1.563 ± 0.167	1.636 ± 0.267	0.816	1.592 ± 0.168
CEJ + 7	DL	0.688 ± 0.160	0.648 ± 0.194	0.876	0.662 ± 0.149
	D	1.389 ± 0.095	1.597 ± 0.082	0.326	1.501 ± 0.066
	B	1.513 ± 0.121	1.582 ± 0.118	0.690	1.552 ± 0.089
	M	1.173 ± 0.078	1.431 ± 0.109	0.068	1.397 ± 0.083
	ML	0.853 ± 0.162	0.616 ± 0.159	0.547	0.706 ± 0.142

B, buccal; D, distal; DL, distolingual; M, mesial; ML, mesiolingual.

Table 4 Mean ± SD of minimal dentine thickness after post preparation at different cross-sections (mm) (n = 13)

Cross-section	Location	HU group			PR group			P value
		Mean ± SD	Min	Max	Mean ± SD	Min	Max	
CEJ + 4	DL	1.692 ± 0.172	0.939	2.811	1.643 ± 0.236	1.311	2.529	0.866
	D	1.816 ± 0.076	1.554	2.075	1.967 ± 0.107	1.400	2.369	0.332
	B	2.103 ± 0.080	1.844	2.424	2.090 ± 0.078	1.872	2.334	0.484
	M	1.692 ± 0.074	1.208	2.032	1.746 ± 0.106	1.157	1.950	0.685
	ML	1.534 ± 0.169	0.881	2.597	1.541 ± 0.272	0.625	2.529	0.228
CEJ + 7	DL	0.664 ± 0.160	0.191	1.672	0.553 ± 0.203	0.111	1.627	0.670
	D	1.346 ± 0.071	1.119	1.629	1.515 ± 0.080	1.108	1.851	0.130
	B	1.486 ± 0.115	0.954	1.779	1.628 ± 0.117	1.267	2.054	0.659
	M	1.224 ± 0.108	0.969	1.674	1.393 ± 0.110	1.053	1.897	0.298
	ML	0.756 ± 0.161	0.089	1.795	0.604 ± 0.161	0.088	1.238	0.320

Max, maximum value; min, minimum value.

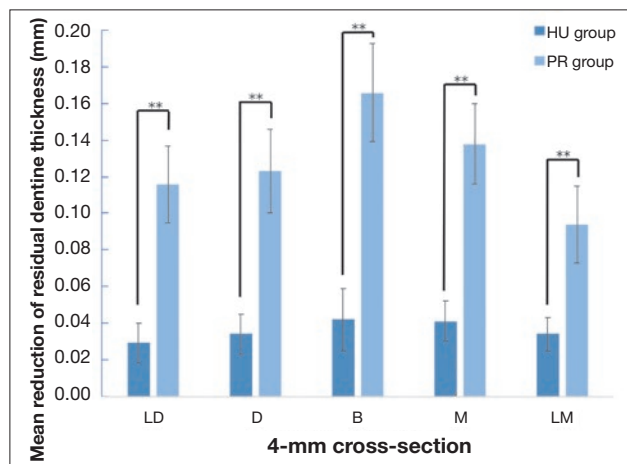



Fig 4 Mean reduction of residual dentine thickness at 4-mm cross-section below the CEJ (mm) (n = 13), ***P* < 0.01.

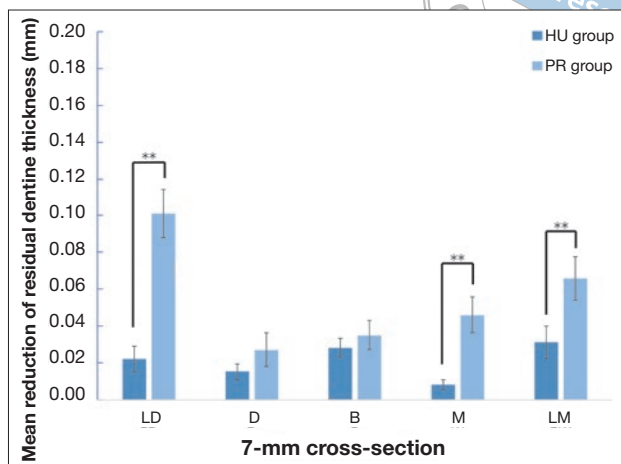


Fig 5 Mean reduction of residual dentine thickness at 7-mm cross-section below the CEJ (mm) (n = 13), ***P* < 0.01.

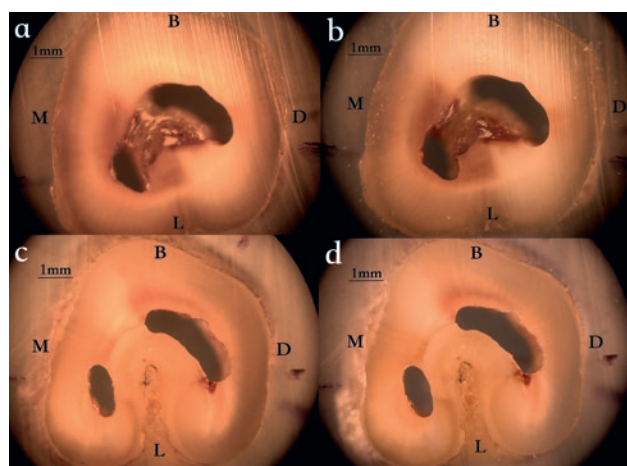


Fig 6 Canal morphology in the HU group: (a) 4-mm cross-section before post preparation; (b) 4-mm cross-section after post preparation; (c) 7-mm cross-section before post-preparation; (d) 7-mm cross-section after post preparation.

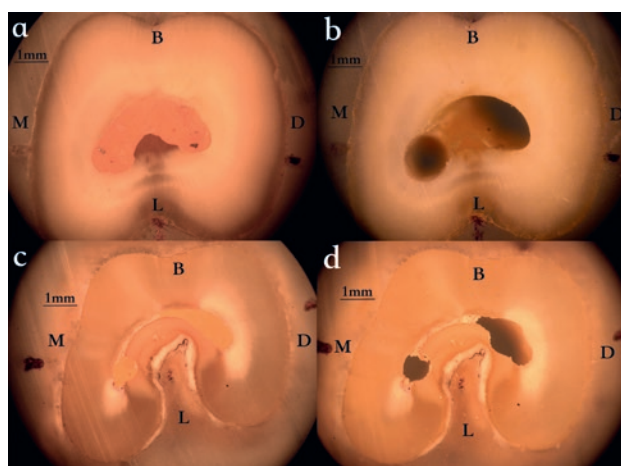


Fig 7 Canal morphology in the PR group: (a) 4 mm cross-section before post preparation; (b) 4-mm cross-section after post preparation; (c) 7-mm cross-section before post preparation; (d) 7-mm cross-section after post preparation.

C3 shapes are more complicated than C1 shape, and also more vulnerable to perforation and thus present a greater challenge during endodontic and prosthetic treatments, so if two of the three sections (orifice, 4 mm and 7 mm below the CEJ) were C2 or C3 shape, we classified the tooth as difficult in terms treatment difficulty. If all three sections of the tooth were C1 shape, we classified it as easy in terms of treatment difficulty (Table 2). Each group had the same number of teeth for different levels of treatment difficulty.

The reduction of residual dentine thickness at the two cross-sections in the HU group was less than that in the PR group. Comparison of the distolingual measured point at the 7-mm cross-section below the CEJ showed a significant intergroup difference (*P* < 0.01). Notably,

this region was at particularly high risk of lateral perforation (Fig 7d).

The mechanical method used in the PR group is widely accepted in clinical settings as a routine post preparation technique that uses sequential enlarging instruments and shaping instruments to prepare the internal root canals according to root length, morphology and diameter. The complexity and irregularity of the C-shaped canal system increase the level of risk faced during the preparation process. First, the thin lingual canal wall is apt for excessive enlargement and perforation. Second, when rotary instruments are used to remove excess gutta-percha and the undercut area from the canal system that has been endodontically treated, the residual dentine thickness and fracture

resistance will be decreased again. Third, long and narrow canals make it difficult to maintain the length of apical sealing, resulting in either excessive or insufficient post preparation. However, heat and ultrasonic instruments avoid the shortcomings of avoid rotary instruments as far as possible, because after the majority of gutta-percha has been removed using a heat carrier, the long and thin ET 20D ultrasonic working tip can only remove residual gutta-percha and undercut by vibration without overcutting the dentine, so this modified method can follow the original shape of the root canal and reduce the amount of tooth preparation. It has been proven that the residual dentine thickness is a determining factor for endodontically treated teeth to resist fracture¹⁴⁻¹⁶. Any operation that could reduce dentine thickness, such as anticurvature motion, could be related to vertical root fracture^{17,18}.

It is reported that in C-shaped roots of mandibular molars, the mean values for the minimal width of the lingual canal wall in the middle and coronal thirds were 0.95 ± 0.41 mm and 1.49 ± 0.54 mm, respectively²¹. Both the buccal and lingual canal walls were frequently narrower at mesial locations than distal locations. Thinner lingual walls of C-shaped canals are at higher risk of root perforation during canal shaping and post preparation procedures²¹, and the present study showed similar results. Before post preparation, the dentine width of the mesiolingual and distolingual walls at the 7-mm cross-section below the CEJ was 0.706 ± 0.142 and 0.662 ± 0.149 mm, respectively. The minimal residual thickness of the mesiolingual wall was merely 0.2 mm. Although there was an outer layer of enamel, the risk of perforation and vertical root fracture was still considerably high. The closer to the apical area, more complicated the canal morphology and the thinner the canal wall, the greater the risk of perforation. The mechanical method, even with the smaller enlarging rotary instrument, destroyed the initial morphology of the canal system when performing post preparation (Fig 7). In this experiment, we only prepared the post space using a size 2 Peeso Reamer to simulate clinical practice; if a size 3 Peeso Reamer had been used, the risk of lateral perforation at the mesiolingual and distolingual walls would have been significantly increased. At the 4-mm cross-section below the CEJ, regardless of the method used to prepare the post canals, the mean width of the mesiolingual and distolingual residual dentine walls of the mandibular second molars was still wider than 1 mm. However, at the 7-mm cross-section below the CEJ, the mean width of the lingual residual dentine wall was already thinner than 1 mm before post preparation. These results suggest that when teeth with

C-shaped canals are restored using a post crown, the prepared post depth should preferably not exceed 4 mm below the CEJ.

Little research has been conducted into how to safely perform post preparation for mandibular second molars with C-shaped root canal configurations. A safe, reasonable and feasible method of restoring C-shaped canal systems is urgently required. This study proposed a new modified post preparation technique that follows the original canal morphology and preserves the residual dentine thickness as much as possible. This modified method also reduced the perforation risk, using heat and ultrasonic instruments to increase the root fracture resistance and long-term effects of the restoration. The method can also be used to restore other teeth with C-shaped, funnel-shaped, curved, short and irregular canals.

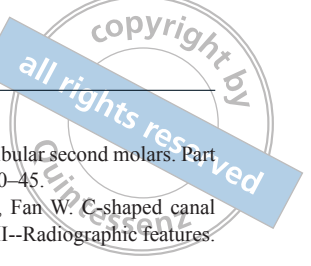
The present study has some limitations. First, to eliminate the difference in the endodontic and post preparation operations between the left and right sides in the dental simulation training system, only the right mandibular second molars with C-shaped canal configurations were selected. Second, because the thickness of the lingual wall of the mandibular second molars with C-shaped canal systems is less than 1 mm, it was preferable to choose a detection device with higher measurement accuracy, such as microcomputed tomography (microCT). In the results, the group 7 mm below the CEJ cross-section had a higher standard error. It was inferred that the reduction of residual dentine thickness was imperceptible and the precision of the detection device was not good enough to measure it. In addition, due to the complexity of C-shaped canal systems, it may be necessary to expand the sample size to compensate for variation in future studies.

Conclusion

Using heat and ultrasonic instruments to prepare post space follows the canal's initial morphology. It saves the tooth structure significantly and decreases the risk and incidence of perforation. The lingual canal wall is a high-risk area for perforation in mandibular second molars with a C-shaped canal system. C2- and C3-shaped canals showed a higher risk of perforation than C1-shaped canals. In addition, the shorter the distance from the apex, the higher the perforation risk.

Acknowledgements

The authors would like to appreciate Dr Zhi Hui SUN for his contribution to and support of this study.



Conflicts of interest

The authors declare no conflicts of interest related to this study.

Author contribution

Drs Si Yu LI and Jie PAN conceived and designed the in vitro study, performed the study, collected and analysed the data and prepared the manuscript; Dr Yi Hong LIU performed the study; Dr Ke Yi HAO prepared the manuscript. All authors reviewed the manuscript.

(Received Apr 14, 2020; accepted Sep 03, 2020)

References

- Cooke HG 3rd, Cox FL. C-shaped canal configurations in mandibular molars. *J Am Dent Assoc* 1979;99:836–839.
- Sidow SJ, West LA, Liewehr FR, Loushine RJ. Root canal morphology of human maxillary and mandibular third molars. *J Endod* 2000;26:675–678.
- Weine FS. The C-shaped mandibular second molar: Incidence and other considerations. Members of the Arizona Endodontic Association. *J Endod* 1998;24:372–375.
- Haddad GY, Nehme WB, Ounsi HF. Diagnosis, classification, and frequency of C-shaped canals in mandibular second molars in the Lebanese population. *J Endod* 1999;25:268–271.
- Yang ZP, Yang SF, Lin YC, Shay JC, Chi CY. C-shaped root canals in mandibular second molars in a Chinese population. *Endod Dent Traumatol* 1988;4:160–163.
- Seo MS, Park DS. C-shaped root canals of mandibular second molars in a Korean population: Clinical observation and in vitro analysis. *Int Endod J* 2004;37:139–144.
- Jin GC, Lee SJ, Roh BD. Anatomical study of C-shaped canals in mandibular second molars by analysis of computed tomography. *J Endod* 2006;32:10–13.
- Jafarzadeh H, Wu YN. The C-shaped root canal configuration: A review. *J Endod* 2007;33:517–523.
- Barnett F. Mandibular molar with C-shaped canal. *Endod Dent Traumatol* 1986;2:79–81.
- Gao Y, Fan B, Cheung GS, Gutmann JL, Fan M. C-shaped canal system in mandibular second molars part IV: 3-D morphological analysis and transverse measurement. *J Endod* 2006;32:1062–1065.
- Manning SA. Root canal anatomy of mandibular second molars. Part II. C-shaped canals. *Int Endod J* 1990;23:40–45.
- Fan B, Cheung GS, Fan M, Gutmann JL, Fan W. C-shaped canal system in mandibular second molars: Part II--Radiographic features. *J Endod* 2004;30:904–908.
- Min Y, Fan B, Cheung GS, Gutmann JL, Fan M. C-shaped canal system in mandibular second molars Part III: The morphology of the pulp chamber floor. *J Endod* 2006;32:1155–1159.
- Junqueira RB, de Carvalho RF, Marinho CC, Valera MC, Carvalho CAT. Influence of glass fibre post length and remaining dentine thickness on the fracture resistance of root filled teeth. *Int Endod J* 2017;50:569–577.
- Farina AP, Weber AL, Severo Bde P, Souza MA, Cecchin D. Effect of length post and remaining root tissue on fracture resistance of fibre posts relined with resin composite. *J Oral Rehabil* 2015;42:202–208.
- Marchi GM, Mitsui FH, Cavalcanti AN. Effect of remaining dentine structure and thermal-mechanical aging on the fracture resistance of bovine roots with different post and core systems. *Int Endod J* 2008;41:969–976.
- Tey KC, Lui JL. The effect of glass fiber-reinforced epoxy resin dowel diameter on the fracture resistance of endodontically treated teeth. *J Prosthodont* 2014;23:572–581.
- Pilo R, Shapenco E, Lewinstein I. Residual dentin thickness in bifurcated maxillary first premolars after root canal and post space preparation with parallel-sided drills. *J Prosthet Dent* 2008;99:267–273.
- Fan B, Cheung GS, Fan M, Gutmann JL, Bian Z. C-shaped canal system in mandibular second molars: Part I--Anatomical features. *J Endod* 2004;30:899–903.
- Melton DC, Krell KV, Fuller MW. Anatomical and histological features of C-shaped canals in mandibular second molars. *J Endod* 1991;17:384–388.
- Chai WL, Thong YL. Cross-sectional morphology and minimum canal wall widths in C-shaped roots of mandibular molars. *J Endod* 2004;30:509–512.
- Santos Pantaleón D, Morrow BR, Cagna DR, Pamejier CH, Garcia-Godoy F. Influence of remaining coronal tooth structure on fracture resistance and failure mode of restored endodontically treated maxillary incisors. *J Prosthet Dent* 2018;119:390–396.
- Uğur Aydın Z, Keskin NB, Özyürek T, Geneci F, Ocak M, Çelik HH. Microcomputed assessment of transportation, centering ratio, canal area, and volume increase after single-file rotary and reciprocating glide path instrumentation in curved root canals: A laboratory study. *J Endod* 2019;45:791–796.
- Wang MQ, He S. *Oral Anatomy and Physiology*, ed 7 [in Chinese]. Beijing: People's Medical Publishing House, 2012.