

Alice Josephine Müller, Simon Peroz, Frank Peter Strietzel

Implant-prosthetic rehabilitation using individualized allogeneic bone blocks for bone defects caused by peri-implantitis

Introduction: Implant-prosthetic rehabilitation after previous implant loss due to peri-implantitis and periodontitis is considered to be challenging and risky, as the remaining alveolar process defects are often extensive and may also affect neighboring regions. A 68-year-old female patient with advanced peri-implantitis in region 44 and a severely atrophied alveolar ridge in region 32–41 requested a new fixed implant-prosthetic restoration of the lower jaw. The patient had an inconspicuous general medical history and previous periodontitis therapy had been performed. Subsequent to explantation at site 44, pronounced horizontal and vertical defects of the alveolar ridge in region 44 to 46 and in region 32 to 41 were identified both clinically and using 3D radiographic imaging (cone-beam computed tomography, CBCT). Prior to implant planning, the status of peri-implantitis and periodontitis was re-evaluated, as there was a suspicion of residual cement-associated peri-implantitis, which could have resulted in implant loss.

Material and Methods: Two patient-specific allogeneic bone grafts were made using CAD-CAM (Maxgraft bone builder, Botiss, Zossen, Germany) and were securely introduced for bone defect reconstruction. Despite dehiscence in region 31, both transplants showed revascularization and integration after 6 months. Implant placement ensued in regions 31, 41, 44 and 46. Thereafter, a fixed implant-supported restoration could be successfully applied 3 months later.

Results: This case report demonstrates that satisfactory bone defect reconstruction, meeting both functional and esthetic criteria, is possible even subsequent to peri-implantitis, explantation and rigorous periodontal pretreatment of chronic marginal periodontitis by means of a two-staged surgical approach. A small dehiscence above the allograft did not curtail the overall result of the augmentation. Long-term studies must show the extent to which the augmentation result remains stable.

Keywords: implant-prosthetic rehabilitation; peri-implantitis; periodontitis; allogeneic grafts

Charité – Medical University Berlin, Charité Center 3 for Dental, Oral, and Maxillary Medicine, Department for Oral Medicine Dental Radiology, and Oral Surgery (Head: Univ.-Prof. Dr. Andrea-Maria Schmidt-Westhausen); Dr. Alice Josephine Müller, PD Dr. Frank-Peter Strietzel

Charité – Medical University Berlin, Charité Center for Dental, Oral, and Maxillary Medicine, Department of Prosthodontics, Geriatric Dentistry and Craniomandibular Disorders (Director and Chairman: Univ.-Prof. Dr. F. Beuer); Simon Peroz

Translation from German: Christian Miron

Citation: Müller AJ, Peroz S, Strietzel FP: Implant-prosthetic rehabilitation using individualized allogeneic bone blocks for bone defects caused by peri-implantitis. *Dtsch Zahnärztl Z Int* 2020; 2: 008–013

Peer-reviewed article: submitted: 12.07.2019, revised version accepted: 30.10.2019

DOI.org/10.3238/dzz-int.2020.0008–0013

Introduction

Implant-prosthetic rehabilitation of extended horizontal and vertical bone defects due to previous peri-implantitis in conjunction with explantation is considered to be challenging. Often, crater-shaped peri-implant bone defects are extensive and they can additionally affect neighboring regions. Their specific and highly individual geometry makes the selection of a suitable augmentation procedure for reconstruction difficult. Currently, the reconstruction of pronounced alveolar process defects with autologous bone grafts is the gold standard. The high degree of difficulty associated with this surgical procedure together with donor site morbidity and the longer duration of the operation are fueling the desire to find alternative methods: one possibility is the use of custom-made allografts.

Case report

Patient presentation: A 68-year-old female patient with an inconspicuous general medical history presented herself to the Department of Oral Medicine, Dental Radiology and Surgery at the Charité Center for Dental, Oral, and Maxillary Medicine of the Charité-Medical University in Berlin with the wish for a new fixed prosthetic, or more specifically, implant-prosthetic restoration. Preliminary examinations had already been carried out by several dentists; the patient was repeatedly shown that the implant 44 and the tooth 45 were not worth preserving and that a new fixed implant-prosthetic restoration was not possible due to the pronounced bone defects in the lower jaw. Nevertheless, the patient had a

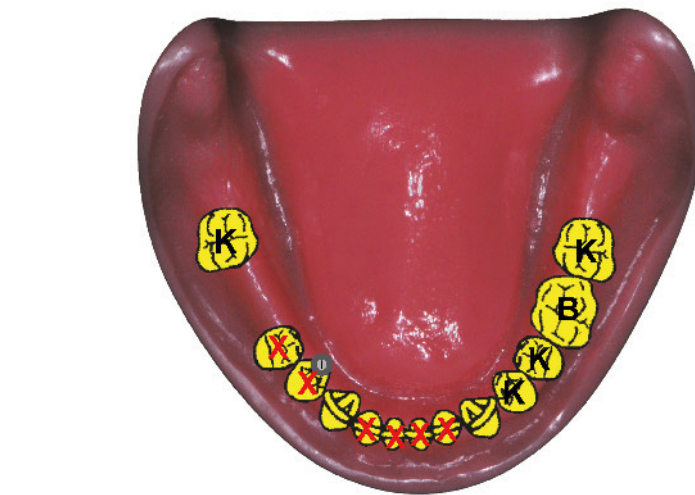


Figure 1 Initial situation

strong desire to be treated with a fixed restoration (Fig. 1 initial situation).

Additional findings

In the lower jaw, it was revealed that teeth 32–42 were not worth preserving due to an advanced marginal periodontitis and that teeth 43 and 33 required crowns owing to pronounced abrasion. Due to chipped ceramic veneering and insufficient crown margins, the crowns on teeth 34 and 47 were in need of renewal, as was the bridge on teeth 35 to 37. Additionally, all crowns in the maxilla were found to be in need of renewal due to insufficient crown margins (teeth 15–25, 27 and implants 17, 16 and 26). The implants showed incipient horizontal bone loss and the endodontic treatment of tooth 21 needed revision due to over-pressed root canal filling material. Although

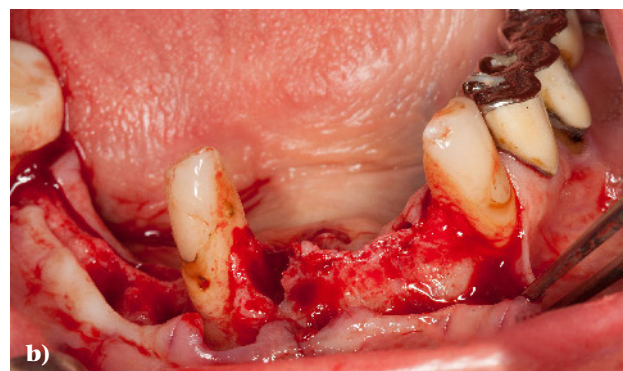
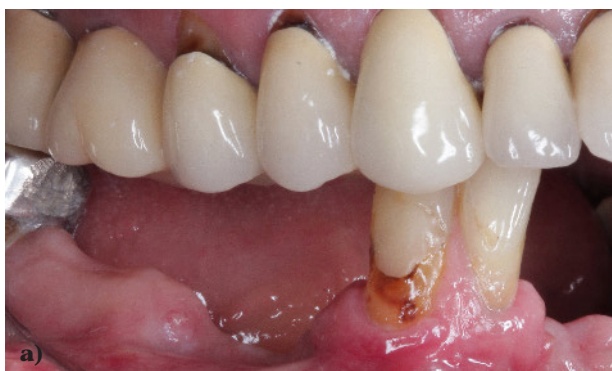the teeth displayed no apical lesions, cervical bone loss was evident.

Therapeutic alternatives

Alternatively, a removable denture could have been made for the lower jaw. To achieve this, a telescopic bridge/removable denture or a partial cast denture anchored by means of clasps could have been plausible. A fixed restoration was only possible using implants in this case.

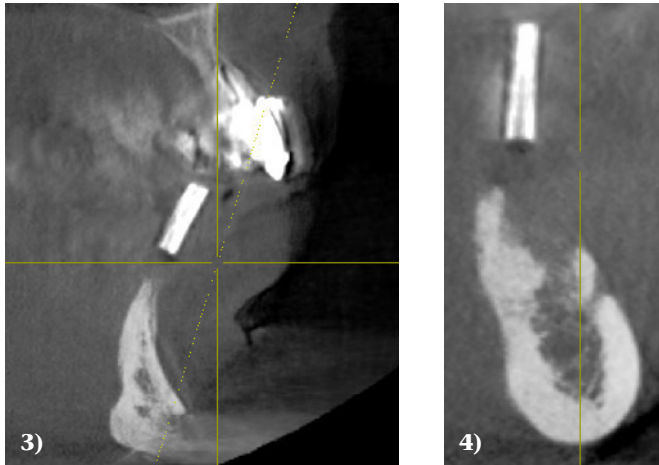
Treatment

First, the explantation of 44 and the extraction of tooth 45 was performed. The ensuing partial edentulous dentition was treated with a periodontally-supported temporary splint. After the wound healing phase was complete, a 3D X-ray using radiopaque reference markers (X-ray template with titanium sleeves [10 mm long] in the regions 46, 44, 32, 41 ac-



(Fig. 2a: S. Peroz, fig. 2b: A.J. Müller)

Figure 2a Clinical condition regio 32 and regio 44/45, **2b** intraoperative condition after flap formation



Figures 3 und 4 CBCT imaging in region 32 und region 44/45 (Galileos, Dentsply Sirona, Bensheim, Germany)

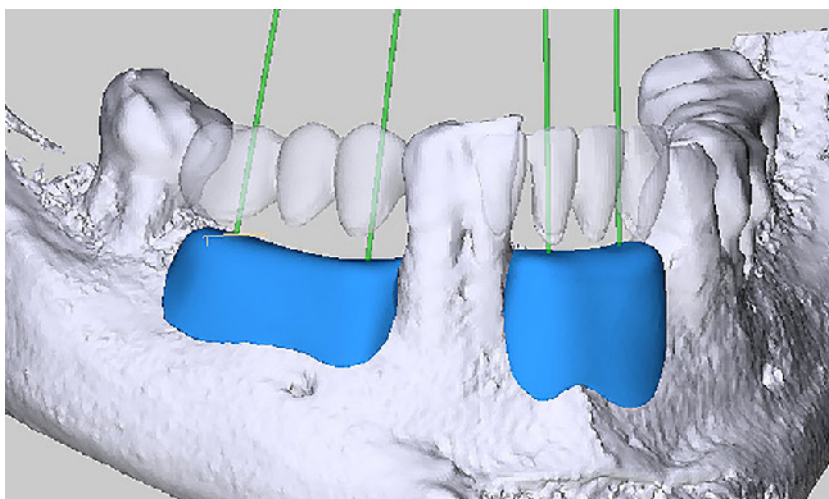
cording to the previously prepared diagnostic model of the missing teeth) was made. CBCT imaging revealed pronounced horizontal and vertical alveolar process defects in these regions, which at first excluded implantation and necessitated a multi-step approach (Fig. 3 and 4). In addition, the commonly used intraoral donor sites for autologous grafts were considered to be dimensionally too small. The use of autologous bone grafts was therefore eliminated as a treatment alternative. The suggestion of augmentation using patient-specific allogeneic bone blocks ensued (Maxgraft Bone Builder, Botiss, Zossen, Germany). The patient was fully informed with regard to other existing treatment options (in-

cluding iliac crest grafting and the use of bone substitute material in particulate form as part of a controlled bone regeneration with the creation of a compartment) with the associated benefits and risks as well as the expected costs. Maxgraft Bone Builder are custom-made allogeneic transplants that are prepared preoperatively by means of digital three-dimensional planning (SMOP, Swissmeda AG, Baar, Switzerland) (Fig. 5) and match the patient's bone defect site (Fig. 1). They are obtained from the Cells+Tissuebank Austria (tissue bank) from the femoral heads of living donors and processed in several steps. They undergo various antigen and serological tests to exclude the transmission of infections. The bone

blocks are prepared by means of ultrasonic baths (cleaning from blood, cell and tissue components), diethyl ether and ethanol rinsing (denaturation of non-collagen protein and pathogens), oxidative treatment (elimination of potential antigens), lyophilization (preservation of structure and residual moisture) and final gamma radiation (sterilization and preservation). Through this manufacturing process, the open porous cancellous bone structure is preserved with a pore size of 100–1800 μm (data according to the manufacturer) [5, 10].

For the patient, 2 patient-specific allografts were prepared using the method described above. Following cortical conditioning at the recipient sites and after rehydration of the grafts using autogenous plasma fraction enriched with growth factors (PRGF Endoret Phase 2, BTI, Karlsruhe, Germany), the 2 grafts were fixed with 2 osteosynthesis screws (Minischrauben, Straumann, Freiburg, Germany) (Figs. 6 and 7), each of which was inserted from vestibular. Subsequent to the mobilization of each respective vestibular mucosal periosteal flap and the covering of the transplants with fibrin membrane (PRGF Endoret, Phase 1, BTI, Karlsruhe, Germany), tension-free, primary wound closure ensued. During the healing phase of the grafts, the patient wore the adapted periodontally-supported temporary splint as much as possible in order to protect the augmented sites from mechanical stress. In addition, systemic antibiotic prophylactic therapy (amoxicillin) was administered perioperatively for 7 days (2 g amoxicillin beginning one hour preoperatively, then 1 g every 8 hours). The wound healing proceeded without complications and, according to the patient, was almost painless. Monthly controls of the augmentation area were performed. Shortly before the end of the 6-month healing phase, a small dehiscence was observed in region 31. The surrounding tissues were free of any irritation.

Before planning the subsequent implantation, a radiographic re-evaluation of the augmented bone was made. An increase in vertical and

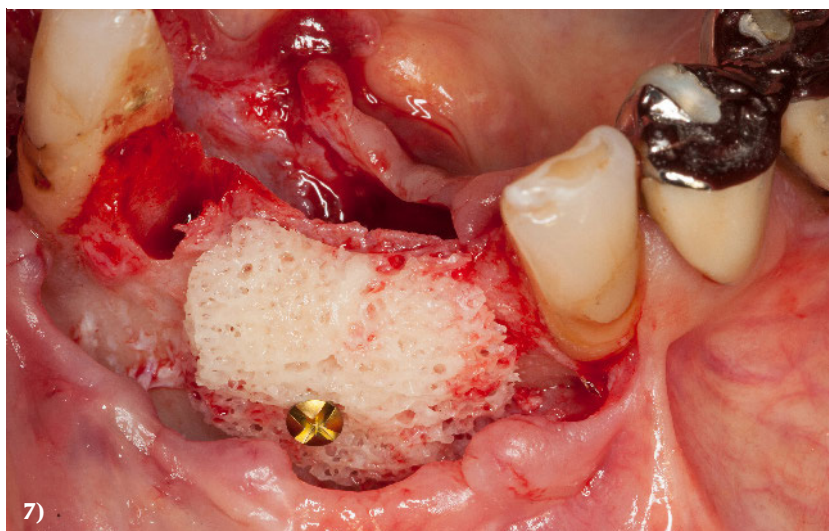
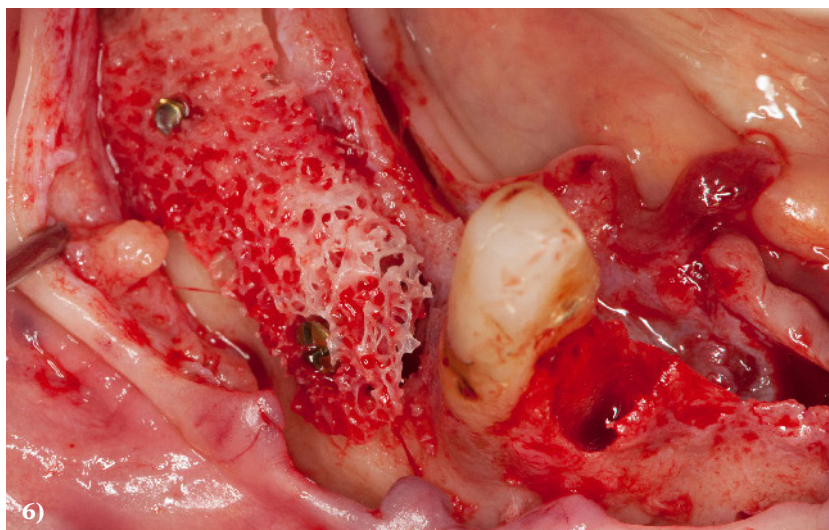

(Fig. 5: Christin Hohmann, Botiss biomaterials GmbH, Zossen)

Figure 5 3-D planning from the company Botiss (Straumann, Freiburg, Deutschland) mit SMOP (Swissmeda AG, Baar, Schweiz)

transversal bone supply for implantation was seen in both clinical and radiographic examinations. Implant planning was carried out after calibration of the PSA using 10 mm long divisible X-ray, or more specifically, drill sleeves and measurement of the regions 32, 41, 44 and 46 that were to receive implants.

The osteosynthesis screws were removed immediately before placing the implants. In the area of the osteosynthesis screws, the allografts displayed a resorption of approximately 1.5 mm (Fig. 8) in the horizontal dimension. Both grafts underwent osseointegration and vascularization. The implants of type Astra EV (Dentsply, Sirona, Bensheim, Germany) were inserted as planned in regions 32, 41, 44 and 46 (Figs. 9 and 10). Furthermore, controlled bone regeneration using bovine bone graft substitutes (Bio Oss, Geistlich Biomaterials, Waldenburg, Switzerland) and a porcine collagen membrane cover (Bio Gide, Geistlich Biomaterials, Waldenburg, Switzerland) were used to protect against resorption and to cover the vestibular implant shoulder in regions 41, 44 and 46. Here too, an accompanying systemic antibiotic therapy with amoxicillin was also administered. Wound healing took place free of any complications. After another 3 months, the implants were exposed and additional vestibuloplasty was performed in regions 32 to 42 and 44 to 46; the multiple augmentations with the associated mobilization of the mucosa had shifted the mucogingival border crestally. By means of vestibuloplasty, a sufficiently wide zone of keratinized gingiva in the area of the implants could once again be restored. Three weeks following the operation, old restorations were removed and the teeth 37, 35, 33, 43 were prepared; the subsequent impression with simultaneous bite registration and face bow application took place. A set-up for trial fitting as well as the custom-milled titanium abutments was fabricated in the dental laboratory (Zahntechnik Mehlhorn, Berlin). Minor chair-side esthetic and functional corrections were made. All bridges and crowns in the lower jaw were made of zirconia with individ-



Figures 6 und 7 Intraoperative situation after fixation of the patient-specific allografts (Maxgraft Bone Builder®, Botiss, Zossen, Deutschland)

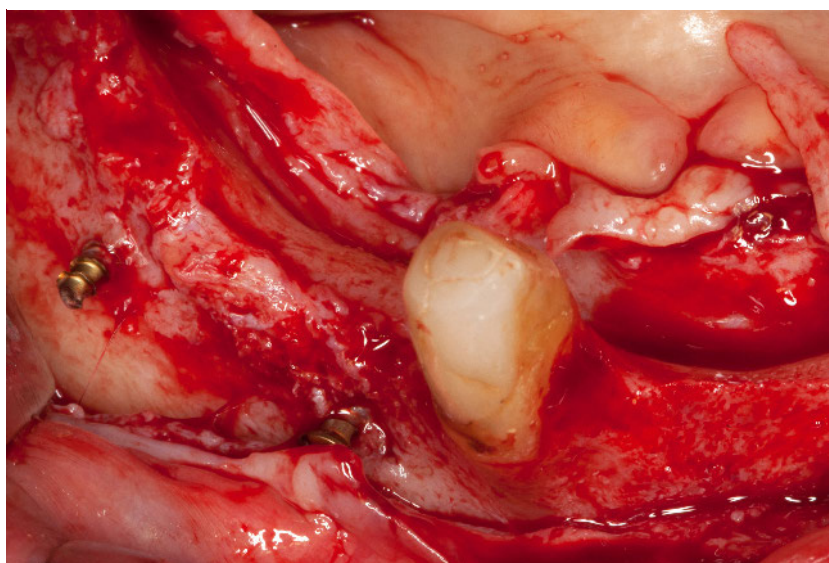
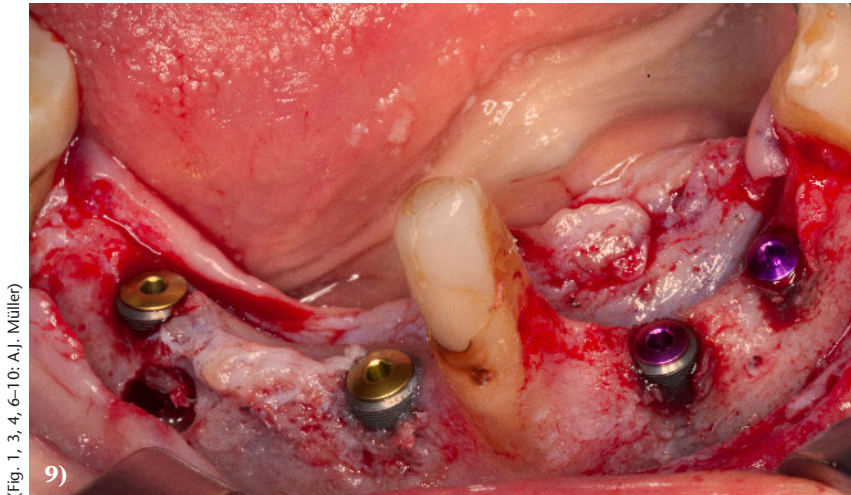
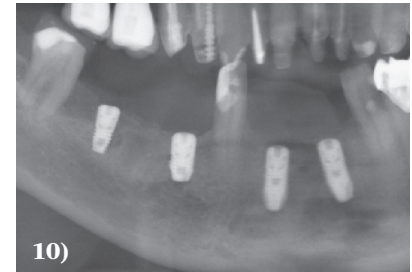


Figure 8 Status after the 6-month healing phase, approx. 1.5 mm resorption is noticeable in the area of the screw heads



(Fig. 1, 3, 4, 6–10: A.J. Müller)



Figures 9 und 10 Status after the removal of the osteosynthesis screws and implant insertion in regions 32, 41, 44, 46, “subsequent augmentation” in region 41, 44 and 46.

ualized ceramic veneering. All tooth-supported crowns and bridges were permanently cemented (Ketac Cem, 3M, Neuss, Germany), while all implant-supported bridges were semi-permanently cemented (Improv, Dentegris, Monheim am Rhein, Germany) (Fig. 11 and 12). At the time when rehabilitation of the mandible was complete, the maxillary teeth were still treated with PMMA-milled long-term provisionals.

Follow-up

The first check-up took place 3 months after the prosthetic treatment and normal peri-implant tissue was seen.

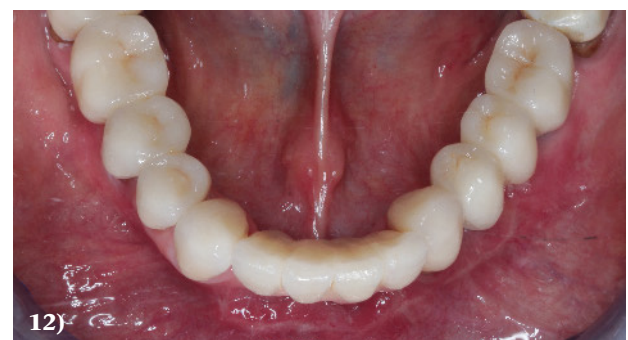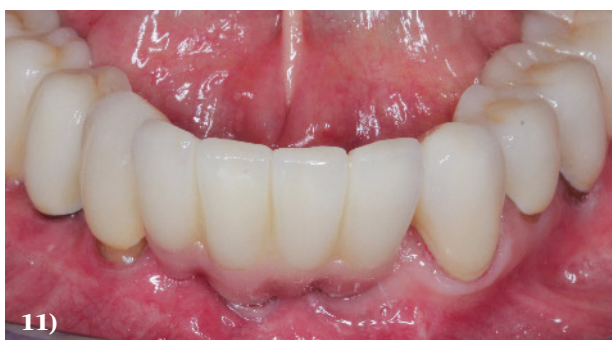Discussion and Epicrisis

In cases of extensive alveolar ridge defects, advanced patient age and multiple revision treatments, the limits are reached for obtaining autologous bone grafts from intraoral donor regions for the purpose of treating affected regions. Iliac crest

transplantation, which is the alternative, deters many patients and is associated with a certain morbidity following bone removal [12] as well as an inpatient stay.

In an intraoperative context, CAD/CAM (“computer-aided design” and “computer-aided manufacturing”) milled patient-specific bone blocks (Maxgraft Bone Builder) offer the advantage of a relatively short operation time due to the accurate fit of the grafts. The large contact area between the graft and donor site facilitates exchange at the interface to occur, as well as revascularization and osseointegration by continuous substitution of the augmentation with own bone [2]. The chosen volume of the patient-specific allogeneic bone block is not allowed to be too large, so that revascularization at the surface and the remodeling process are ensured [3]. Also, the thickness of the covering mucosa is decisive for the success of the augmentation; with this in mind, the maxilla is theoretic-

cally, with an average mucosa thickness of 3 to 6 mm, more suitable than the mandible for transplant use; this is because a proportionally thicker mucosal membrane facilitates both tension-free wound closure as well as nourishment of the periosteal mucosa flap [11]. For a long time, there have been varied opinions regarding the potential risk of disease transmission from donor to recipient through the use of allografts; however, since the introduction of DNA-based blood tests as well as the preparation of the grafts by solvent dehydrogenation, oxidative treatment and gamma irradiation, no cases of disease transmission from donor to recipient have been demonstrated [4]. Moreover, the issue of antigenicity to the human leukocyte antigen (HLA) is also driven into the background by the multi-step processing techniques of allogeneic bone grafts, which are used nowadays. To date, antigenicity has been observed especially in connection to cryopreservation [7, 8]



(Fig. 11 und 12: S. Peroz)

Figures 11 und 12 Status after completion of implant-prosthetic treatment

and freshly frozen allografts [9]. A detailed explanation of the type, origin and characteristics of the intended bone substitute material is required in each case [1]. When comparing autologous and allogeneic grafts, Kloss et al. found similar resorption rates after a 12-months observation period based on radiographic controls [6]. This can, like in the course of the present treatment, make an additional augmentation necessary afterwards; however, the augmentation can nonetheless be performed concomitantly with implant placement.

Especially in the production of a prosthesis fixed on implants, red-white esthetics plays a major role and this can only be achieved satis-

factorily if defect reconstruction also takes place in the vertical direction. In the present case, this was fully achieved only in regions 44 to 46; in regions 32 to 42, additional pink ceramic needed to be used to compensate for the missing gingival height.

Conclusion

In overview of all factors, allogeneic patient-specific bone blocks represent an alternative to autologous bone blocks or the shell technique for the reconstruction of alveolar process defects. By means of digital planning and diagnostics using CBCT, possible augmentation procedures can be evaluated and discussed with the patient together. The lower morbidity and shorter operation time (given

that bone harvesting and adaptation of autologous bone blocks are not necessary) are important arguments in selecting a suitable augmentation technique. Long-term follow-up studies must show the extent to which the augmentation results remain stable and how the retention rates of the implants in a reconstructed implant-bearing tissue of this type develop.

Conflicts of interest:

The authors declare that there is no conflict of interest within the meaning of the guidelines of the International Committee of Medical Journal Editors.

References

1. Benz K, Buchbinder B, Strietzel FP, Fehn BJ, Jackowski J: Allografts und Aufklärung – Schutz für Patienten und Behandler. *Quintessenz Zahnmedizin* 2019; 70: 8
2. Burchardt H: The biology of bone graft repair. *Clin Orthop Relat Res* 1983; 174: 28–42
3. Fretwurst T, Spanou A, Nelson K, Wein M, Steinberg T, Stricker A: Comparison of four different allogeneic bone grafts for alveolar ridge reconstruction: a preliminary histologic and biochemical analysis. *Oral Surg Oral Med Oral Pathol Oral Radiol* 2014; 118: 424–431
4. Hinsenkamp M, Muylle L, Eastlund T, Fehily D, Noel L, Strong DM: Adverse reactions and events related to musculoskeletal allografts: reviewed by the World Health Organisation Project NOTIFY. *Int Orthop* 2012; 36: 633–641
5. www.botiss-dental.com/de/products/maxgraft-bonebuilder-de/
6. Kloss FR, Offermanns V, Kloss-Brandstatter A: Comparison of allogeneic and autogenous bone grafts for augmentation of alveolar ridge defects – a 12-month retrospective radiographic evaluation. *Clin Oral Implants Res* 2018. doi: 10.1111/clr.13380. [Epub ahead of print]
7. Mosconi G, Baraldi O, Fantinati C et al.: [Anti-HLA antibodies after bone graft and their impact on kidney transplant programs]. *G Ital Nefrol* 2009; 26 (Suppl 45): S58–63
8. Mosconi G, Baraldi O, Fantinati C et al.: Donor-specific anti-HLA antibodies after bone-graft transplantation. Impact on a subsequent renal transplantation: a case report. *Transplant Proc* 2009; 41: 1138–1141
9. O’Sullivan ED, Battle RK, Zahra S, Keating JF, Marson LP, Turner DM: All sensitization following bone graft. *Am J Transplant* 2017; 17: 2207–2211
10. Pecanov-Schröder A: Allogene Transplantate – sicher wie Arzneimittel. *Implantologie Journal* 2017; 12: 4
11. Plöger M: Autologe Blocktransplantate bei Hypodontie lateraler Inzisivi. *Implantologie Journal* 2019; 5: 8
12. Sudhakar KNV, Mohanty R, Singh V: Evaluation of donor site morbidity associated with iliac crest bone harvest in oral and maxillofacial, reconstructive surgery. *J Clin Diagn Res* 2017; 11: ZC28–ZC33



(Photo: Elmar Wurster, Charité Berlin)

DR. ALICE MÜLLER
Charité – Medical University Berlin,
Charité Center 3 Dental, Oral and
Maxillofacial Surgery
Division of Oral Medicine, Dental
Radiology and Surgery
Aßmannshauser Str. 4-6
14197 Berlin
alice.mueller@charite.de