

Roland Frankenberger, Marie-Christine Dudek, Norbert Krämer, Julia Winter, Matthias J. Roggendorf

# The 10 most popular mistakes in adhesive dentistry

## Abstract

Adhesive dentistry dominates the spectrum of restorative dentistry today. While there have been significant improvements in composites as well as adhesive systems, certain fundamental prerequisites are still essential to be clinically successful. This review highlights the 10 most important aspects of modern adhesive technology based on the “most popular” mistakes in the clinical protocol: Indication, Contamination, Moisture Control, Evaporation, Polymerization, Dentine Sclerosis, MMP Hype, Preparation, Repair and Function. If these 10 points are successfully addressed, the probability of success in the adhesive technique reaches almost 100%.

**Keywords:** adhesives; contamination; MMPs; resin composites; technique sensitivity

---

Department for Operative Dentistry, Endodontics, and Pediatric Dentistry, Medical Center for Dentistry, Philipps University Marburg and University Hospital Giessen and Marburg, Campus Marburg, Georg-Voigt-Str. 3, 35039 Marburg: Univ.-Prof. Dr. med. dent. FADM Roland Frankenberger, Dr. med. dent. Marie-Christine Dudek, OÄ Dr. med. dent. Julia Winter M.Sc., OA Priv.-Doz. Dr. med. dent. Matthias J. Roggendorf

Department for Pediatric Dentistry, Justus Liebig University Giessen and University Hospital Giessen and Marburg, Campus Giessen, Schlangenzahl 14, 35392 Giessen: Univ.-Prof. Dr. med. dent. Norbert Krämer

Translation from German: Thomas Volmert

**Citation:** Frankenberger R, Dudek M-C, Krämer N, Winter J, Roggendorf MJ: The 10 most popular mistakes in adhesive dentistry. *Dtsch Zahnärztl Z Int* 2022; 4: 111–117

**Peer-reviewed article:** submitted: 21.04.2022, revised version accepted: 31.05.2022

**DOI.org/10.53180/dzz-int.2022.0013**

## Introduction

Figures from dental health care research impressively demonstrate that caries prevention has been successful in the Federal Republic of Germany [17]. Compared to 1991, 48% fewer fillings, 33% fewer extractions and 18% fewer endodontic procedures are performed (Fig. 1) [12, 17].

However, these curves are also an indication that the increasing move away from “Extension for Prevention” and the simultaneous focus on minimally invasive restorative measures from around 1992 onwards were important flanking measures that influenced the course of the curves shown. However, it is striking that at the beginning of this paradigm shift, the numbers of root canal fillings did not initially decrease but increased – a possible explanation for this is that the overwhelming majority of colleagues now working with adhesives had never learned fundamental content of adhesive dentistry in their studies. The “endo curve” thus reflects nothing more than an adhesive learning curve at the beginning of the restorative paradigm shift towards composites and ceramics. The fact that every dental adhesive technique is characterized by con-

siderable technique sensitivity and at the same time benefits substantially from the skills of the practitioner has been amply demonstrated [8, 10]. Although the measurable reduction in polymerization shrinkage of composites over the past 30 years, as well as the evolution of adhesive systems, have simplified many daily routine steps today [2, 5, 6, 16], fundamentally important factors of successful adhesive technique still persist and are critical to clinical success. These are highlighted below.

## 1. Indication: composite first, ceramic second

The mean penetration time of proximal caries through the enamel is 6–8 years [18]. The prioritization of minimally invasive interventions therefore necessarily starts first with arresting, sealing or observing measures to protect healthy tooth structure [19]; minimally invasive excavation is only performed in the second step if these first measures were not successful [19, 23]. Thereafter, the concept of “composite first – ceramic second” is applied, which is based on the chronological preference of direct vs. indirect measures; this does not mean that composite is generally

“better” than ceramic, but that composite should always be the first choice, especially in younger patients, in order to preserve a maximum amount of healthy tooth structure for as long as possible [6]. What is important initially is not how long the selected filling material “lasts” but how long the tooth survives in the oral cavity, and for this minimally invasive adhesive strategies are always preferable to aggressive preparations (and excavations) [11, 16, 19, 23, 25]. However, with increasing age, the described preferences shift toward indirect restorations in some cases, especially when adhesively bonded partial crowns provide effective stabilization of residual tooth structure in fractured cusps or those weakened by preexisting restorations (especially amalgam) [6, 11]. Today, crowns on vital teeth are a last resort because, apart from rare exceptions (circular defects), partial crowns are associated with significantly less dentin wounding and involve substantially fewer concomitant endodontic risks [1]. Another exception are root canal treated teeth with traditionally extensive loss of tooth structure – crowns are also a stable alternative for them [24].

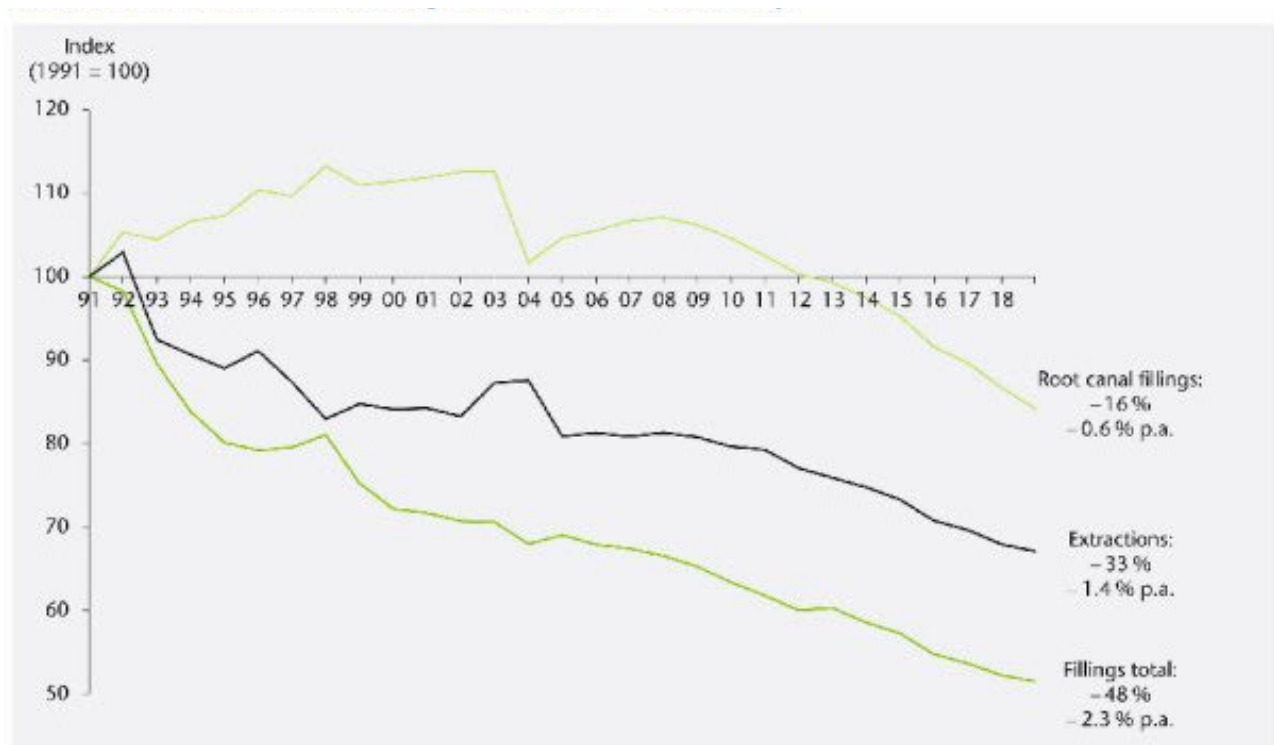


Fig. 1 Fillings, extractions and root canal fillings in the Federal Republic of Germany since 1991.

## 2. Contamination

A contamination-free working field is the No. 1 fundamental prerequisite for adhesive techniques, or to put it the other way round: The No. 1 source of error in the adhesive protocol is contamination of the tooth structure substances by saliva, sulcus fluid, blood, detergents, astringents, lip and skin care products [14]. Even cavity disinfection must be mentioned in this context, as it also represents nothing other than contamination of the tooth structure in comparison with conventional, retentive techniques. A more than questionable disinfection of enamel and dentin is contrasted with a potential reduction in adhesion, which should be weighed up critically. In any case, the author of this review has not performed a “cavity toilet” for 25 years, which is supported by his own data on H<sub>2</sub>O<sub>2</sub> or CHX (Fig. 2).

Rubber dam is often suggested as an “all-purpose weapon” against contamination. This is not realistic either, because especially in the proximally very deep cavities, where the risk of contamination is greatest, rubber dams are extremely difficult to place. Of course, rubber dam is a very good standard that makes many clinical situations much easier, but in the really tricky situations it is not helpful, because especially subgingivally, techniques such as “proximal box elevation” are much more effective than simply applying the rubber dam [7]. And finally, it should not be forgotten that if the proximal depth of the cavity can be controlled, in the event of bleeding, rubber dams work more easily, more quickly and with less contamination than astringents, which sometimes have devastating effects on dentin adhesion [14].

The most dangerous contamination is definitely that which the practitioner does not notice. Then any adhesive technique will hardly be successful. However, if the contamination is detected, decontamination is usually relatively easy to perform by spraying. The most unfavorable time slot for contamination is directly after application of the adhesive, as long as it has not yet polymerized – then the complete process, including finishing, must be repeated.

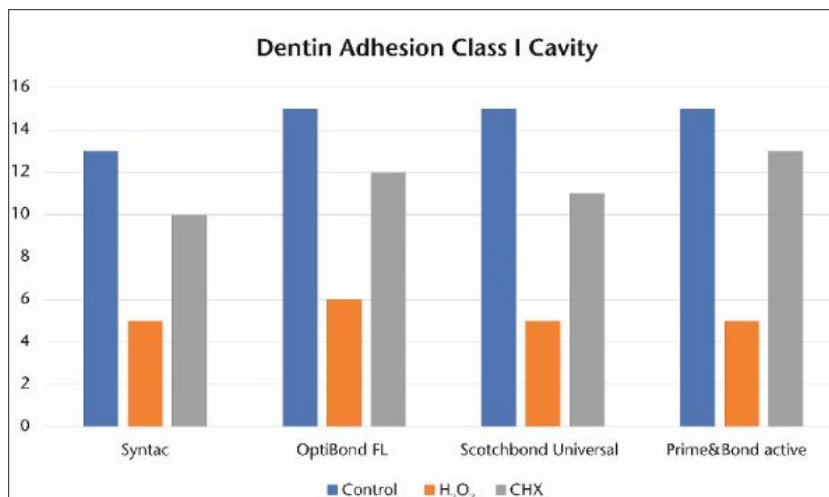


Fig. 2 Influence of “cavity toilet” on dentin adhesion in deep class I cavities (own data).




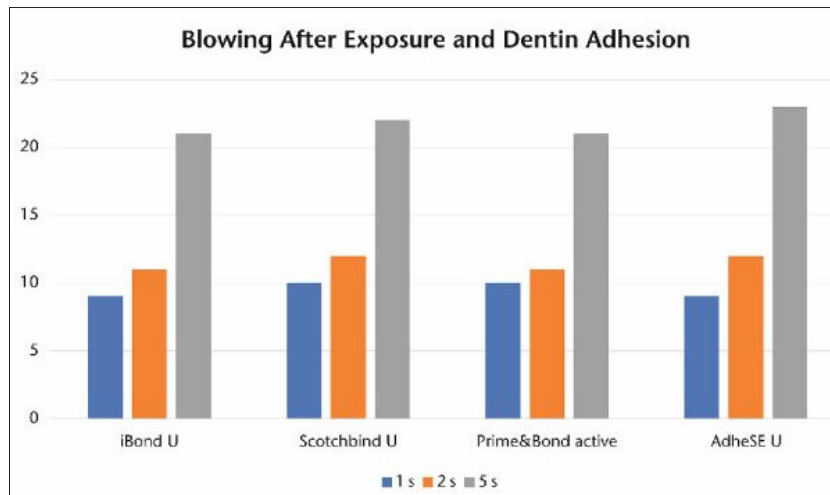
Fig. 3 Dentin surface after “removal” of a eugenol-free temporary cement with pumice powder and brush: almost half of the dentin tubules are still blocked (SEM, 3000× magnification).

Another contamination that should not be underestimated is provisional cement in indirect lab-fabricated restorations. It is difficult to remove completely from the dentin surface (Fig. 3). Therefore, approaches such as “Immediate Dentin Sealing” (IDS) make sense in indirect techniques to prevent dentin contamination [9].

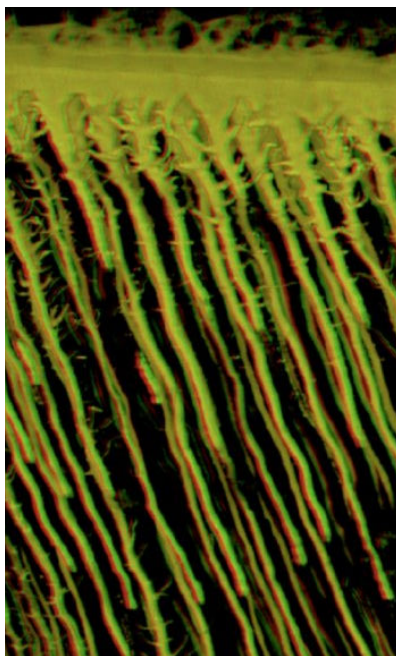
## 3. Moisture control: why “wet bonding” failed

The term “wet bonding” has dominated adhesive dentistry for almost 30 years. If the collagen network is exposed during phosphoric acid etching of the dentin, it is very sensitive to drying and collapses. If an

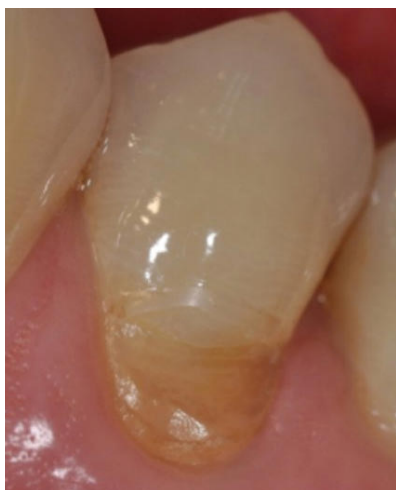acetone-based adhesive is then used – as published by Kanca with All-Bond 2 [15] – (the same applies to ethanol-based systems), hybridization of the dentin surface can only succeed if the dentin is either not dried at all after phosphoric acid etching (which is clinically unwise, since one first wants to be convinced that it is free of contamination) or is re-wetted in a second step (“re-wetting”). However, re-wetting has 3 major clinical disadvantages: 1. It is hardly reproducible. 2. It is dependent on the cavity geometry. 3. It causes emotional problems for the practitioner, who actually wants to work “dry” in the adhesive technique. These 3 aspects mean that the



**Fig. 4** Only complete blowing or better drying of the (universal) adhesive after the reaction time produces good adhesion to the cavity floor.



**Fig. 5** Penetration of resin tags into the dentin during bonding (CLSM, 2000×).



**Fig. 6** Sclerotic dentin in class V.

use of “wet bonding” has never been able to establish itself and will not do so in the future.

An important question to be discussed in the history of adhesive technology is: why were the classic multi-bottle adhesives (Syntac, Opti-Bond FL, ART Bond, EBS Multi, Gluma Solid Bond, Scotchbond Multi-Purpose etc.) so successful in the German market for over 30 years? The answer is simple: because they exhibited virtually no technique sensitivity: as long as the minimum requirement of using the appropriate vials in the correct sequence was met, one could hardly do anything wrong – especially with “wet bonding”. All multi-bottle adhesives contained sufficient water to allow the re-wetting process to be carried out almost by itself without any additional step [21]. All further “developments” that followed in the adhesive sector were 100% marketing-driven “bogus simplifications” in the form of a simple reduction in the number of bottles. However, since all of these adhesives for chemical reasons could no longer contain water, the observed rate of postoperative hypersensitivity increased dramatically [3]. In other words: suddenly adhesive systems were technique sensitive – and many disappointed users returned to the multi-bottle adhesives because they had much fewer problems with them.

It was not until the evolution of universal adhesives about 8 years ago

that an effective reduction in technique sensitivity was again observed, along with chemical coupling to the dentin [5]. In particular, the traditional advantage of the classic multi-bottle adhesives of functioning on etched as well as unetched dentin was again successfully realized, and in the event of unintentional or intentional dentin etching, the universal adhesives are just as successful thanks to innovative solvent concepts (water addition) even without explicit “re-wetting”.

#### 4. Evaporation: please do not “blow gently”


A term often heard in the course of adhesive application is “gently blowing”. This expression is incorrect. Primers or adhesive mixtures contain solvents and often also water, and it is therefore not expedient to gently blow adhesives. “Drying” is the better expression in most cases, because only when there is no more liquid flow in the cavity has the solvent successfully evaporated and dentin adhesion to the cavity floor reaches a good level (Fig. 4).

#### 5. Polymerization

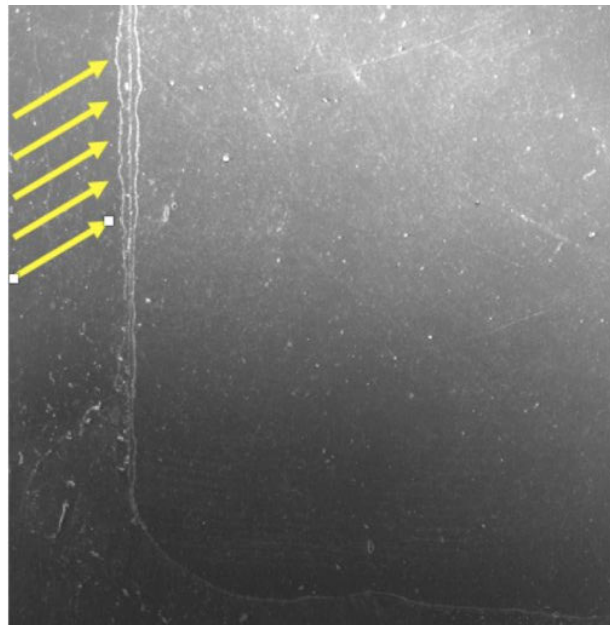
After contamination, light curing ranks second among errors in the adhesive technique. The main sources of error are (a) too short polymerization of the adhesive, (b) unintentional swiveling of the light guide and (c) an ill-conceived polymerization protocol for indirect techniques.

**To (a):** If an averagely thick layer of composite is light-cured for 20 s according to the instructions for use, the same period of time for a 200-fold thinner layer of adhesive seems excessively long. However, this is not a question of polymerization of the adhesive layer at the cavity floor, but of curing of the “resin tags”, which penetrate up to 300 µm deep into the dentinal tubules – through-curing in the opaque dentin thus requires exactly the specified 10 (self-etch) or 20 (etch&rinse) seconds.

**To (b):** Tilting the light guide by as little as 10° reduces dentin adhesion to the cavity floor by more than 50%. Unfavorably bent light guides, reduced mouth opening and careless-



**Fig. 7** Sclerotic deposits in the dentinal tubules in the CLSM (3000× magnification).



**Fig. 8** Paramarginal fractures (arrows) in the absence of proximal enamel bevel (SEM, 100× magnification).

ness of the assistant can easily lead to such and even worse situations [20].

**To (c):** When adhesively cementing indirect restorations, it should be borne in mind that polymerization of light-curing materials through the ceramic is problematic. An average translucent glass-ceramic absorbs approx. 90% of the light energy at a thickness of 4 mm. Furthermore, it is practically impossible to polymerize an adhesive that has not been polymerized separately through the ceramic and luting composite 300 µm into the dentin [9]. One solution would be, for example, a completely dual-curing luting procedure, but this runs the risk of reducing the time required for clean excess removal. Alternatively, we recommend staying with light-curing materials but applying them with IDS and polymerizing a universal adhesive separately [9].

## 6. Dentinal sclerosis

Especially in cervical defects, the dentin is often hypermineralized (Figs 5, 6). It has been repeatedly shown that this type of dentin is an unfavorable bonding surface, which is responsible for numerous failures in class V restorations. The most effective approach in adhesive restorative therapy is to remove the hypermineralized sur-

face with a coarse diamond bur; this improves adhesion enormously [22].

## 7. MMP hype

It has been known from basic science for over a decade that dentin adhesion has many enemies: intrinsic moisture, hydrolysis and enzymatic degradation [13]. Much research has been conducted on the latter in particular, in order to effectively combat a potential “weak link” in adhesive technology [13]. A widely favored agent is chlorhexidine digluconate, which is said to have MMP-inhibiting properties [4, 13].

These studies are scientifically interesting and in part quite innovative, but by no means justify a significant change in the clinical protocol [13]. As described under “contamination”, the following still applies: CHX and other cavity disinfection or stabilization measures are primarily nothing more than contamination and are sufficiently suspected of reducing the effectiveness of the adhesive technique (Fig. 2). Therefore, nothing beats a clean, contamination-free cavity.

## 8. Preparation

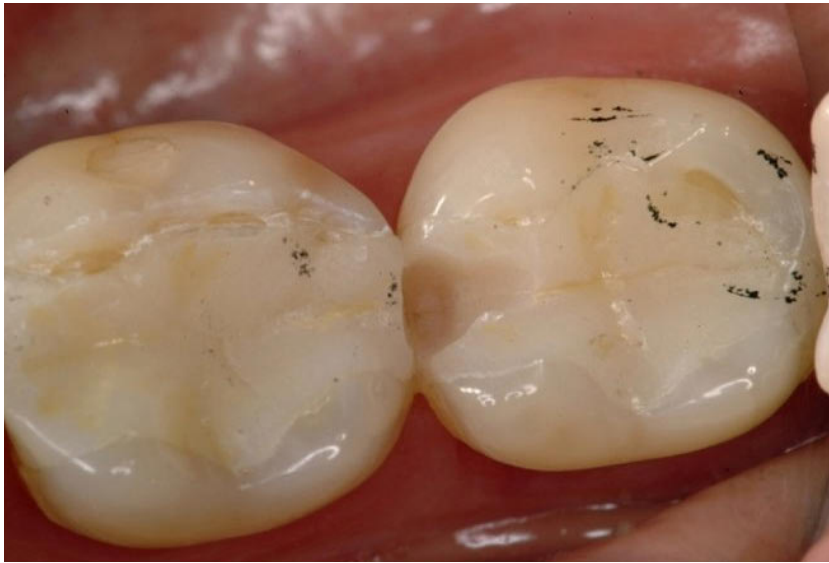Preparation errors can also contribute to the longevity of adhesive restorations. The main errors are (a) the

handling of unground enamel, (b) beveling of the enamel margin and (c) too timid preparation geometries in indirect restorations.

**To (a):** When bonding to unpolished enamel, e.g. for diastema closure, 60 s of enamel etching are recommended. However, this only applies to very young patients, e.g. for diastema bonding after orthodontic treatment. If older patients are bonded to unprepared enamel, a more invasive procedure is recommended in relation to their age. In other words, for a 60-year-old, this may even involve roughening with a diamond bur. Bonding in self-etch mode without phosphoric acid is contraindicated in these cases anyway.

**To (b):** According to our clinical studies, an enamel margin chamfer is not an indispensable prerequisite for clinical success in composite restorations in the posterior region. However, since paramarginal fractures (so-called “white lines”) are formed at the cavity margin without proximal beveling due to the polymerization “pull” (Fig. 8), a narrow beveling in the sense of “edge breaking” is still useful.

**To (c):** Leaving severely weakened cusps in (laboratory-fabricated) indirect restorations is usually a mistake in the long term (Fig. 9). The same



**Fig. 9** Ceramic inlays with preparation margin of weakened cusps at cusp tip level, situation after 8 years.

applies to preparation margins at cusp tip level (regardless of whether direct or indirect restorations are used), as they almost always cause problems later on. In these cases, “minimal invasiveness” is counterproductive [11].

## 9. Repair

The 5 pillars of minimally invasive tooth preservation are prevention, excavation, preparation, sustainability and reparability. Especially the latter is fundamentally important for true minimal invasiveness in partially defective tooth-colored restorations. Why should a restoration that is 20% defective be 100% renewed and risk the removal of large amounts of healthy tooth structure? Therefore, minimal invasiveness is not possible without conclusive repair concepts.

## 10. Function

Good function is still a decisive factor for clinical success. Wherever reasonably possible, adhesive restorative measures should be accompanied by the establishment of good function. For example, the restoration of a sufficient anterior canine guidance with minimally invasive composite abutments is standard practice for us before more extensive restoration is carried out in the posterior region.

## Conflict of interest

Prof. Frankenberger reports third-party funding from the companies 3M, Dentsply, Ivoclar and Kulzer as well as speaker fees from Dentsply, Kulzer, ADS and Ivoclar. Prof. Krämer discloses speaking engagements for Kulzer, Viadent, Densply, GC Europe and Oral B. In addition, the authors declare that there are no conflicts of interest as defined by the guidelines of the International Committee of Medical Journal Editors.

## References

1. Afrashtehfar KI, Emami E, Ahmadi M, Eilayyan O, Abi-Nader S, Tamimi F: Failure rate of single-unit restorations on posterior vital teeth: a systematic review. *J Prosthet Dent* 2017; 117: 345–353.
2. Askar H, Krois J, Göstemeyer G, Schwendicke F: Secondary caries risk of different adhesive strategies and restorative materials in permanent teeth: systematic review and network meta-analysis. *J Dent* 2021; 104: 103541.
3. Blanchard P, Wong Y, Matthews AG, Vena D, Craig RG, Curro FA, Thompson VP: Restoration variables and postoperative hypersensitivity in Class I restorations: PEARL Network findings. Part 2. *Compend Contin Educ Dent* 2013; 34: e62–8.
4. Coelho A, Amaro I, Rascão B, Marcelino I, Paula A et al.: Effect of cavity disin-

fectants on dentin bond strength and clinical success of composite restorations – a systematic review of in vitro, in situ and clinical studies. *Int J Mol Sci* 2020; 22: 353.

5. de Paris Matos T, Perdigão J, de Paula E, Coppla F, Hass V et al.: Five-year clinical evaluation of a universal adhesive: a randomized double-blind trial. *Dent Mater* 2020; 36: 1474–1485.

6. Frankenberger R: Composite first – Ceramic second: 25 Jahre Erfahrungen mit Komposit im Front- und Seitenzahn-bereich. *Quintessenz* 2018; 69(5): 490–497.

7. Frankenberger R, Hehn J, Hajtó J, Krämer N, Naumann M, Koch A, Roggendorf MJ: Effect of proximal box elevation with resin composite on marginal quality of ceramic inlays in vitro. *Clin Oral Investig* 2013; 17: 177–183.

8. Frankenberger R, Krämer N, Petschelt A: Technique sensitivity of dentin bonding: effect of application mistakes on bond strength and marginal adaptation. *Oper Dent* 2000; 25: 324–330.

9. Frankenberger R, Lohbauer U, Taschner M, Petschelt A, Nikolaenko SA: Adhesive luting revisited: influence of adhesive, temporary cement, cavity cleaning, and curing mode on internal dentin bond strength. *J Adhes Dent* 2007; 9 Suppl 2: 269–273.

10. Frankenberger R, Reinelt C, Petschelt A, Krämer N: Operator vs. material influence on clinical outcome of bonded ceramic inlays. *Dent Mater* 2009; 25(8): 960–968.

11. Frankenberger R, Taschner M, Garcia-Godoy F, Petschelt A, Krämer N: Leucite-reinforced glass ceramic inlays and onlays after 12 years. *J Adhes Dent* 2008; 10: 393–398.

12. Frankenberger R, Winter J, Schmalz G: Amalgam und Alternativen – Diskussionen zur Quecksilberreduktion in der Umwelt [Amalgam and alternatives – discussions on mercury reduction in the environment]. *Bundesgesundheitsblatt Gesundheitsforschung Gesundheitsschutz* 2021; 64: 847–855.

13. Göstemeyer G, Schwendicke F: Inhibition of hybrid layer degradation by cavity pretreatment: meta- and trial sequential analysis. *J Dent* 2016; 49: 14–21.

14. Groddeck S, Attin T, Tauböck TT: Effect of cavity contamination by blood and hemostatic agents on marginal adaptation of composite restorations. *J Adhes Dent* 2017; 19: 259–264.

15. Kanca J 3rd: Resin bonding to wet substrate. 1. Bonding to dentin. *Quintessence Int* 1992; 23: 39–41.

16. Kunz PVM, Wambier LM, Kaizer MDR, Correr GM, Reis A, Gonzaga CC: Is

Fig. 2-9; R. Frankenberger

the clinical performance of composite resin restorations in posterior teeth similar if restored with incremental or bulk-filling techniques? A systematic review and meta-analysis. *Clin Oral Investig* 2022; 26: 2281–2297.

17. KZBV (2020) Jahrbuch 2020. <https://www.kzbv.de/jahrbuch-2020.768.de.html>

18. Mejäre I, Källest I C, Stenlund H: Incidence and progression of approximal caries from 11 to 22 years of age in Sweden: a prospective radiographic study. *Caries Res* 1999; 33: 93–100.

19. Meyer-Lueckel H, Opdam NJM, Breschi L, Buchalla Wet al.: EFCD Curriculum for undergraduate students in Integrated Conservative Oral Healthcare (ConsCare). *Clin Oral Investig* 2019; 23: 3661–3670.

20. Moreira RJ, de Deus RA, Ribeiro MTH, Braga SSL, Schettini ACT et al.: Effect of light-curing unit design and mouth opening on the polymerization of bulk-fill resin-based composite restorations in molars. *J Adhes Dent* 2021; 23: 121–131.

21. Perdigão J, Frankenberger R: Effect of solvent and rewetting time on dentin adhesion. *Quintessence Int* 2001; 32: 385–390.

22. Rocha AC, Da Rosa W, Cocco AR, Da Silva AF, Piva E, Lund RG: Influence of surface treatment on composite adhesion in noncarious cervical lesions: systematic review and meta-analysis. *Oper Dent* 2018; 43: 508–519.

23. Schwendicke F, Walsh T, Lamont T, Al-Yaseen W, Bjørndal L, Clarkson JE, Fontana M, Gomez Rossi J, Göstemeyer G, Levey C, Müller A, Ricketts D, Robertson M, Santamaria RM, Innes NP: Interventions for treating cavitated or dentine carious lesions. *Cochrane Database Syst Rev* 2021 19; 7.

24. Sequeira-Byron P, Fedorowicz Z, Carter B, Nasser M, Alrowaili EF: Single crowns versus conventional fillings for the restoration of root-filled teeth. *Cochrane Database Syst Rev* 2015; CD009109.

25. Worthington HV, Khangura S, Seal K, Mierzwinski-Urban M, Veitz-Keenan A et

al.: Direct composite resin fillings versus amalgam fillings for permanent posterior teeth. *Cochrane Database Syst Rev* 202113; 8.



Photo: R. Frankenberger

**Corresponding author**  
**UNIV.-PROF. DR. MED. DENT.**  
**FADM ROLAND FRANKENBERGER**  
Department for Operative Dentistry,  
Endodontics, and Pediatric Dentistry,  
Medical Center for Dentistry,  
Philipps University Marburg and  
University Hospital Giessen  
and Marburg, Campus Marburg,  
Georg-Voigt-Str. 3, 35039 Marburg