

# Aesthetic Rehabilitation of Amputated Little Finger using RTV Silicone Elastomer- A Case Report

Manu Rathee<sup>1</sup>, S Divakar<sup>2</sup>, Sujata Chahal<sup>2</sup>,  
Sandeep Singh<sup>2</sup>, Maqbul Alam<sup>2</sup>, Sarthak Singh Tomar

<sup>1</sup> Senior Professor and Head, <sup>2</sup> Post Graduate Student  
<sup>1</sup>Department of Prosthodontics, Post Graduate Institute of Dental Sciences, Rohtak,  
Haryana, India

## INTRODUCTION

The hand plays a crucial role in social interaction, body language, and communication, along with performing its primary functions of gripping and feeling. Amputation of a finger or a section of a finger is the most prevalent kind of partial hand loss. Even though microsurgical reimplantation can restore severely damaged and traumatized digits, maxillofacial prosthetic rehabilitation provide benefits in patients who are not willing to undergo surgery.

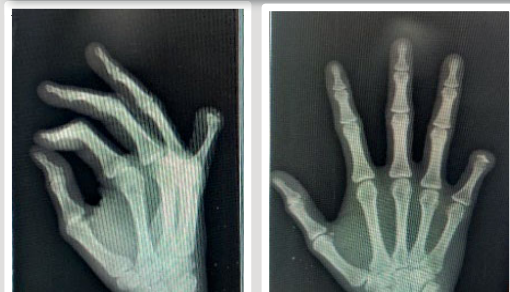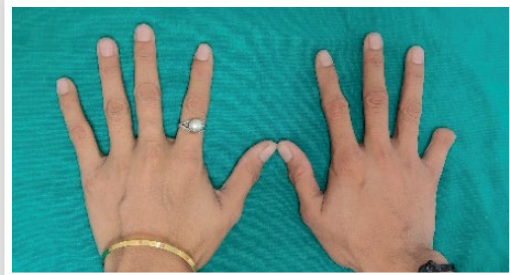## CASE REPORT

A 23-year-old female reported with the chief complaint of a partially missing little finger on her right hand. History reveals that she lost her finger 5 years ago due to an occupational incident. On examination, a partial amputation of the little finger in the intermediate interphalangeal joint was noted. The skin on the amputated finger had healed entirely with a slight bulge on the end of the damaged finger, with no signs of infection, scarring, or swelling.

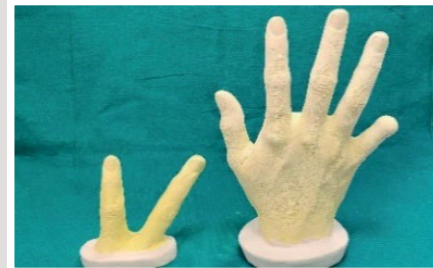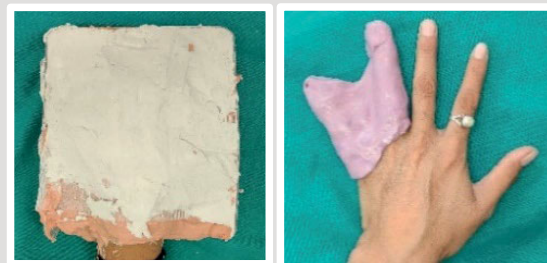## TREATMENT PLANNING

The patient had been provided with the treatment options of a finger prosthesis made of acrylic, an implant-retained finger prosthesis and a silicone finger prosthesis. It was determined to build a silicone prosthesis extending up to the proximal phalanx based on the patient's economic status and age. An undercut present at the intermediate interphalangeal joint and an artificial ring was planned to use as retention

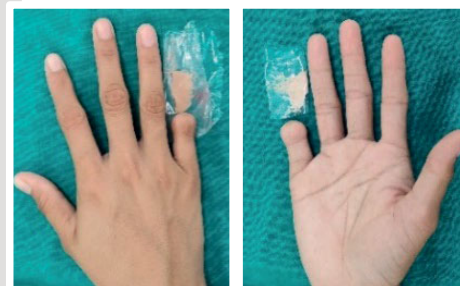## PRE-REHABILITATIVE VIEW




## IMPRESSION AND MASTER CAST



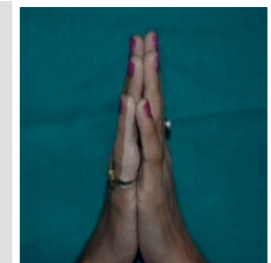
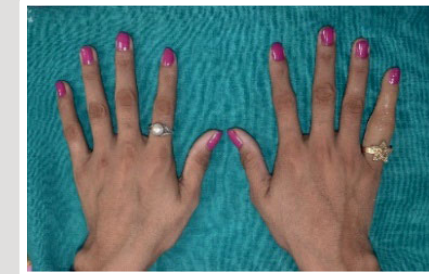## WAX-UP AND SHADE SELECTION



## LABORATORY PROCEDURES



## POST-REHABILITATIVE VIEW



## CONCLUSION

Eventhough the use of digital technology exhibits great potential for the fabrication of functional partial finger, this simple and less expensive technique will provide rehabilitation of a lost finger for economically weak patients.

## REFERENCES

1. Mehta S, Leela B, Karanjkar A, Halani AJ. Prosthetic rehabilitation of a partially amputated finger using a customized ring-wire substructure. J Indian Prosthodont Soc 2018;18:82-5
2. K RK, Bandela V, M B, S V GR. Acrylic finger prosthesis: a case report. J Clin Diagn Res. 2014;8(8):ZD07-ZD8.