

# Clinical and economic efficiency of a full digital workflow for craniomandibular dysfunction treatment



Niklas Kahlich<sup>1</sup>, Conrad Kühnöl<sup>2</sup>, Tomasz Gedrange<sup>1</sup>, Ute Ulrike Botzenhart<sup>1</sup>

<sup>1</sup>Department of Orthodontics, Medical Faculty Carl Gustav Carus, TU Dresden, 01307 Dresden, Germany

<sup>2</sup>Dental office, Dr. med. dent. C. Kühnöl, Bayreutherstr. 30, 01187 Dresden, Germany

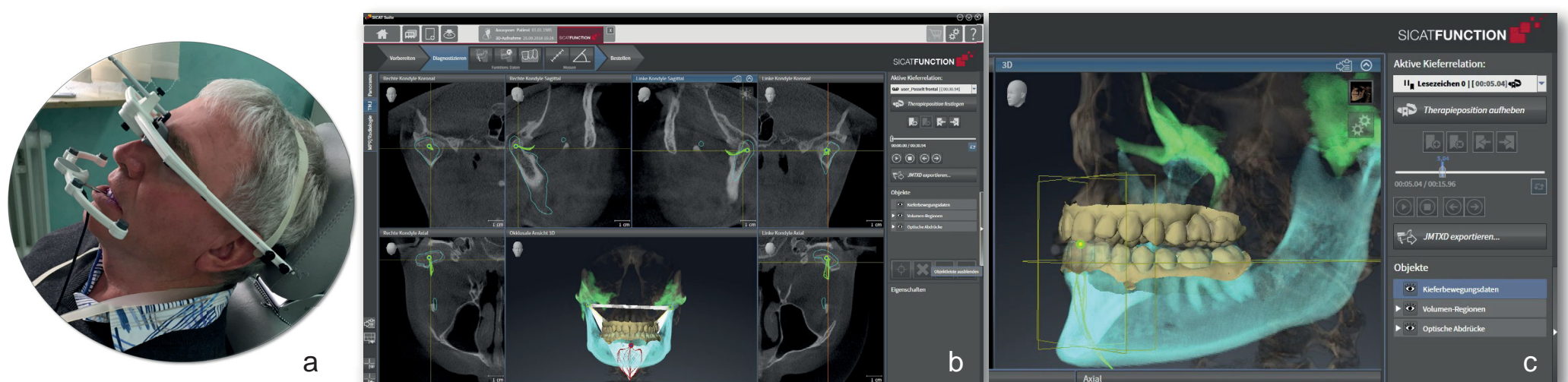
## Background

Craniomandibular dysfunctions (CMD) are dysregulations of the chewing organ and adjoining structures, which can lead to destruction of hard and soft dental tissues, joint cartilage, decreased chewing function and pain, thereby massively reducing wellbeing and quality of life. The treatment of CMD requires accurate and objective diagnostics to enable a successful interdisciplinary treatment. Conventional diagnostics cannot completely detect the temporomandibular joint in its own complexity by technical restriction. In addition, due to a high proportion of "manual labour", human errors and diagnostic variances cannot be excluded<sup>1</sup>.

**The purpose of this study was to evaluate a full digital workflow for craniomandibular dysfunction diagnostics, including intraoral scans, digital volume tomography, digital motion tracking, and treatment with a 3D-shaped bite splint.**

## Material and Methods

This prospective study included n=19 adult patients (8 men, 11 women) suffering from CMD, who met the inclusion criteria (presence of a craniomandibular dysfunction requiring treatment; no previous splint therapy; no primary temporomandibular joint disease or general underlying disease that could be the cause of the pain or could influence the therapy outcome [e.g. rickets, Parkinson's disease, osteoporosis, psychosomatic diseases, neuralgias, and neuropathies]), and consented to the therapy and the use of their data. Prior to treatment, ethical approval was obtained by legal agency (EK 213062018). 3D diagnostics and data matching were performed, on the basis of which a 3D bite splint was designed and produced (SICAT, Bonn, Germany; Polymethylmethacrylat astron® Clearsplint® CAD/CAM, Schütz Dental GmbH, Rosbach, Germany) (Fig. 1). Patients were evaluated pre- and post-treatment and every 6 weeks up to 6 months by clinical analysis, splint adjustment, and questionnaire. Descriptive analysis and statistics were performed using MS Excel (Version 16.0, Microsoft Corporation, Redmond, USA).



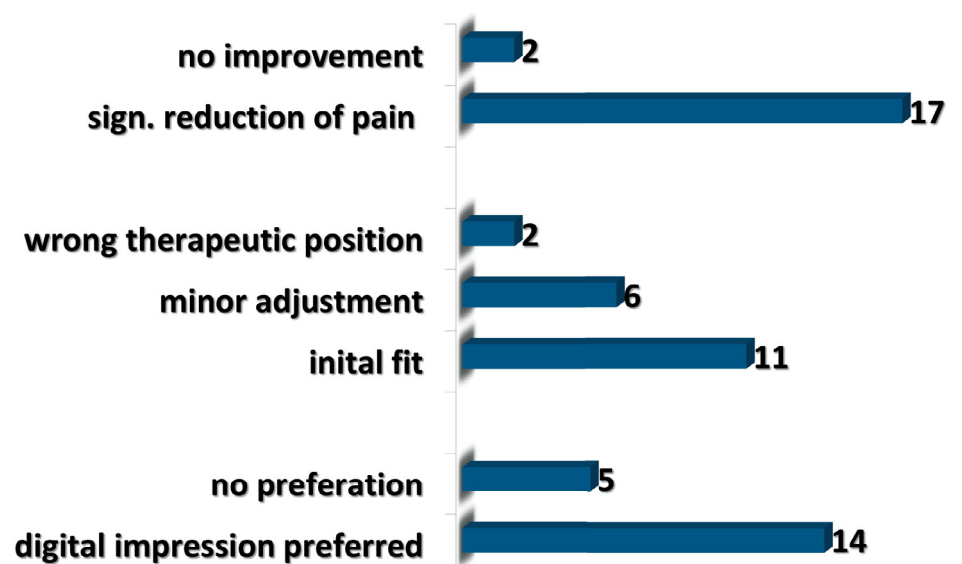
**Figure 1:** a) motion tracking with the SICAT JMT+, b) 3D fusion of digital volume tomography, intraoral scan and motion tracking of an exemplary patient in the SICAT software (Posselt diagramm frontal view, motion path of the TMJ illustrated in green) c) simulated therapeutic position for splint adjustment in the SICAT software.

## Results

Splint therapy led to a significant reduction in subjective complaints in 89% (n=17) of patients, whereas only 11% (n=2) reported unchanged complaints. 74% (n=14) of patients preferred digital impressions and milled bite splints; the other 26% (n=5) did not indicate a special preference. The majority of digitally designed bite splints showed a satisfactory initial fit (58%/n=11) and 32% (n=6) could be fitted after minor adjustments (Fig. 2).

## Conclusion

The digital workflow for CMD treatment, analysed in this study, showed a significant reduction in working time by a high proportion of digitization and automation combined with a high level of patient satisfaction and accuracy of splint fit. Nevertheless, the use of digital volume tomography did not improve diagnostics and should be viewed critically in this context.



**Figure 2:** Illustration of data outcomes after patient questionnaire about preferred impression type and improvement of pain as well as clinical outcome of splint fit in a full digital workflow (real data) of n=19 patient.

## Literature

<sup>1</sup>Kordaß B. Praxisorientierte Analyse der funktionellen Okklusion. Jahrbuch Digitale Dentale Technologien; 2016: 15-18.

<sup>2</sup>Ludlow JB, Ivanovic M. Comparative dosimetry of dental CBCT devices and 64-slice CT for oral and maxillofacial radiology. Oral Surg Oral Med Oral Pathol Oral Radiol Endod. 2008 Jul;106(1):106-14.