



Neurovascular Disturbance Associated with Implant Placement in the Anterior Mandible and its Surgical Implications: Literature Review including Report of a Case

Xin LIANG^{1,2,3}, Ivo Lambrichts², Livia Corpas¹, Constantinus Politis⁴, Luc Vrielinck⁴, Guo Wu MA³, Reinhilde Jacobs¹

Abstract: Nowadays, oral implants are routinely used for rehabilitation of the edentulous mandible as this procedure is often considered uncomplicated, especially when limiting implant placement to the symphyseal area. Nevertheless, a case of nerve disturbance in the anterior mandible after the implant placement is described. Therefore, surgical, radiographic and anatomic considerations are reviewed in order to encounter the risks for neurosensory disturbance and haemorrhage. It is clear that preoperative radiographic planning of oral implant placement in the anterior mandible should pay attention to the mandibular incisive and lingual canals, besides the mental one, to avoid any neurovascular complications.

Key words: dental implant, surgical complications, neurovascular, anterior mandible

The anterior mandible is mostly considered as an ideal and safe area for rehabilitation of the edentulous mandible with oral implants. Nevertheless, the use of volumetric imaging has allowed the visualising of canal structures in the anterior mandible, which might assume some elaborate neurovascularisation. These

findings may be linked to the fact that, in the past two decades, some authors have reported neurosensory disturbances and haemorrhage in the anterior mandible^{1–21}. This may underline the need for presurgical assessment of neurovascular structures prior to anterior mandibular surgery. Unfortunately, there are few publications on anatomical variations in dimensions and morphology of these canals^{22–24}. Considering the increased use of oral implants, the occurrence and anatomic variability of the mandibular incisive canal and lingual canal (superior and inferior genial spinal canals and lateral lingual canal) have regained attention to optimise surgical planning and avoid complications^{23,24}.

In the present report, a case is presented in which oral implant placement caused nerve disturbance, and a further review is carried out to clarify this observation and explain other case reports on neurosensory disturbance after anterior mandibular surgery. A review of the literature is also performed on all documented case reports on haemorrhage and related anatomical structures in the anterior mandible. The article also includes a report on

1 Oral Imaging Centre, School of Dentistry, Oral Pathology and Maxillofacial Surgery, Faculty of Medicine, Catholic University of Leuven, Leuven, Belgium.

2 Department of Basic Medical Sciences, Faculty of Medicine, University of Hasselt, Diepenbeek, Belgium.

3 College of Stomatology, Dalian Medical University, Dalian, P.R. China.

4 Maxilla-Facial Surgery ZOL, Hospital Genk, Genk, Belgium.

Corresponding author: Dr Reinhilde Jacobs, Oral Imaging Centre, School of Dentistry, Oral Pathology and Maxillofacial Surgery, Faculty of Medicine, Catholic University of Leuven, Kapucijnenvoer 7, K.U. Leuven postbox: 07001 - UZ ST RAFAEL, B-3000 Leuven, Belgium. Tel: +3216 33 24 10; Fax: +3216 33 24 10. E-mail: reinhilde.jacobs@uzleuven.be

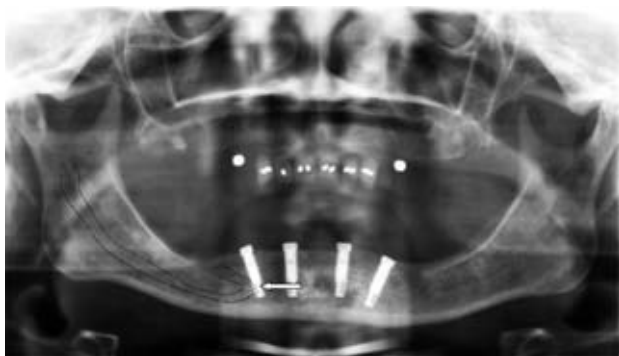


Fig 1 After the first surgery, the panoramic image showed the anterior vertical looping part of the mandibular canal was overlapped by implant with longer length and located most distally (see arrow).

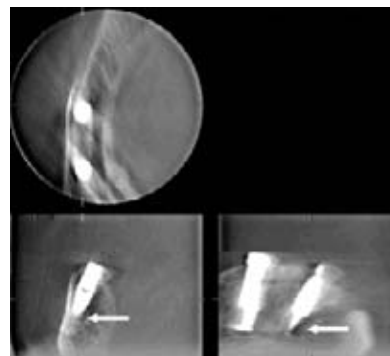


Fig 2 After the first surgery, CBCT images were taken using the Accuitomo machine showing the location of the mandibular implants and their relation to the mandibular incisive and mental canal.

anatomical variations in the anterior mandible and some suggestions for presurgical planning to avoid complications.

Case Report on Nerve Disturbance

A 61-year-old woman, who had been edentulous for more than 20 years, was referred to the Department of Oral and Maxillofacial Surgery for oral implant placement. The treatment plan included the placement of four implants in the interforaminal region to provide support for a mandibular complete-arch restoration. A panoramic image (Orthophos XG Plus, Sirona, Bensheim, Germany) was applied as presurgical radiological planning. Mandibular surgery was performed under local anaesthesia and four 15 mm length implants were placed in the symphyseal area, according to a two-stage protocol. Two months after wearing the prosthesis, the patient came back with neuralgiform pain in the right lower lip; therefore, the prosthesis was not left in function. Panoramic (Orthophos XG Plus) and cone beam computerised tomography (CBCT) images (Accuitomo[®], Morita, Japan) were taken to inspect the region. On the panoramic image after initial implant placement, it is seen that the anterior looping part of the mandibular canal is overlapping with the most distally located implant (Fig 1). Considering the postsurgical unsustainable pain, the reason may be sought in an implant–nerve contact. The latter assumption is proven by the result of CBCT imaging of this particular region (Fig 2). On the cross-sectional slices of CBCT, it appeared that the right oral implants touched the incisive canal (Fig 2). Therefore, the 15 mm implants at the right side were removed and another two, shorter 10 mm im-

plants were placed. On the fourth post-operative day, the patient was in good health and pain had subjectively, as well as upon further clinical testing, decreased. On a post-operative control 3 weeks after surgery, implants were considered stable with good position and the wound healing. Unfortunately, the pain complaints had restarted and increased and there vitamin B12 was prescribed.

Almost 1 year after the first surgery, the patient consulted again with persistent pain in the right lower lip. The pain was described as cutting like glass. Marcaine (Bupivacaine HCl) was injected in the mental foramen and afterwards the pain disappeared temporarily. Two months later, cryotherapy was performed on the right mental region (-89°C , three times, 2 min each time). At a postoperative control 4 days later, the patient was free from the pain, but again the pain returned 2 weeks later. Subsequently, another series of panoramic and CBCT images (Galileos, Sirona, Bensheim, Germany) were taken. Images showed the distal implant touched the corner of the anterior vertical looping of the mental nerve and the branch of incisive canal (Figs 3 and 4). Oral sensory testing was carried out. The patient's intra-oral condition was good (Fig 5). Tests showed gums of the distal implant region from the right side being less sensitive than the left side. The right-side lip pain affected eating, speaking and even writing. It was totally insupportable except during the sleep. The strongest feeling of the pain was now qualified as a burning sensation. Few months later, therefore, the patient started to use morphine in order to try killing the pain (12–25 mg/72 h). In the beginning it enabled some pain relief, but the effectiveness decreased over time.

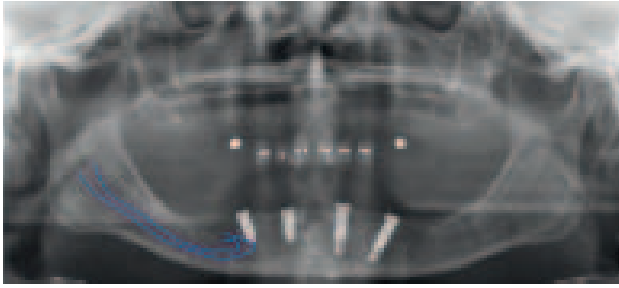


Fig 3 After placement of shorter implants, the panoramic slice showed the distal implant touching the branching of the mandibular incisive canal and the mental nerve anterior looping.

Review of Nerve Disturbance Reports

Previous reports also described that sensory disturbances could be associated with implant placement in the anterior mandible^{2–8}. Based on the analysis of questionnaires, Ellies and Hawker² reported 37% of their subjects had an altered sensation after the implantation and 10–15% of them still noted such changes after 15 months. Van Steenberghe et al³ found that 17% of the patients experienced an altered sensation of the lower lip after implant surgery in the mandible. Kiyak et al⁴ noticed such sensory changes in 43% of their study patients after 2 weeks of implant surgery. In the publication of Walton⁵, both sensation test and questionnaire analysis were applied and 24% of subjects reported neurosensory disturbances 2 weeks after implant surgery in the anterior mandible, but the problem of such disturbances reduced to about 1% at 1 year after surgery. By using a combination of psychophysical methods (soft brush, two-point discrimination, pain perception and temperature sensitivity), Bartling et al⁶ found only 8 out of 94 study subjects had altered sensation after oral implant placement in the mandible. Wismeijer et al⁷ described an altered sensation in 11% of their subjects after 10 days of the implant surgery by using questionnaire analysis, and 10% of them still suffered this disturb at 6 months after surgery. On the other hand, Abarca et al⁸ evaluated the past and present neurosensory disturbances with regard to immediately loaded implants in the edentulous anterior mandible. A questionnaire and a psychophysical approach were used in their study. One-third of the subjects reported a neurosensory disturbance after the surgery, and 15% still complained 8–21 months afterwards⁸.

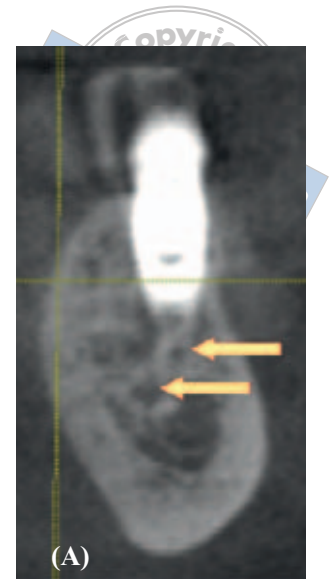
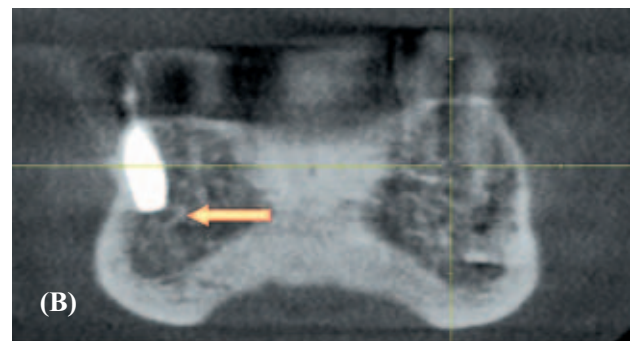


Fig 4 CBCT images taken after the second surgery: (A) the anterior looping of the mandibular mental canal on the cross-section; (B) the implant touching the upper border of the incisive canal (pointed to by arrow) from a frontal view.



Review of Haemorrhage Clinical Case Reports

A review of the literature shows that 12 references have described 13 previous cases of haemorrhage in the floor of the mouth and potentially life-threatening upper airway obstruction after the placement of implants into the anterior mandible^{10–21}. Nine females and four male patients from 42 years to 80 years were included in the previous reports (mean age: 53.5 years). A total of 38 implants were placed in nine completely and four partially edentulous mandibles. One of them is a single abutment implantation in a fully dentate mandible. Two reports were related to the immediate implant placements. The treatment plans included single restoration²⁰, fixed prostheses^{12,15}, partial dentures¹⁸, and overdentures^{13,14,21}. The majority of haemorrhages were related to the implant length (≥ 15 mm) or the depth of osteotomy preparations^{10–21}. According to the haemorrhaging onset time, three cases happened during the

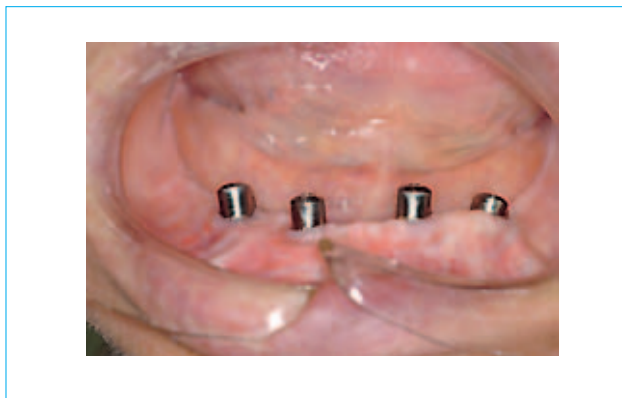


Fig 5 An intra-oral image illustrates the good intra-oral condition of the patient.

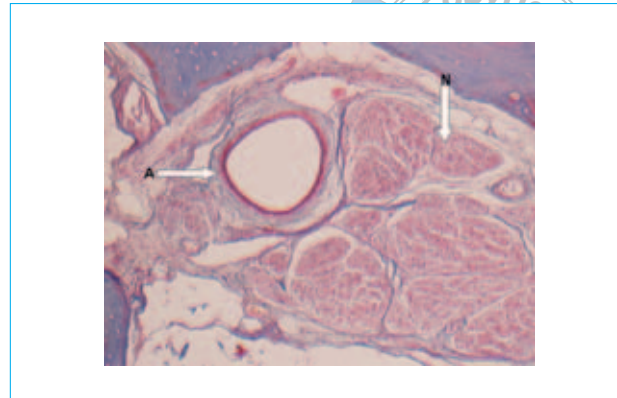


Fig 6 A histological image confirmed the existence of big nerve bundles (arrow N) and artery (arrow A) inside the incisive canal. Courtesy of Histology Group of University Hasselt, Belgium.

implant osteotomy preparation^{10,14,19}, three cases during the implantation^{15,16,21}, two cases during the suturing^{13,18}, two cases after 30 min^{17,20} and three cases after 4–6 h^{11,12,14}. There is only one case that was successfully managed with airway observation¹⁴. To prevent life-threatening haemorrhage and airway obstruction, all the other cases were handled adequately by controlling airway passage and stopping haemorrhage. Airway control was successful in most patients with naso-oro-tracheal intubation^{10–15,17}. In another five cases, the airway passage was enabled using tracheostomy^{16,18–21}. For controlling haemorrhage, surgical exploration of the floor of mouth was performed in most of the cases for haematoma evacuation and isolation^{11–18,20,21}, except for two cases that were handled conservatively^{10,19}. All patients were discharged home after 1 to 11 days and recovered well.

Anatomical Considerations

Mandibular incisive canal and its contents

Except for mental nerve, the incisive nerve is often detected as a second terminal branch of the inferior alveolar nerve, which is an intraosseous course in a so-called mandibular incisive canal. This canal is located anteriorly to the mental foramen from both left and right sides of the mandible^{25–27} (see Figs 4 and 6). However, many clinicians neglect the presence of a real mandibular incisive canal. Gray's Anatomy mentions that the mandibular canal gives off two small canals, mental and incisive; the mental canal swerves up, back and laterally to the mental foramen, whereas the mandibular incisive canal continues below the incisor teeth²⁸. Conventional radio-

graphs usually fail to show such a canal²⁹. Panoramic radiographs can be used for visualization of the mental foramen and a potential anterior looping, but not for locating the mandibular incisive canal³⁰. Tomographic imaging allows exploration for the presence and course of an anterior prolongation of the mandibular canal^{24,31}. Both CBCT and spiral CT images can identify this canal by viewing in three dimensions^{30,32,33}.

A high-resolution MRI study by Jacobs et al³³ indicated that the mandibular incisive canal contains a true neurovascular bundle with nerve structures, having a sensory function. This finding confirms that the canal contains the intra-osseous extension of the inferior alveolar neurovascular bundle, supplying the mandibular anterior teeth. In the presently reported case, post-operative CT images revealed that implants had been placed inside of the mandibular incisive canal and were touching the incisive nerve which runs through the canal.

Superior and inferior genial spinal foramina, lateral lingual foramina and their bony canal contents

Lingual foramina and canals are the other important anatomical landmarks, located in the mandibular interforaminal region. These foramina included the superior and inferior genial spinal foramina and lateral lingual foramina. The superior one is at the level of, or superior to, the genial spine; the inferior one is below to the genial spine; and the lateral one is on the left or right side of the midline (Figs 7–9). This has been found in 85 to 99% of mandibles^{22,34–36}.

The existence and contents of these foramina are seldom described in the general anatomy text-

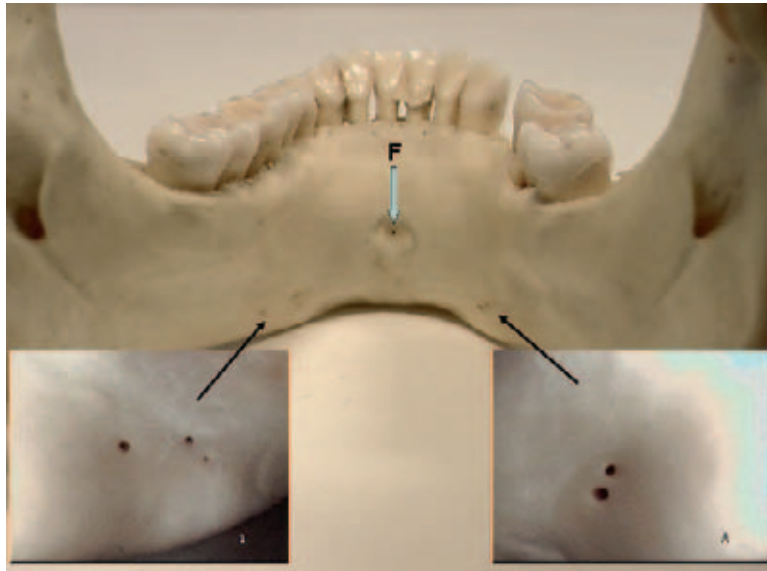


Fig 7 In a dry mandibular specimen, there is a superior genial spinal foramen (see arrow F) and several lateral lingual foramina located on both left and right sides in the mandibular anterior region.

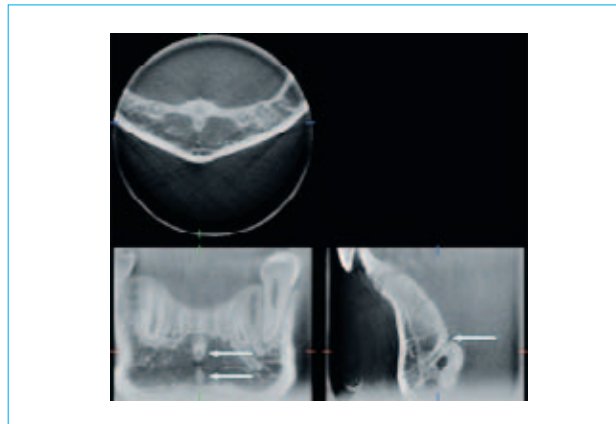


Fig 8 CBCT images show both superior and inferior genial spinal foramina from frontal view (see arrows on image of lower left) and a bony canal from sagittal view (see arrow on image of lower right).

books^{28,37-41}, nor in dental anatomy textbooks⁴²⁻⁴⁴. However, these canals are well identified in textbooks related to dental radiographic anatomy, because of the corticalised contour^{32,45-47}. Acquiring proper knowledge on foramina could be important for presurgical considerations of implant placement in the midline of the mandible⁴⁸. In previous dissection reports, some

anatomical variations and anastomoses have been discovered. A branch of the lingual artery and vein and lingual nerve, a branch of the mylohyoid nerve together with branches or anastomoses of the sublingual and/or submental artery and vein have been identified upon entering those foramina. This artery could be of sufficient size to provoke a haemorrhage intraosseously or in the

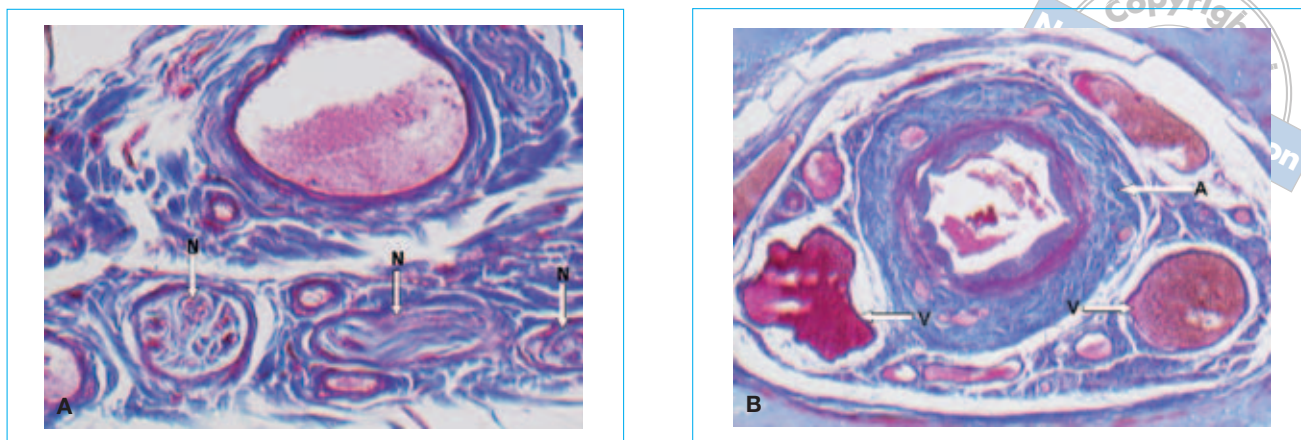


Fig 9 True canal contents of lingual canal were confirmed by histological study: (A) the nerve tissue (arrow N); (B) the artery (arrow A) and vein (arrow V). Courtesy of Histology Group of University Hasselt, Belgium.

connective soft tissue which might be difficult to control^{23,35}. A high-resolution MRI study³³ clearly established that the contents of these canals have a neurovascular nature. Liang et al⁴⁹ used qualitative and quantitative MRI images for microanatomical assessment which was also confirmed by the histological evaluation. These findings may be considered as an important link to the case reports on haemorrhage and/or sensory disturbances after anterior mandibular surgery.

Discussion

Sensory disturbances

Sensory disturbances can be caused by direct trauma, indirect trauma (e.g. pressure by a haematoma in the canal) or chronic stimulation to the mandibular incisive canal bundle or lingual canal bundle after implant placement in the interforaminal region. After direct trauma, which can occur if the implant is placed through the bony canal, the nerve ending may get retrograde degeneration⁵⁰ in most cases, because the nerve running in the canal is a terminal ending of the nerve and the size is quite small. Indirect trauma can be caused by a haematoma in the canal affecting the mandibular incisive canal bundle and spreading to the main mental branch^{1,51}. As this blood clot cannot be evacuated, the swelling compresses the nerve and leads to trauma by compression neuropathy. Sensory disturbances might also be related to chronic stimulation. If the implant is situated beside or on top of the nerve, then the nerve can be stimulated recurrently each time when biting or chewing. It is likely that such

chronic stimulation may, therefore, end up as chronic neuropathy³³.

Hypoaesthesia, anaesthesia and paraesthesia may display as a sensory disturbance. In some cases the sense of pain is mainly disturbed, but in others the tactile and temperature senses are also disturbed⁵¹. All these changes can be transient or persistent, depending on the degree of damage to the nerve tissue involved^{52,53}.

Haemorrhage

Extensive haemorrhage in the floor of the mouth may occur during implant placement in the mental interforaminal region and may cause acute airway obstruction^{10–21}. The haemorrhage not only can be induced by instrumentation through a perforation of the lingual cortical plate, but may also be caused by touching and damaging the neurovascular bony canals, like lingual canals. There are many vascular anastomoses in the anterior region of the mandible and rich vascular supplies to the lingual periosteum^{23,54}. This may lead to a profuse bleeding even from a break of a small-sized bony canal.

The presence of lingual bony canals with an assumed vascular content may indeed present a risk for bleeding complication, such as during implant surgery. Madeira et al⁵⁵ reported that the canal content was neurovascular with branches of the mylohyoid nerve and sublingual artery. Ennis⁵⁶ stated that the lingual foramen transmits a branch of the incisive artery to anastomose with the sublingual artery. White and Pharoah³² noted that the foramina and canals are the termination of the incisive

neurovascular branch of the mandibular canal. In the study of Kawai et al⁵⁷, the submental artery was found to send complex branches to the lingual foramen, which passed through the canal and connected with the incisive branch and mental artery in the anterior region of the mandible. Liang and co-workers^{23,34,49} confirmed the existence of neurovascular contents by high-resolution MRI and histology. They also found that the lingual canal neurovascular contents may relate to the location of the canal and anatomical variations. In these studies, a lingual nerve branch innervates the superior canal, while a branch of the mylohyoid nerve enters the inferior and lateral canal. Vascular supplies from lingual artery, sublingual artery and submental artery are anastomotic for superior, inferior and lateral foramina. They may evidently have a different neurovascular supply considering their differential location below or above the mylohyoid muscle. Importantly, the vascular size and canal diameter have often been identified as large enough to cause significant damage and bleeding when touching.

Surgical implications and suggestions for presurgical planning to avoid surgical complications

To prevent surgical complications of anterior mandibular surgery, a careful preoperative lingual probing or elevation of the periosteum were mostly suggested by previous studies to provide a sufficient and safe view of the anatomy. Normally, surgeons regard a longer implant as desirable to ensure the stability of the osseointegration. However, there is no clinically proven advantage for implants as long as 18 mm¹⁸. Ten Bruggenkate et al⁵⁸ proved a successful osseointegration in the rehabilitation of resorbed mandibles by using 6 and 8 mm short implants. Most of the former complications were coupled to placement implants with length of 15 mm or longer. Therefore, implants with length shorter than 15 mm might be advisable to place in the anterior mandible. The latter may also help to avoid thermal trauma, as the symphyseal area is often dense and long implants may cause more heating. In addition, the drilling angulations should be adjusted according to the remaining socket¹⁸. Anyway, a good prerequisite of volumetric imaging (e.g. CBCT imaging) is necessary for such implant surgery, because it can give better information of those pivotal anatomical structures and can definitely help the surgeon to plan implant length or angulations. Considering the anatomical considerations and the aforementioned limitations, the present case, therefore, clearly demonstrates that two-dimensional imaging does not yield enough information to guarantee avoiding surgical complications in all cases.

Three-dimensional imaging, therefore, is a prerequisite to avoid surgical complications. Presurgical three-dimensional imaging may assist the surgeon in evaluating bone size, morphology and quality of the planned implant locations. It may also help to detect the presence and location of vital neurovascular bundles.

Cross-sectional imaging is thus recommended for presurgical planning, even when dealing with a case in this anterior mandible, previously often considered as a safe and uncomplicated surgical area. For such planning, cross-sectional imaging is recommended. In the past, cross-sectional imaging was performed using spiral tomography⁵¹, but considering the introduction of volumetric imaging offering far more information at similar dose levels, it is clear that CBCT has become the method of choice for such presurgical planning techniques⁵⁹. Compared with spiral CT scan, CBCT scan can provide a detailed three-dimensional reconstruction of the bony morphology at a lower dose and cost than spiral CT⁶⁰. Besides, the mandibular incisive canal, the superior and inferior genial spinal foramina, the lateral lingual foramina and their bony canals can be clearly depicted on CBCT images⁶¹. This underlines the recommended use of low-dose CBCT imaging for implant planning as an accurate method⁵⁹. Conventional panoramic radiography may be helpful to establish a treatment plan prior to implant surgery if no other previous images are present²⁴.

Conclusion

Although nerve disturbance after implant placement is rare, the present case report has shown that, if happening, it can result in life disordering complications. The haemorrhage case reports summarised in the review illustrate another life-threatening complication of implant placement in the mandibular interforaminal region. Therefore, the anterior mandible should be reconsidered as encountering risks for neurovascular disturbance instead of being denoted as an 'easy' or 'safe' surgical area. A careful preoperative radiographic assessment is recommended, with CBCT as the method of choice for the presurgical planning.

References

1. Rosenquist B. Is there an anterior loop of the inferior alveolar nerve? *Int J Periodontics Restorative Dent* 1996;16:40–45.
2. Ellies LG, Hawker PB. The prevalence of altered sensation associated with implant surgery. *Int J Oral Maxillofac Implants* 1993;8:674–679.

3. Van Steenberghe D, Lekholm U, Bolender C, Folmer T, Henry P, Herrmann I et al. Applicability of osseointegrated oral implants in the rehabilitation of partial edentulism: a prospective multicenter study on 558 fixtures. *Int J Oral Maxillofac Implants* 1990;5:272–281.
4. Kiyak HA, Beach BH, Worthington P, Taylor T, Bolender C, Evans J. Psychological impact of osseointegrated dental implants. *Int J Oral Maxillofac Implants* 1990;5:61–69.
5. Walton JN. Altered sensation associated with implants in the anterior mandible: a prospective study. *J Prosthet Dent* 2000;83:443–449.
6. Bartling R, Freeman K, Kraut RA. The incidence of altered sensation of the mental nerve after mandibular implant placement. *J Oral Maxillofac Surg*. 1999;57:1408–1412.
7. Wismeijer D, van Waas MA, Vermeeren JI, Kalk W. Patients' perception of sensory disturbances of the mental nerve before and after implant surgery: a prospective study of 110 patients. *Br J Oral Maxillofac Surg* 1997;35:254–259.
8. Abarca M, van Steenberghe D, Malevez C, De Ridder J, Jacobs R. Neurosensory disturbances after immediate loading of implants in the anterior mandible: an initial questionnaire approach followed by a psychophysical assessment. *Clin Oral Investig* 2006;10:269–277.
9. Hofschneider U, Tepper G, Gahleitner A, Ulm C. Assessment of the blood supply to the mental region for reduction of bleeding complications during implant surgery in the interforaminal region. *Int J Oral Maxillofac Implants* 1999;14:379–383.
10. Kalpidis CD, Setayesh RM. Hemorrhaging associated with endosseous implant placement in the anterior mandible: a review of the literature. *J Periodontol* 2004;75:631–645.
11. Krenkel C, Holzner K. Lingual bone perforation as causal factor in a threatening hemorrhage of the mouth floor due to a single tooth implant in the canine region. *Quintessenz* 1986;37:1003–1008.
12. Mason ME, Triplett RG, Alfonso WF. Life-threatening hemorrhage from placement of a dental implant. *J Oral Maxillofac Surg* 1990;48:201–204.
13. Laboda G. Life-threatening hemorrhage after placement of an endosseous implant: report of case. *J Am Dent Assoc* 1990; 121:599–600.
14. Ten Bruggenkate CM, Krekeler G, Kraaijenhagen HA, Foitzik C, Oosterbeek HS. Hemorrhage of the floor of the mouth resulting from lingual perforation during implant placement: a clinical report. *Int J Oral Maxillofac Implants* 1993;8:329–334.
15. Mordenfeld A, Andersson L, Bergström B. Hemorrhage in the floor of the mouth during implant placement in the edentulous mandible: a case report. *Int J Oral Maxillofacial Implants* 1997;12:558–561.
16. Darriba MA, Mendonca-Cardad JJ. Profuse bleeding and life-threatening airway obstruction after placement of mandibular dental implants. *J Oral Maxillofac Surg* 1997;55:1328–1330.
17. Panula K, Oikarinen K. Severe hemorrhage after implant surgery. *Oral Surg Oral Med Oral Pathol Oral Radiol Endod* 1999;87:2.
18. Givol N, Chaushu G, Halamish-Shani T, Taicher S. Emergency tracheostomy following life-threatening hemorrhage in the floor of the mouth during immediate implant placement in the mandibular canine region. *J Periodontol* 2000;71:1893–1895.
19. Niamtu III J. Near-fatal airway obstruction after routine implant placement. *Oral Surg Oral Med Oral Pathol Oral Radiol Endod* 2001;92:597–600.
20. Boys-Varley JG, Lownie JF. Haematoma of the floor of the mouth following implant placement. *S Afr Dent J* 2002;57:64–65.
21. Woo BM, Zee KY, Chan FH, Corbet EF. In vitro calibration and validation of a digital subtraction radiography system using scanned images. *J Clin Periodontol* 2003;30:114–118.
22. McDonell D, Reza Nouri M, Todd ME. The mandibular lingual foramen: a consistent arterial foramen in the middle of the mandible. *J Anat* 1994;184:363–369.
23. Liang X, Jacobs R, Lambrichts I, Vandewalle G. Lingual foramina on the mandibular midline revisited: a macroanatomical study. *Clin Anat* 2007;20:246–251.
24. Mraiwa N, Jacobs R, Moerman P, Lambrichts I, van Steenberghe D, Quirynen M. Presence and course of the incisive canal in the human mandibular interforaminal region: two-dimensional imaging versus anatomical observations. *Surg Radiol Anat* 2003;25:416–423.
25. Bavitz JB, Harn SD, Hansen CA, Lang M. An anatomical study of mental neurovascular bundle-implant relationships. *Int J Oral Maxillofac Implants* 1993;8:563–567.
26. Mardinger O, Chaushu G, Arensburg B, Taicher S, Kaffe I. Anatomic and radiologic course of the mandibular incisive canal. *Surg Radiol Anat* 2000;22:157–161.
27. Jacobs R, Mraiwa N, van Steenberghe D, Gijbels F, Quirynen M. Appearance, location, course, and morphology of the mandibular incisive canal: an assessment on spiral CT scan. *Dentomaxillofac Radiol* 2002;31:322–327.
28. Williams PL, Warwick R, Dyson M, Bannister LH (eds). *Gray's Anatomy, 37th edition*. Edinburgh: Churchill Livingstone, 1989; 368–390, 736–737, 1106.
29. Langland OE, Sippy FH, Langlais RP (eds). *Textbook of Dental Radiology, 2nd edition*. Springfield: Charles C. Thomas, 1984; 380–411.
30. Jacobs R, Mraiwa N, Van Steenberghe D, Sanderink G, Quirynen M. Appearance of the mandibular incisive canal on panoramic radiographs. *Surg Radiol Anat* 2004;26:329–333.
31. Naitoh M, Katsumata A, Kubota Y, Okumura S, Hayashi H, Arijii E. The role of objective plane angulation on the mandibular image using cross-sectional tomography. *J Oral Implantol* 2006;32:117–121.
32. White SC, Pharoah MG (eds). *Oral Radiography Principles and Interpretation, 5th edition*. C.V. Mosby, 2004; 182.
33. Jacobs R, Lambrichts I, Liang X, Martens W, Mraiwa N, Adriaensens P, Gelan J. Neurovascularization of the anterior jaw bones revisited using high-resolution magnetic resonance imaging. *Oral Surg Oral Med Oral Pathol Oral Radiol Endod* 2007;103:683–693.
34. Vandewalle G, Liang X, Jacobs R, Lambrichts I. Macroanatomical and radiographic characteristics of the superior genial spinal foramen and its bony canal. *Int J Oral Maxillofac Implants* 2006;21:581–586.
35. Shiller WR, Wiswell OB. Lingual foramina of the mandible. *Anat Rec* 1954;119:387–390.
36. Sutton RN. The practical significance of mandibular accessory foramina. *Aust Dent J* 1974;19:167–173.
37. Last RJ (ed). *Anatomy, Regional and Applied, 7th edition*. London: Churchill Livingstone, 1984; 575–577.
38. McMinn R, Hutchins RT (eds). *Colour Atlas of Human Anatomy, 2nd edition*. Chicago: Year Book Medical Publishers Inc, 1988; 20–24.
39. Woodbume RT, Burkel WE (eds). *Essentials of Human Anatomy, 8th edition*. New York: Oxford University Press, 1988; 253–255.
40. Agur AMR (ed). *Grant's Atlas of Anatomy, 9th edition*. Baltimore: Williams and Wilkins, 1991; 501.
41. Moore K (ed). *Clinically Oriented Anatomy, 3rd edition*. Baltimore: William and Wilkins, 1992; 651–655.

42. Berkovitz RKB, Holland GR, Moxham BJ (eds). *A Colour Atlas and Textbook of Oral Anatomy*. Chicago: Year Book Medical Publishers Inc, 1977; 15–16.
43. Liebgott B (ed). *The Anatomical Basis of Dentistry*. Toronto: WB Saunders, 1982; 225–229.
44. Longman RB, McRae DA (eds). *Clinical Anatomy for Dentistry*. New York: Churchill Livingstone, 1985; 35–38.
45. Kasse MJ (ed). *An Atlas of Dental Radiographic Anatomy*, 3rd edition. Toronto: WB Saunders; 1989, 76–83.
46. Mansong-Hing LR (ed). *Fundamentals of Dental Radiography*, 3rd edition. Philadelphia: Lea and Febiger, 1990; 96–98.
47. Langland OE, Langlais RP (eds). *Principles of Dental Imaging*. Baltimore: Williams & Wilkins, 1997; 331–355.
48. Liang X, Jacobs R, Lambrichts I. An assessment on spiral CT scan of the superior and inferior genial spinal foramina and canals. *Surg Radiol Anat* 2006;28:98–104.
49. Liang X, Jacobs R, Lambrichts I, Vandewalle G, van Oostveldt D, Schepers E, Adriaensens P, Gelan J. Microanatomical and histological assessment of the content of superior genial spinal foramen and its bony canal. *Dentomaxillofac Radiol* 2005;34:362–368.
50. Beirowski B, Adalbert R, Wagner D, Grumme DS, Addicks K, Ribchester RR, Coleman MP. The progressive nature of Wallerian degeneration in wild-type and slow Wallerian degeneration (WldS) nerves. *BMC Neurosci* 2005;6:6.
51. Mraiwa N, Jacobs R, van Steenberghe D, Quirynen M. Clinical assessment and surgical implications of anatomic challenges in the anterior mandible. *Clin Implant Dent Relat Res* 2003;5:219–225.
52. Simpson HE. Injuries to the inferior dental and mental nerves. *J Oral Surg (Chic)*. 1958;16:300–305.
53. Bailey PH, Bays RA. Evaluation of long-term sensory changes following mandibular augmentation procedures. *J Oral Maxillofac Surg* 1984;42:722–727.
54. Pi X (ed). *Oral maxilla facial anatomy and physiology*. 3rd edition. Beijing: Ren Min Wei Sheng, 1994; 97–98, 119 (in Chinese).
55. Madeira MC, Percinoto C, das-Gracas-M-Silva M. Clinical significance of supplementary innervation of the lower incisor teeth: a dissection study of the mylohyoid nerve. *Oral Surg Oral Med Oral Pathol* 1978;46:608–614.
56. Ennis LM. Roentgenographic variations of the maxillary sinus and the nutrient canals of the maxilla and mandible. *Int J Orthod Oral Surg* 1937;23:173–193.
57. Kawai T, Sato I, Yosue T, Takamori H, Sunohara M. Anastomosis between the inferior alveolar artery branches and submental artery in human mandible. *Surg Radiol Anat*. 2006;28:308–310.
58. Ten Bruggenkate CM, Asikainen P, Foitzik C, Krekeler G, Sutter F. Short (6-mm) nonsubmerged dental implants: results of a multicenter clinical trial of 1 to 7 years. *Int J Oral Maxillofac Implants* 1998;13:791–798.
59. Van Assche N, van Steenberghe D, Guerrero ME, Hirsch E, Schutyser F, Quirynen M, Jacobs R. Accuracy of implant placement based on pre-surgical planning of three-dimensional cone-beam images: a pilot study. *J Clin Periodontol* 2007;34:816–821.
60. Loubele M, Guerrero ME, Jacobs R, Suetens P, van Steenberghe D. A comparison of jaw dimensional and quality assessments of bone characteristics with cone-beam CT, spiral tomography, and multi-slice spiral CT. *Int J Oral Maxillofac Implants* 2007;22:446–454.
61. Liang X, Jacobs R, Semal P, Corpas L, Martens W, Raymundo Júnior R, Lambrichts I. Modern human variability of neurovascular structures in the anterior mandible. *Dentomaxillofacial Radiology*. Presented at the 16th International Congress of the IADMFR, 26–30 June 2007, Beijing, China.