

Simultaneous Occurrence of an Autosomal Dominant Inherited MSX1 Mutation and an X-linked Recessive Inherited EDA Mutation in One Chinese Family with Non-syndromic Oligodontia

Xiao Xia ZHANG¹, Sing Wai WONG^{1,2}, Dong HAN¹, Hai Lan FENG¹

Objective: To describe the simultaneous occurrence of an autosomal dominant inherited MSX1 mutation and an X-linked recessive inherited EDA mutation in one Chinese family with non-syndromic oligodontia.

Methods: Clinical data of characteristics of tooth agenesis were collected. MSX1 and EDA gene mutations were detected in a Chinese family of non-syndromic oligodontia.

Results: Mild hypodontia in the parents and severe oligodontia in the son was recorded. A novel missense heterozygous mutation c.517C>A (p.Arg173Ser) was detected in the MSX1 gene in the boy and the father. A homozygous missense mutation c.1001G>A (p.Arg334His) was detected in the EDA gene in the boy and the same mutant occurred heterozygously in the mother.

Conclusion: Simultaneous occurrence of two different gene mutations with different inheritance patterns, which both caused oligodontia, which occurred in one subject and in one family, was reported.

Key words: EDA, inheritance, MSX1, mutation, oligodontia

Chin J Dent Res 2015;18(4):229–234; doi: 10.3290/j.cjdr.a35147

Hypodontia (the congenital missing of teeth, which is also known as tooth agenesis) is the most common developmental anomaly in men¹. Oligodontia, usually referring to a severe hypodontia, is defined as the congenital absence of six or more teeth, excluding the third molars, and may present as part of the syndrome, while the non-syndromic oligodontia is more commonly found². Although many oligodontia cases presented

sporadically without an inheritance trait, researchers have found more evidence that genetic defects play a major role in the aetiology^{3,4}. In the last two decades, mutations were identified to be associated with non-syndromic oligodontia in many genes, including muscle segment homeobox 1 (MSX1), paired box 9 (PAX9), axin inhibition protein 2 (AXIN2), wingless-type mouse mammary tumour virus integration site family member 10A (WNT10A), nuclear factor-kappa-B essential modulator (NEMO), keratin 17 (KRT17) and ectodysplasin A (EDA), that formerly was found to cause the most typically syndromic oligodontia of hypohidrotic ectodermal dysplasia (HED)/anhidrotic ectodermal dysplasia (EDA)⁵⁻¹⁷.

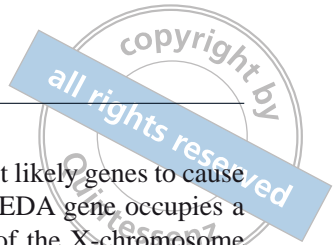Non-syndromic oligodontia has wide phenotypic heterogeneity and can be inherited in an autosomal dominant, autosomal recessive, or X-linked manner¹⁸, which were mostly autosomal dominant in the MSX1 mutation or an X-linked recessive trait in the EDA mutation.

1 Department of Prosthodontics, Peking University School and Hospital of Stomatology, Beijing, P.R. China.

2 Oral Biology Curriculum, School of Dentistry, University of North Carolina at Chapel Hill, Chapel Hill, NC, USA.

Corresponding author: Dr Hai Lan FENG, Department of Prosthodontics, Peking University School and Hospital of Stomatology, #22 Zhongguancun South Avenue, Haidian District, Beijing 100081, P.R. China. Tel: 86-10-82195232; Fax: 86-10-62173402. Email: kqfenghl@bjmu.edu.cn

This study was supported by grants from the National Natural Science Foundation (No.81070814 and No.81100725), and the Capital Medical Developing Foundation (No.2007-1005).



The *MSX1* gene located in 4p16.2 encodes a member of the muscle segment homeobox gene family. The encoded protein functions as a transcriptional repressor during embryogenesis through interactions with components of the core transcription complex and other homeoproteins. It may also have roles in limb-pattern formation, craniofacial development, particularly odontogenesis, and tumour growth inhibition¹¹. *MSX1* was the first gene identified causing family non-syndromic tooth agenesis in humans⁵, which was also reported to be associated with orofacial clefting (lip and palate cleft), tooth agenesis¹⁹ and Witkop syndrome, known as tooth and nail syndrome (TNS), a rare autosomal dominant disorder, with the characteristics of affected individuals having nail dysplasia and several congenitally missing teeth²⁰. Later, more mutations in *MSX1* were identified causing non-syndromic oligodontia^{6,21-25}, mostly missense mutations or nonsense mutations in autosomal dominant inheritance.

Almost at the same time when the *MSX1* mutation was first identified to be a cause of oligodontia, mutation in a novel transmembrane protein of *EDA* was found to cause X-linked anhidrotic ectodermal dysplasia (*EDA*)/hypohidrotic ectodermal dysplasia (*HED*)¹². Then, different *EDA* mutations were continuously identified to be associated with *EDA*/*HED* families or patients. Until 2006, it was reported that a novel missense mutation in the *EDA* gene in all affected males and carrier females of a Mongolian family, with only a congenital absence of teeth, inherited the mutation in an X-linked fashion. The affected members of the family did not show other *HED* characteristics, except hypodontia¹³. Ever since, many literatures reporting *EDA* mutations in non-syndromic oligodontia appeared^{14-16,26,27}, and the

EDA gene became one of the most likely genes to cause non-syndromic oligodontia. The *EDA* gene occupies a 425kb segment of the long arm of the X-chromosome (Xq12-13.1) and encodes a protein that belongs to the tumor necrosis factor (TNF) superfamily of ligands¹². In total, eight isoforms of *EDA* transcript can be created by differential splicing of the 12 exons²⁸. The phenotype and the mutation function analysis suggest that the threshold for *EDA* signaling in tooth development must be higher than in other *EDA*-dependent structures such as hair, sweat glands and skin²⁷.

In this study, two mutations in *MSX1* and *EDA* were identified, both in the boy and one in the father and the mother, which was inherited as an autosomal dominant trait and X-linked recessive trait respectively, in a Chinese family with non-syndromic oligodontia. It is very interesting that a rare co-occurrence arose in such a way. To our knowledge, no literature has been found reporting similar conditions.

Materials and methods

Subjects

A 16-year-old male patient requested treatment advice regarding some of his congenitally missing permanent teeth, and underwent the oral examination at the Department of Prosthodontics, Peking University, School and Hospital of Stomatology. It was confirmed that no teeth extraction occurred or any other developmental abnormalities, except the missing teeth, according to their medical history and the description given by his parents. Oral examination, cast analysis and panoramic

Table 1 The original teeth status of the subjects.

| Subjects | | Congenitally missing teeth | | | | | | | | | | | | | | | |
|----------|------|----------------------------|---|---|---|---|---|----|---|---|---|---|---|---|---|---|---|
| | | 8 | 7 | 6 | 5 | 4 | 3 | 2 | 1 | 1 | 2 | 3 | 4 | 5 | 6 | 7 | 8 |
| Son | Max. | * | * | | * | | § | * | * | | | § | | | | * | * |
| | Man. | * | | | | | | | * | * | | | | | | * | * |
| Father | Max. | * | # | | | | | & | | | & | | | | | # | * |
| | Man. | * | # | # | | | | | | | | | | | # | | * |
| Mother | Max. | * | | | | | | &# | | | & | | | | | | * |
| | Man. | * | | | | | | | * | * | | | | | | | # |

Note: Max – maxillary; Man – mandibular; 1 – incisor; 2 – lateral incisor; 3 – canine; 4 – first premolar; 5 – second premolar; 6 – first molar; 7 – second molar; 8 – third molar; * – congenitally missing permanent teeth; # – extracted teeth; & – conical-shaped teeth; §– ectopic eruption.

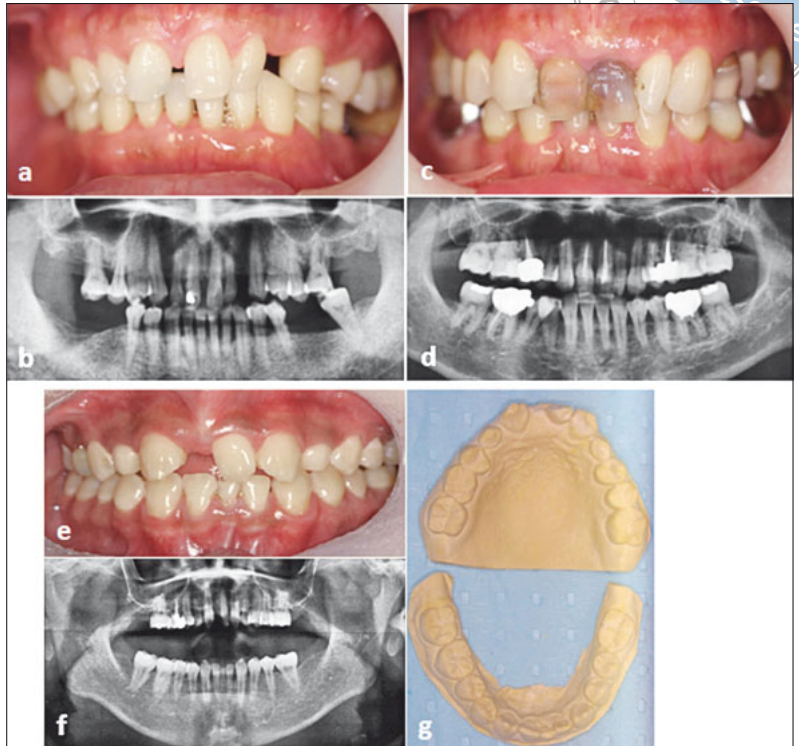


Fig 1 The clinical features of teeth in the family: a and b) the mild symptoms of maxillary later incisors and diastemas in the father (the panoramic radiograph was recorded after some of the molars were extracted, and not all the absent teeth in the picture were congenitally missing); c and d) the mother had two typical conical maxillary lateral incisors, where one had been extracted, and had two congenitally missing mandibular incisors; e to g) oral examination, panoramic radiograph and the plaster cast of the boy. All of these were analysed together, to identify the exact status of tooth agenesis.

radiographs revealed the diagnosis of non-syndromic oligodontia. His father and mother were recruited later and clinical data were collected as described above. They were both finally diagnosed with mild hypodontia. Peripheral blood was taken from the family for the subsequent detection of genomic mutations of candidate genes that associated with oligodontia, including *MSX1* and *EDA*. One hundred normal volunteers were selected as control individuals for the mutation detection experiments. The study was approved by the Institutional Review Board of Peking University School and Hospital of Stomatology. Informed consent was obtained from the family, as well as the normal controls.

DNA extraction and detection of mutations

Genomic DNA was extracted from peripheral blood lymphocytes using the Biotec DNA minikit (Biotek, Beijing, China) according to the manufacturer's instruction. Also genomic DNA of normal volunteers were extracted from the buccal epithelial cells using swab DNA minikit (Tiangen, Beijing, China), according to the manufacturer's instructions.

The entire coding region and the intron-exon junctions of *MSX1* and *EDA* genes were amplified by polymerase chain reaction (PCR) with Amplitaq Gold 360 Master Mix (Applied Biosystems, California, USA). The PCR

products were sent to the Sangon Biotech Company (Beijing, China) for direct sequencing, using a Big Dye terminator v3.1 (Applied Biosystems) and a 3730 DNA sequencer (Applied Biosystems). Primer sequences and PCR conditions were available upon request. SeaMan Pro genetic analysis software (DNASTAR, Wisconsin, USA) was used for sequencing analysis.

Results

Clinical data

The whole family including the proband boy and his parents, all of whom were in good physical health and well-being. Hypodontia only affected permanent dentitions. The original status of congenitally missing teeth and oral abnormalities at the first visit was recorded according to the examination and the medical history as in Table 1. The father had a full dentition of 28 teeth excluding the third molars, but there were diastemas in the maxillary anterior region due to the maxillary conical lateral incisors and the obvious smaller width of all present teeth (Table 1; Figs 1a and 1b). The father's panoramic radiograph in Figure 1 was taken when some of the molars were extracted for periodontal disease after several years had passed. The mother's two mandibu-

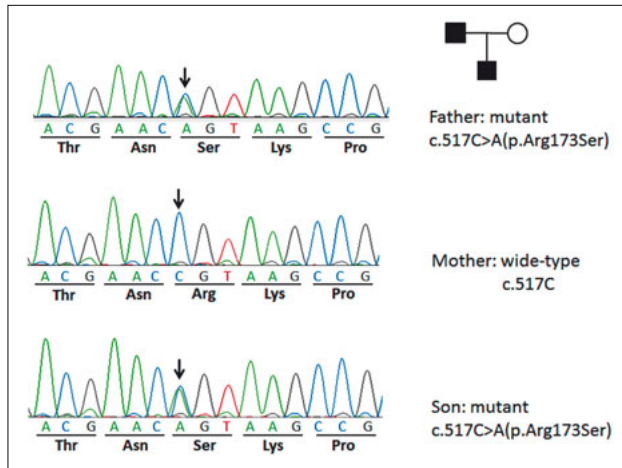
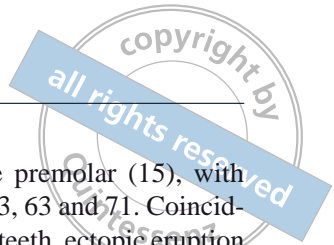


Fig 2 MSX1 missense heterozygous mutation was detected at the site of c. 517C>A (p.Arg173Ser) in the boy and the father, while it was not detected in the mother, which presented an autosomal dominant inheritance pattern.

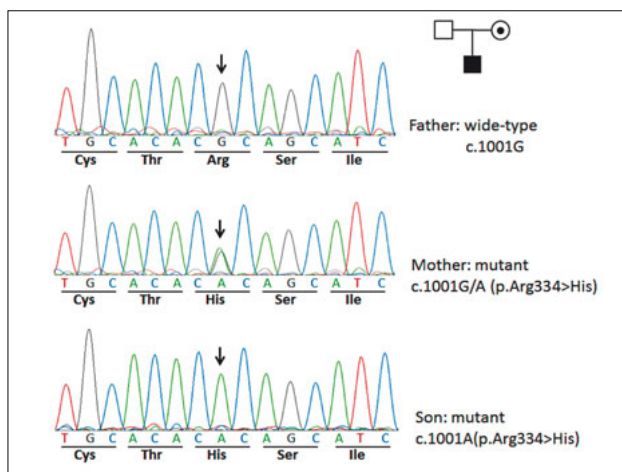


Fig 3 EDA homozygous missense mutation of c.1001G>A (p.Arg334His) was detected in the boy; the same mutant occurred heterozygously in the mother, while it was not detected in the father, which presented an X-linked recessive inheritance model.

lar incisors were congenitally missing with no space in the dentition, which was found only by thorough examination. She had two typical maxillary conical lateral incisors and the right one was extracted at a young age because of crowding. At least one of the third molars was developed and then extracted according to the medical recorder (Table 1, Figs 1c and 1d). The son had more severe congenitally missing teeth than his parents. In addition to the third molars, the congenitally missing teeth included five incisors (12, 11, 22, 31 and 41), three

molars (17, 27 and 37) and one premolar (15), with retained deciduous teeth i.e. 55, 53, 63 and 71. Coinciding with the congenitally missing teeth, ectopic eruption of both maxillary canines and the torquing left maxillary incisor were observed (Table 1; Figs 1e, 1f and 1g). The boy was the only child of the family, and there was no exact or reliable medical records obtained from the relatives of the parents about the tooth agenesis and other ectodermal dysplasia-related conditions.

Mutations detected

MSX1: A missense heterozygous mutation c. 517C>A (p.Arg173Ser) was detected in exon 2 of MSX1 in the boy and the father, however it was not detected in the mother (Fig 2)

EDA: A homozygous missense mutation of c.1001G>A (p.Arg334His) was detected in exon 8 of the EDA in the boy; the same mutant occurred heterozygously in the mother, while it was not detected in the father (Fig 3).

None of the mutations were detected in normal controls in this study.

Discussion

In a systematic review and meta-analysis on the genetic background of non-syndromic oligodontia, which includes articles published up to March 2012, it was reported that PAX9, EDA and MSX1 are the first three genes currently known to have a potential for causing non-syndromic oligodontia¹¹. Numerous literatures reported that different mutations in different genes may cause family non-syndromic oligodontia, but to our knowledge, it is unreported that two different mutations in the most common oligodontia-associated genes occurred in one family with different inheritance traits, which is a very uncommon occurrence.

The MSX1 gene mutation identified in this study is a novel mutation which occurred in exon 2 of the gene. Like most of the mutations previously identified in MSX1²¹⁻²⁴, the mutation found in this study was also a missense mutation c.517C>A that changed one amino acid (p.Arg173Ser) in the highly conserved homeodomain. However, the mutation of c.1001G>A (p.Arg334His) in exon 8 of the EDA gene in this family is the same as the known mutation reported¹⁵, and the previous structural analysis indicated that it would produce conformational changes, potentially altering the stability of the EDA homotrimers.

The most interesting thing in this study is the relationship between the genotypes and phenotypes, both

in individual appearance and in the family inheritance. It has been reported that the size of remaining teeth in oligodontia patients is significantly smaller compared to normal controls^{2,3}. This is the same with our clinical observation and previous studies²⁹. The summary of non-syndromic oligodontia phenotypes associated with mutations, showed that MSX1 mutations are more likely linked to the agenesis of the second premolar and the four third molars^{6,30}. While the hypodontia phenotype in EDA-associated non-syndromic tooth agenesis seems to favour the lack of incisors, other teeth are involved as well, and carrier females generally show a much milder phenotype with only one or two teeth missing or no symptoms at all²⁷.

In the present family, although the father had a full dentition of 28 teeth, he had no developed third molars and all remaining teeth showed a reduction in size, causing diastemas. The EDA mutation carrier mother just had mild symptoms i.e. absence of two mandibular incisors and peg-shaped maxillary incisors. However, the son inherited two sites of mutations through different traits, had a more severe phenotype of tooth agenesis than his parents, with congenitally missing teeth, mainly in the incisors and molars. Since c.518G>C (p.Arg173Pro) has been recorded as one of the MSX1 SNPs³¹, which is similar with the mutation in this study, it may be a mild mutation and may be associated with the third molar agenesis in the father and the son. The other tooth agenesis in the boy was probably affected more by the EDA mutation from the carrier mother. Further investigation, regarding the phenotypes, genotypes and mutant gene functions in this family is required.

Conflict of interest

The authors reported no conflicts of interest related to this study.

Author contribution

Dr Xiaoixa Zhang for the clinical data and blood sample collection, for designing the study and writing the paper; Dr Singwai Wong and Dr Dong Han for the mutation detection experiments; and Dr Hailan Feng for the overall design of the research.

References

1. De Coster PJ, Marks LA, Martens LC, Huyseune A. Dental agenesis: genetic and clinical perspectives. *J Oral Pathol Med* 2009;38:1–17.
2. Schalk-van der Weide Y, Steen WH, Bosman F. Distribution of missing teeth and tooth morphology in patients with oligodontia. *ASDC J Dent Child* 1992;59:133–140.
3. Nieminen P. Genetic basis of tooth agenesis. *J Exp Zool B Mol Dev Evol* 2009;312B:320–342.
4. Vastardis H. The genetics of human tooth agenesis: new discoveries for understanding dental anomalies. *Am J Orthod Dentofacial Orthop* 2000;117:650–656.
5. Vastardis H, Karimbux N, Guthua SW, Seidman JG, Seidman CE. A human MSX1 homeodomain missense mutation causes selective tooth agenesis. *Nat Genet* 1996;13:417–421.
6. Wong SW, Liu HC, Han D, et al. A novel non-stop mutation in MSX1 causing autosomal dominant non-syndromic oligodontia. *Mutagenesis* 2014;29:319–323.
7. Stockton DW, Das P, Goldenberg M, D'Souza RN, Patel PI. Mutation of PAX9 is associated with oligodontia. *Nat Genet* 2000;24:18–19.
8. Wang Y, Wu H, Wu J, et al. Identification and functional analysis of two novel PAX9 mutations. *Cells Tissues Organs* 2009;189:80–87.
9. Wong S, Liu H, Bai B, et al. Novel missense mutations in the AXIN2 gene associated with non-syndromic oligodontia. *Arch Oral Biol* 2014;59:349–353.
10. van den Boogaard MJ, Créton M, Bronkhorst Y, et al. Mutations in WNT10A are present in more than half of isolated hypodontia cases. *J Med Genet* 2012;49:327–331.
11. Ruf S, Klimas D, Hönemann M, Jabir S. Genetic background of nonsyndromic oligodontia: a systematic review and meta-analysis. *J Orofac Orthop* 2013;74:295–308.
12. Kere J, Srivastava AK, Montonen O, et al. X-linked anhidrotic (hypohidrotic) ectodermal dysplasia is caused by mutation in a novel transmembrane protein. *Nat Genet*. 1996;13:409–416.
13. Tao R, Jin B, Guo SZ, et al. A novel missense mutation of the EDA gene in a Mongolian family with congenital hypodontia. *J Hum Genet*. 2006;51:498–502.
14. Han D, Gong Y, Wu H, et al. Novel EDA mutation resulting in X-linked non-syndromic hypodontia and the pattern of EDA-associated isolated tooth agenesis. *Eur J Med Genet* 2008;51:536–546.
15. Song S, Han D, Qu H, et al. EDA gene mutations underlie non-syndromic oligodontia. *J Dent Res* 2009;88:126–131.
16. Sarkar T, Bansal R, Das P. Whole genome sequencing reveals novel non-synonymous mutation in ectodysplasin A (EDA) associated with non-syndromic X-linked dominant congenital tooth agenesis. *PLoS One* 2014;9:e106811.
17. Bergendal B, Klar J, Stecksén-Blicks C, Norderyd J, Dahl N. Isolated oligodontia associated with mutations in EDARADD, AXIN2, MSX1, and PAX9 genes. *Am J Med Genet A* 2011;155A:1616–1622.
18. Burzynski NJ, Escobar VH. Classification and genetics of numeric anomalies of dentition. *Birth Defects Orig Artic Ser* 1983;19:95–106.
19. van den Boogaard MJ, Dorland M, Beemer FA, van Amstel HK. MSX1 mutation is associated with orofacial clefting and tooth agenesis in humans. *Nat Genet* 2000;24:342–343.
20. Jumlongras D, Bei M, Stimson JM, et al. A nonsense mutation in MSX1 causes Witkop syndrome. *Am J Hum Genet*. 2001;69:67–74.
21. De Mynck S, Schollen E, Matthijs G, Verdonck A, Devriendt K, Carels C. A novel MSX1 mutation in hypodontia. *Am J Med Genet A*. 2004;128A:401–403.
22. Kim JW, Simmer JP, Lin BP, Hu JC. Novel MSX1 frameshift causes autosomal-dominant oligodontia. *J Dent Res* 2006;85:267–271.
23. Xuan K, Jin F, Liu YL, et al. Identification of a novel missense mutation of MSX1 gene in Chinese family with autosomal-dominant oligodontia. *Arch Oral Biol* 2008;53:773–779.

24. Kamamoto M, Machida J, Yamaguchi S, et al. Clinical and functional data implicate the Arg(151)Ser variant of MSX1 in familial hypodontia. *Eur J Hum Genet* 2011;19:844–850.
25. Kimura M, Machida J, Yamaguchi S, et al. Novel nonsense mutation in MSX1 in familial nonsyndromic oligodontia: subcellular localization and role of homeodomain/MH4. *Eur J Oral Sci* 2014;122:15–20.
26. Tarpey P, Pemberton TJ, Stockton DW, et al. A novel Gln358Glu mutation in ectodysplasin A associated with X-linked dominant incisor hypodontia. *Am J Med Genet A* 2007;143:390–394.
27. Mues G, Tardivel A, Willen L, et al. Functional analysis of Ectodysplasin-A mutations causing selective tooth agenesis. *Eur J Hum Genet* 2010;18:19–25.
28. Bayés M, Hartung AJ, Ezer S, et al. The anhidrotic ectodermal dysplasia gene (EDA) undergoes alternative splicing and encodes ectodysplasin-A with deletion mutations in collagenous repeats. *Hum Mol Genet* 1998;7:1661–1669.
29. Zhang XX, Feng HL. Clinical characteristic analysis of oligodontia [in Chinese]. *Journal of Modern Stomatology* 2005;19:7–9.
30. Yin W, Bian Z. The gene network underlying hypodontia. *J Dent Res* 2015;94:878–885.
31. rs569734431 [Homo sapiens] in NCBI SNP database. Accessed: Available at: <http://www.ncbi.nlm.nih.gov/snp/?term=rs569734431>

