

Morphologic Analysis of Maxillary Sinus Floor and its Correlation to Molar Roots using Cone Beam Computed Tomography

Ya Qiong ZHANG¹, Xue Bing YAN², Yuan MENG¹, Ya Ning ZHAO¹, Deng Gao LIU¹

Objective: To analyse the anterior extension of the maxillary sinus, distribution of the sinus septa and vertical relationship between the maxillary sinus and molar roots using cone beam computed tomography (CBCT).

Methods: Imaging data of 970 consecutive patients who underwent CBCT scans were retrospectively collected. The anterior border, septa distribution of the maxillary sinus and relationship between the maxillary sinus and molar roots were analysed. The root–sinus relationship was divided into three types; the roots protruding into the sinus or touching the floor without a bony barrier was defined as Type I root–sinus relationship.

Results: Overall, 15.5% of the maxillary sinuses extended beyond the incisor region and 68.9% extended beyond the canine region. A bony septum of ≥ 2 mm was detected in 16.9% (328/1940) of the maxillary sinuses from 26.0% (252/970) of the patients. Among the 355 septa in the 328 sinuses with septa, 108 (30.4%) were located at the first and second premolar region, 180 (50.7%) at the first and second molar region and 67 (18.9%) posterior to the second molar. Among the first molars, a Type I root–sinus relationship was detected in 61.0% of palatine roots, 55.4% of distobuccal (DB) roots, and 52.7% of mesiobuccal (MB) roots. Moreover, among three-rooted second molars, a Type I relationship was detected in 62.0%, 58.2% and 45.8% of MB, DB and palatine roots, respectively.

Conclusion: The maxillary sinus can extend beyond the incisor region; approximately 1/6 of sinuses have bony septa; and 1/2 of molar roots protrude into the maxillary sinus or touch the sinus floor without a bony barrier.

Key words: maxillary sinus, sinus septum, sinus border, maxillary molar, cone beam computed tomography (CBCT)

Chin J Dent Res 2019;22(1):29–36; doi: 10.3290/j.cjdr.a41772

The maxillary sinus is an important anatomical structure of the midface region. The development of modern dentistry, particularly implantation, necessitates a precise knowledge of the anatomical structure

of the maxillary sinus, including the sinus border, septa on the sinus floor and the relationship between the molar roots and the sinus floor. Anterior pneumatization of the sinus is occasionally encountered on dental periapical or panoramic radiographs and might be misunderstood as a cystic lesion. However, few reports have focused on the anterior border of the maxillary sinus. Maxillary sinus septa are barriers of cortical bone that divide the maxillary sinus floor into two or more compartments^{1,2}. During sinus floor augmentation surgery, the presence of a maxillary sinus septa may complicate the creation of an access window into the lateral sinus wall as well as elevation of the sinus membrane from the bony sinus floor. The risk of sinus membrane perforation is reportedly increased during such procedures³⁻⁵. The prevalence

1 Department of Oral and Maxillofacial Radiology, Peking University School and Hospital of Stomatology, National Engineering Laboratory for Digital and Material Technology of Stomatology, Beijing Key Laboratory of Digital Stomatology, Beijing, P.R. China.
2 Special Dental Department, First Clinical Division, Peking University School and Hospital of Stomatology, Beijing, P.R. China

Corresponding author: Dr Deng Gao LIU, Department of Oral and Maxillofacial Radiology, Peking University School and Hospital of Stomatology, 22# Zhongguancun South Avenue, HaiDian District, Beijing 100081, P.R. China. Tel: 86 10 82195326; Fax: 86 10 62173402. Email: kqldg@bjmu.edu.cn

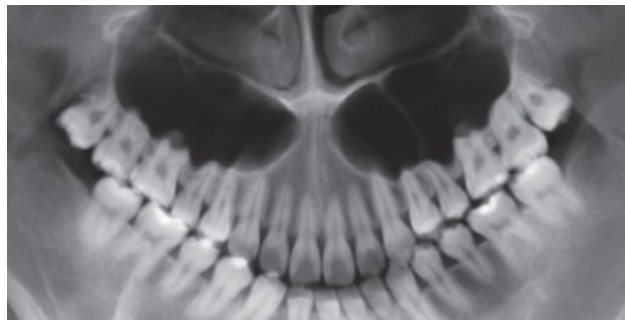


Fig 1 Anterior border of the maxillary sinus extended beyond the central incisor.

of maxillary sinus septa varies distinctly among 7% to 70% according to former studies that used panoramic radiograph, cone beam computed tomography (CBCT) and computed tomography (CT)^{2,6-12}. Recognition of the anatomical relationship of teeth relative to the maxillary sinus is essential for a successful endodontic or tooth extraction procedure. The bone barrier between the root and the inferior sinus floor can be thin, and the spreading of a periapical or periodontal infection can probably cause maxillary sinusitis¹³⁻¹⁷. Of note, oro-antral fistula or root displacement into the sinus cavity is a frequent complication after extraction of first and second molars; moreover, intrusion or bodily movement of teeth across the sinus floor by orthodontic treatment has been known to cause moderate apical root resorption¹⁸. Reportedly, 10% to 36.7% of maxillary molars protrude into the sinus^{13,15,19}. These marked differences in the aforementioned findings regarding the prevalence of sinus septa and the sinus–molar root relationship might be explained by differences of ethnic background, sampling size, imaging modality and interpretation of anatomical structures^{20,21}. Furthermore, there are no comprehensive studies of the maxillary sinus that con-

sider anterior pneumatization, sinus septa distribution and the sinus–molar root relationship, particularly in the population of northern China. Nowadays, CBCT images providing high-resolution three-dimensionality are commonly used in dental practice, which facilitates a thorough analysis of these anatomic structures.

The present study aimed to investigate the anterior pneumatization of the maxillary sinus, the prevalence and distribution of the sinus septa, and the relationship between the sinus floor and molar roots in the population of the Beijing area through the use of CBCT.

Materials and methods

Subjects

In this retrospective study, CBCT images of patients who presented at our imaging centre from January to December 2015 were retrospectively collected and evaluated. The study design was approved by the institutional review board of our school (PKUSSIRB-201732010).

Inclusion criteria included:

- patients aged 18 to 45 years;
- complete dentition (third molar as an exclusion);
- field of view (FOV) of 15 × 15 cm, with the entire maxillary sinus visible;
- high-quality images without motion or beam-hardening artefacts.

Exclusion criteria included the presence of:

- periapical or severe periodontal lesions, endodontic or implantation treatments;
- tumoral lesions, cleft lip and palate or systematic diseases;
- orthodontic or orthognathic treatment.

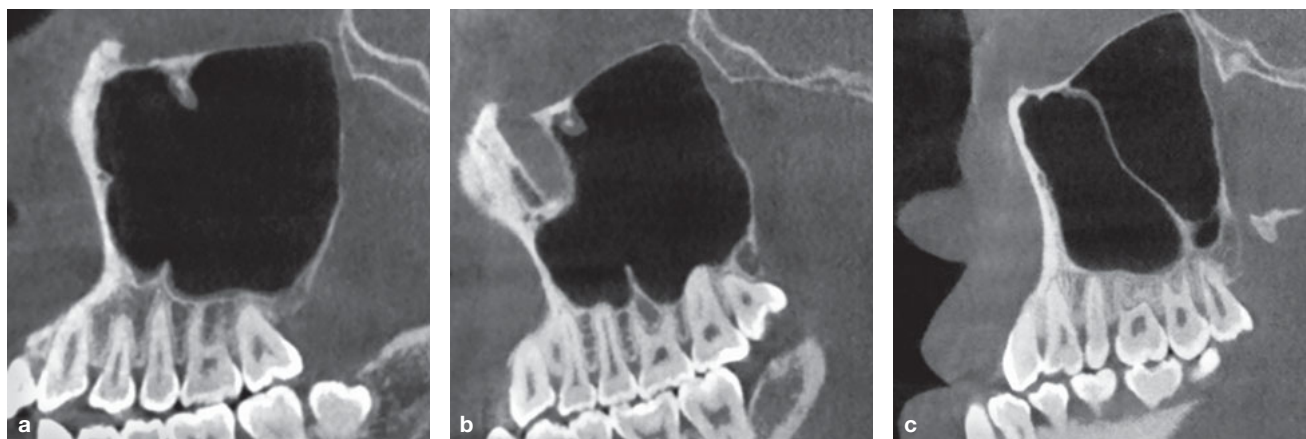


Fig 2 Illustrations of different locations of the sinus septa. (a) Anterior. (b) Middle. (c) Posterior.

A total of 970 patients took part in the study, including 341 men and 629 women ranging in age between 18 and 42 years (mean: 26.2). High-quality CBCT images were acquired from all patients.

Evaluation of CBCT images

CBCT images were obtained using NewTom VGi (QR s.r.l. Verona, Italy) with the following exposure settings: 110 kV, automatic mA and 3.6 s impulsive exposure. The voxel size was 200 μ m during the reconstruction of the volume data. The NNT software (version 4.00.1; Verona, Italy) provided by the CBCT machine was utilized for data analysis. All images were assessed respectively by two experienced oral radiologists. In the event of a disagreement, the cases were discussed until a consensus was reached.

For each patient, the anterior pneumatization of the maxillary sinus was initially observed on axial images set parallel to the occlusal plane and recorded according to the corresponding tooth position via a reconstructed panoramic view set perpendicular to the occlusal plane (Fig 1). An inferiorly extended maxillary sinus was defined as ≥ 3 teeth touching the sinus floor. Meanwhile, the molar relationship was recorded as Class I to III based on Angle's classification.

The floor of the maxillary sinus, combined with the inferior lateral wall, was observed under multiplanar reconstruction (MPR) images, and the presence and number of septa were recorded. As suggested by Naitoh et al³, only bony septa of ≥ 2 mm in height were registered. The septa locations were classified into three types relative to the neighbouring tooth: anterior (pre-molar region), middle (first and second molar region)

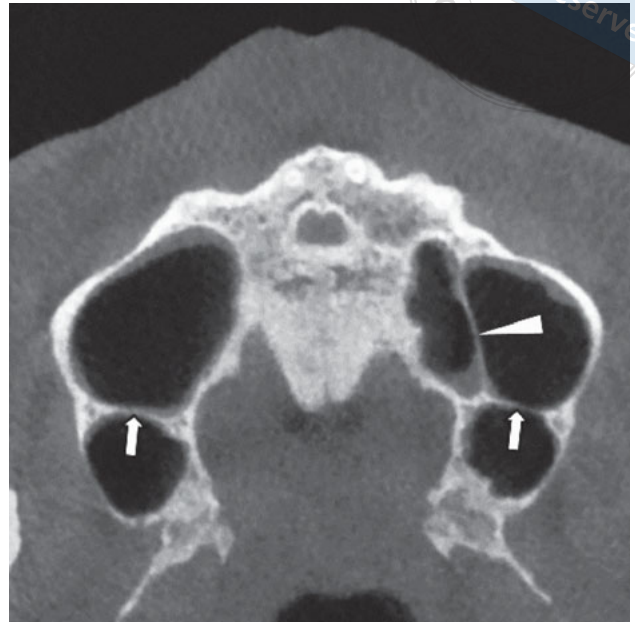

Fig 3 Two buccopalatal septa (\uparrow) and one sagittal septum (\blacktriangle) were observed on the axial view of the CBCT scan.

and posterior (posterior to the second molar) (Fig 2). Furthermore, the orientation of the septa was classified as sagittal and coronal (Fig 3).

The vertical relationship between each molar root and the sinus floor was classified into three types (Fig 4):

- Type I: The root penetrated into the sinus floor or touched the sinus floor with cortical bone discontinuity.
- Type II: The root touched the sinus floor with continual cortical bone or the distance between the sinus floor and the root apex was < 2 mm.

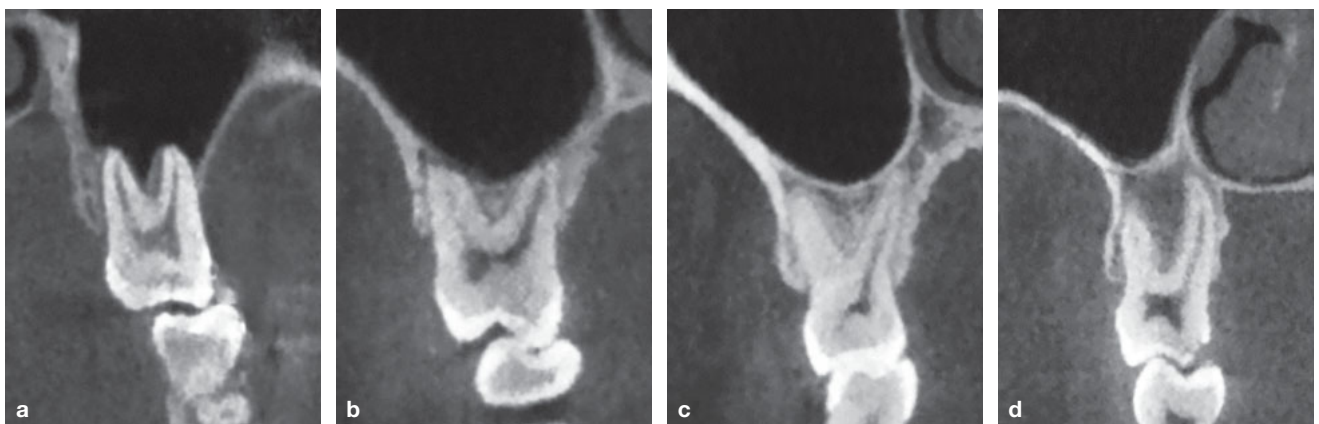


Fig 4 Classification of the vertical relationship between molar roots and the maxillary sinus floor. (a) Mesio Buccal and palatal roots of the molar penetrated into the sinus floor (Type I). (b) Distobuccal and palatal roots of the molar touched the sinus floor with cortical bone discontinuity (Type I). (c) The palatal root of the molar contacted the sinus floor with continual cortical bone (Type II). (d) The distance between the sinus floor and molar roots was > 2 mm (Type III).



Table 1 Distribution of 355 septa among 252 patients.

| | | | Anterior | Middle | Posterior |
|------------------|---------------------------|----------|----------|--------|-----------|
| Unilateral septa | L N = 80 | 1 septum | 27 | 37 | 11 |
| | | 2 septa | 2 | 7 | 1 |
| | | 3 septa | 0 | 0 | 0 |
| | R N = 96 | 1 septum | 30 | 45 | 13 |
| | | 2 septa | 7 | 4 | 3 |
| | | 3 septa | 1 | 1 | 1 |
| Bilateral septa | 2 symmetric septa n = 26 | L | 7 | 10 | 9 |
| | | R | 7 | 10 | 9 |
| | 2 asymmetric septa n = 39 | L | 10 | 23 | 6 |
| | | R | 9 | 25 | 5 |
| | 3 septa | L | 2 | 9 | 3 |
| | | R | 3 | 7 | 3 |
| | N = 9 | L | 2 | 1 | 1 |
| | | R | 1 | 1 | 2 |
| 4 septa | L | 2 | 1 | 1 | |
| | R | 1 | 1 | 2 | |
| Total | | | 108 | 180 | 67 |

L: Left; R: Right.

- Type III: The distance between the sinus floor and root apex was ≥ 2 mm.

Statistical analyses

Statistical analyses were conducted using the SPSS software (version 22.0; IBM, Chicago, IL) to investigate the prevalence of the anterior border of the maxillary sinus, the distribution of the sinus septum and variations in the root–sinus floor relationship. In addition, chi-square tests were performed to assess differences among laterality and gender. $P < 0.05$ was considered statistically significant. In terms of the vertical relationship between the sinus floor and molar roots, patients were classified into two groups according to their median age (24.5 years): ≤ 24 and > 24 years. Chi-square tests were also conducted to compare the difference between the two age groups.

Results

Anterior border of maxillary sinus

Overall, 3.4% of the maxillary sinus extended anteriorly into the central incisor region (Fig 1), 12.1% into the lateral incisor, 68.9% into the canine, 14.2% into the first premolar, and the remaining 1.4% into the second premolar or first molar region. The anterior pneumatization did not statistically differ between men and women or between the two sides of the sinuses ($P = 0.909$).

The prevalence of an inferiorly extended maxillary sinus was 52.3% (152/291) in Class I molar relationships, 51.0% (176/346) in Class II and 53% (176/333) in Class III molar relationships, and no significant differences were found among these three types ($P = 0.937$). In addition, statistical analysis showed no gender differences in the prevalence of inferiorly extended maxillary sinus ($P = 0.549$).

Table 2 Vertical correlation of the maxillary sinus floor to the first and three-rooted second maxillary molars.

| Root | Type I | Type II | Type III |
|------|--------|---------|----------|
| 6MB | 52.7% | 22.9% | 24.5% |
| 6MD | 55.4% | 21.1% | 23.0% |
| 6P | 61.0% | 14.6% | 23.8% |
| 7MB | 62.0% | 19.4% | 18.6% |
| 7MD | 58.2% | 22.1% | 19.7% |
| 7P | 45.8% | 22.9% | 31.3% |

6: First maxillary molar; 7: Second maxillary molar; MB: mesiobuccal; MD: mesiodistal; P: palatal.

Prevalence of septa on the maxillary sinus floor (Table 1)

A bony septum of ≥ 2 mm was detected in 16.9% (328/1940) of the maxillary sinuses from 26.0% (252/970) of the patients. Among the patients with sinus septa, 80 (31.7%) had septa on the floor of the left maxillary sinus, 96 (38.1%) had septa on the right side, and 76 (30.2%) had septa on both sides. Among the 328 sinuses with septa, 302 (92.1%) sinuses had a single septum, 25 (7.6%) had two septa, and 1 (0.3%) had three septa. In terms of septa location, 180 (50.7%) septa were located in the middle region of the sinus floor, 108 (30.4%) in the anterior region, and 67 (18.9%) in the posterior region. The orientation of the septa was transverse (bucopalatal) in 323 (91.0%) and sagittal (mesiodistal) in 32 (9.0%). Moreover, in terms of septa prevalence, no significant differences were detected between men and women or between the two sides of the maxillary sinuses ($P = 0.383$).

Vertical relationship of molar roots and the maxillary sinus floor (Table 2)

All the maxillary first molars were three-rooted. Among first molars, a Type I root–sinus relationship was detected in 61.0% of palatine roots, 55.4% of distobuccal (DB) roots and 52.7% of mesiobuccal (MB) roots. Among second molars, 20.5% had one fused root, 24.9% had two roots, 53.5% had three roots and 1.1% had four roots. Among three-rooted second molars, a Type I root–sinus relationship was detected in 62.0% of MB roots, 58.2% of DB roots and 45.8% of palatine roots. Of the total number of roots, a Type I relationship was detected in 56.7%, 50.0% and 59.4% of one-, two- and four-rooted second molars, respectively. Statistical analysis showed

no gender differences of root–sinus relationship in all the different roots ($P > 0.05$); however, significant differences were found between two sides of the root–sinus relationship in MB ($P = 0.016$) and DB ($P = 0.001$) roots of the first molar and palatine roots ($P = 0.005$) of the second molar. Additionally, it was revealed that a Type I relationship occurred more frequently in all the different roots of the ≤ 24 -year age group ($P < 0.05$), particularly in the first molar (Table 3), compared with that of the > 24 -year age group.

Discussion

As an important structure of the midfacial area, paranasal sinuses act as shock absorbers, account for weight reduction of the head and are involved in voice resonance. Maxillary sinus pneumatization is a physiological process; its volume increases after 12 to 13 years of age and ends with the completion of third molar eruption at 18 years²². It is known that the volume of the maxillary sinus varies among the adult population; nevertheless, few studies have focused on the anterior extension of the sinus. The present study revealed that the anterior border of the maxillary sinus could reach the central or lateral incisor regions. Clinically, a huge-sized maxillary sinus could be misdiagnosed as an alveolar cyst on conventional radiographs. In addition, in cases of implants, an excessive extension of the sinus beyond the incisors might diminish the available bone volume of this region.

Maxillary sinus septum is considered to be primarily formed by chewing pressure. Previous studies have reported varied prevalence of maxillary sinus septum, which could be related to age, ethnicity and imaging modality². By using CBCT, Qian et al²³, Shahidi et al²⁴, and Naitoh et al³ found that the prevalence of

Table 3 Vertical relationship between molar roots and sinus floor in two age groups.

| | | 1st molar | | | Three-rooted second molar | | | One-rooted second molar | Two-rooted second molar |
|----------|----------|-----------|-------|-------|---------------------------|-------|-------|-------------------------|-------------------------|
| | | MB | DB | P | MB | DB | P | | |
| ≤ 24 yrs | Type I | 65.5% | 67.9% | 71.5% | 71.9% | 65.1% | 50.8% | 64.4% | 60.0% |
| | Type II | 20.3% | 18.4% | 12.3% | 17.8% | 22.4% | 24.4% | 21.4% | 22.5% |
| | Type III | 14.2% | 13.7% | 16.2% | 10.3% | 12.5% | 24.8% | 14.2% | 17.5% |
| > 24 yrs | Type I | 39.7% | 43.6% | 51.5% | 52.4% | 51.6% | 41.0% | 48.9% | 39.8% |
| | Type II | 25.5% | 23.8% | 17.0% | 20.9% | 21.7% | 21.5% | 31.6% | 28.6% |
| | Type III | 34.8% | 32.6% | 31.5% | 26.7% | 26.7% | 37.5% | 19.5% | 31.6% |

Note: Four-rooted second molars were not catalogued because only 16 patients were observed.

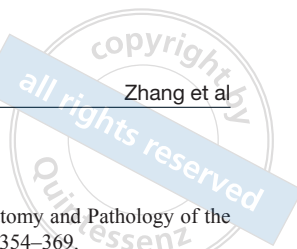septa varied from 37% to 57.6%. In 2012, Pommer et al² reviewed the available literature from 1995 to 2011 and summarized that the prevalence of maxillary sinus septa ranged from 24.3% to 32.5%. In the present study, the prevalence, location and orientation of septa were observed using high-resolution CBCT images. The results revealed that 16.9% of sinuses had septa on the floor of the maxillary sinuses. The prevalence of maxillary sinus septa was slightly lower than that reported in previous studies. One reason was that only septa of ≥ 2 mm detectable on the maxillary sinus floor and inferior lateral wall were registered, in view of the fact that septa ≥ 2 mm in height significantly impede the success rate in sinus floor elevation^{3,24}; and septa originating from other sinus walls were not listed. Moreover, all patients possessed complete dentition in the present study; the aim was to reveal the intrinsic prevalence of maxillary sinus septa and to avoid the bias of a secondary septum in edentulous patients^{2,21,25}.

Furthermore, the total number and proportion of different types of septa varied in previous studies. In the present study, 92.1% of sinuses had a single septum, 7.6% had two septa, and 0.3% had three septa. This was similar to the result reported by Qian et al²³ and may be explained by the fact that the two studies were performed among the same population. In addition, 30.4% of the sinus septa in the present study were situated in the premolar region, 50.7% in the middle region, and 18.9% posterior to the second molar region, which was similar to previous reports^{3,26}. This could be attributed to the fact that the middle region sustained more masti-

catory pressure than other regions³. Clinically, surgical elevation of the maxillary sinus floor was primarily performed in the maxillary first and second molar region, necessitating preoperative CBCT evaluation to minimize probable complications.

Previous studies have shown close proximity between the root apex of the maxillary posterior teeth and the maxillary sinus floor by means of CBCT; however, the criteria for this relationship suggested by those authors were different^{19,27,28}. Ok et al¹⁵ and Tian et al¹³ evaluated each root of maxillary molars according to three types: below the sinus floor, contacting with the sinus floor and penetrating into the sinus floor. Jung and Cho²⁹ evaluated each root of the maxillary molars according to four types: no touching, touching the cortical borders of the sinus, projecting laterally on the sinus cavity and protruding into the sinus.

The criteria used in the present study was a modification of the criteria used in the study by Jung and Cho²⁹. The vertical relationship between each molar root and the sinus floor was classified into three types. In Type I, the root penetrated into the sinus floor or touched the sinus floor with cortical bone deficiency. This type of relationship represents the closest proximity between the root and the sinus floor, and special care should be taken to avoid any procedural complications. Obviously, the spatial resolution of CBCT images was crucial for observing the continuity of the cortical border on the maxillary sinus floor. In the present study, the CBCT images with a voxel size of 200 μ m confirmed a satisfactory image quality. Results revealed that a Type I



relationship occurred most frequently in the MB roots of maxillary second molars (62.0%) and least often in the palatine roots of second molars (45.8%). This implied that approximately half of molar roots protruded into the maxillary sinus or touched the sinus floor without a cortical bone barrier and, therefore, posed a risk of infection during endodontic procedures or oroantral fistula formation during tooth extraction surgery. Moreover, severe deficiency of the bone height could be anticipated if an implant surgery was needed. The percentage of Type I relationships in the > 24-year age group was lower than that in the ≤ 24-year group, which implied that the distance between the sinus floor and the maxillary posterior teeth increased with age, as described by Ok et al¹⁵ and Tian et al¹³. In the present study, the proportion of roots protruding into the sinus appeared to be higher than that reported by Ok et al¹⁵ (25.9% to 34.2%) and Tian et al¹³ (32.8% to 44.75%), which can be attributed to the different criteria and the age ranges of the patients. Patient age in the present study ranged from 18 to 42 years, while in the studies conducted by Ok et al¹⁵ and Tian et al¹³ it ranged from 14 to 84 years. The relatively younger age range in the present study might have led to an overestimation of the Type I root–sinus relationship, and this should be regarded as a shortcoming of our study. Further studies of older age groups, as well as edentulous patients, should be conducted in future.

In conclusion, the maxillary sinus can extend anteriorly beyond the incisor region. Approximately a quarter of patients or 1/6 of sinuses have bony septa that are ≥ 2 mm in height on the sinus floor, and half of the septa are located in the first and second molar region. Half of molar roots protrude into the maxillary sinus or touch the sinus floor without a bony barrier. These anatomical features provided by CBCT are helpful for planning and performing relevant endodontic, tooth extraction and implant procedures.

Conflicts of interest

The authors report no conflicts of interest related to this study.

Author contribution

Dr Ya Qiong ZHANG acquired and analysed the case data and prepared the manuscript; Drs Xue Bing YAN, Yuan MENG and Ya Ning ZHAO analysed the radiological data; Professor Deng Gao LIU designed and supervised the study and revised the manuscript.

(Received March 29, 2018; accepted May 22, 2018)

References

- Underwood AS. An Inquiry into the Anatomy and Pathology of the Maxillary Sinus. *J Anat Physiol* 1910;44:354–369.
- Pommer B, Ulm C, Lorenzoni M, Palmer R, Watzek G, Zechner W. Prevalence, location and morphology of maxillary sinus septa: systematic review and meta-analysis. *J Clin Periodontol* 2012;39:769–773.
- Naitoh M, Suenaga Y, Kondo S, Gotoh K, Arijji E. Assessment of maxillary sinus septa using cone-beam computed tomography: etiological consideration. *Clin Implant Dent Relat Res* 2009;11(suppl 1):e52–e58.
- Park YB, Jeon HS, Shim JS, Lee KW, Moon HS. Analysis of the anatomy of the maxillary sinus septum using 3-dimensional computed tomography. *J Oral Maxillofac Surg* 2011;69:1070–1078.
- Mafee MF, Chow JM, Meyers R. Functional endoscopic sinus surgery: anatomy, CT screening, indications, and complications. *AJR Am J Roentgenol* 1993;160:735–744.
- Gandhi KR, Wabale RN, Siddiqui AU, Farooqui MS. The incidence and morphology of maxillary sinus septa in dentate and edentulous maxillae: a cadaveric study with a brief review of the literature. *J Korean Assoc Oral Maxillofac Surg* 2015;41:30–36.
- Maestre-Ferrín L, Galán-Gil S, Rubio-Serrano M, Peñarrocha-Diogo M, Peñarrocha-Oltra D. Maxillary sinus septa: a systematic review. *Med Oral Patol Oral Cir Bucal* 2010;15:e383–e386.
- Li Z, Fa YH, Wang YF, Li B. Research progress on maxillary sinus septa [in Chinese]. *Guo Ji Kou Qiang Yi Xue Za Zhi (Int J Stomatol)* 2015;42:40–43.
- Orhan K, Kusakci Seker B, Aksoy S, Bayindir H, Berberoğlu A, Seker E. Cone beam CT evaluation of maxillary sinus septa prevalence, height, location and morphology in children and an adult population. *Med Princ Pract* 2013;22:47–53.
- Tadinada A, Jalali E, Al-Salman W, Jambhekar S, Katechia B, Almas K. Prevalence of bony septa, antral pathology, and dimensions of the maxillary sinus from a sinus augmentation perspective: A retrospective cone-beam computed tomography study. *Imaging Sci Dent* 2016;46:109–115.
- van Zyl AW, van Heerden WF. A retrospective analysis of maxillary sinus septa on reformatted computerised tomography scans. *Clin Oral Implants Res* 2009;20:1398–1401.
- Sakhdari S, Panjnoush M, Eyvazlou A, Niktash A. Determination of the Prevalence, Height, and Location of the Maxillary Sinus Septa Using Cone Beam Computed Tomography. *Implant Dent* 2016;25:335–340.
- Tian XM, Qian L, Xin XZ, Wei B, Gong Y. An Analysis of the Proximity of Maxillary Posterior Teeth to the Maxillary Sinus Using Cone-beam Computed Tomography. *J Endod* 2016;42:371–377.
- Selden HS. The endo-antral syndrome: an endodontic complication. *J Am Dent Assoc* 1989;119:397–398, 401–402.
- Ok E, Güngör E, Colak M, Altunsoy M, Nur BG, Ağlarci OS. Evaluation of the relationship between the maxillary posterior teeth and the sinus floor using cone-beam computed tomography. *Surg Radiol Anat* 2014;36:907–914.
- Hauman CH, Chandler NP, Tong DC. Endodontic implications of the maxillary sinus: a review. *Int Endod J* 2002;35:127–141.
- Arijji Y, Obayashi N, Goto M, et al. Roots of the maxillary first and second molars in horizontal relation to alveolar cortical plates and maxillary sinus: computed tomography assessment for infection spread. *Clin Oral Investig* 2006;10:35–41.
- Sharan A, Madjar D. Correlation between maxillary sinus floor topography and related root position of posterior teeth using panoramic and cross-sectional computed tomography imaging. *Oral Surg Oral Med Oral Pathol Oral Radiol Endod* 2006;102:375–381.
- Kilic C, Kamburoglu K, Yuksel SP, Ozen T. An Assessment of the Relationship between the Maxillary Sinus Floor and the Maxillary Posterior Teeth Root Tips Using Dental Cone-beam Computerized Tomography. *Eur J Dent* 2010;4:462–467.

20. González-Santana H, Peñarrocha-Diago M, Guarinos-Carbó J, Sorní-Bröker M. A study of the septa in the maxillary sinuses and the subnasal alveolar processes in 30 patients. *J Oral Implantol* 2007;33:340–343.
21. Krennmair G, Ulm CW, Lugmayr H, Solar P. The incidence, location, and height of maxillary sinus septa in the edentulous and dentate maxilla. *J Oral Maxillofac Surg* 1999;57:667–671.
22. Lorkiewicz-Muszyńska D, Kociemba W, Rewekant A, et al. Development of the maxillary sinus from birth to age 18. Postnatal growth pattern. *Int J Pediatr Otorhinolaryngol* 2015;79:1393–1400.
23. Qian L, Tian XM, Zeng L, Gong Y, Wei B. Analysis of the Morphology of Maxillary Sinus Septa on Reconstructed Cone-Beam Computed Tomography Images. *J Oral Maxillofac Surg* 2016;74:729–737.
24. Shahidi S, Zamiri B, Momeni Danaei S, Salehi S, Hamedani S. Evaluation of Anatomic Variations in Maxillary Sinus with the Aid of Cone Beam Computed Tomography (CBCT) in a Population in South of Iran. *J Dent (Shiraz)* 2016;17:7–15.
25. Shen EC, Fu E, Chiu TJ, Chang V, Chiang CY, Tu HP. Prevalence and location of maxillary sinus septa in the Taiwanese population and relationship to the absence of molars. *Clin Oral Implants Res* 2012;23:741–745.
26. Kim MJ, Jung UW, Kim CS, et al. Maxillary sinus septa: prevalence, height, location, and morphology. A reformatted computed tomography scan analysis. *J Periodontol* 2006;77:903–908.
27. Yoshimine S, Nishihara K, Nozoe E, Yoshimine M, Nakamura N. Topographic analysis of maxillary premolars and molars and maxillary sinus using cone beam computed tomography. *Implant Dent* 2012;21:528–535.
28. Fry RR, Patidar DC, Goyal S, Malhotra A. Proximity of maxillary posterior teeth roots to maxillary sinus and adjacent structures using Denta scan®. *Indian J Dent* 2016;7:126–130.
29. Jung YH, Cho BH. Assessment of the relationship between the maxillary molars and adjacent structures using cone beam computed tomography. *Imaging Sci Dent* 2012;42:219–224.