

# The value of antiinfective prophylaxis in head and neck surgery

**Language:** English

**Authors:** Bilal Al-Nawas<sup>1</sup>, Knut A. Grötz<sup>1</sup>, Ulrich Wahlmann<sup>1</sup>, Markus Mäurer<sup>2</sup>, Hans-Dieter Kuffner<sup>1</sup>, Wilfried Wagner<sup>1</sup>

<sup>1</sup>Oral and Maxillofacial Surgery

<sup>2</sup>Medical Microbiology and Hygiene, Univ-Hosp., D-55118 Mainz

**Date/Event/Venue:**

21.03.99- 24.03.99

9. European Conference of Clinical Microbiology and Infectious Diseases  
Berlin, Germany

## Objective

In a prospective study in 260 patients who underwent surgery at the head and neck at the university hospital Mainz from July to Oktober 1998 the incidence and severity of post-surgical infections was analysed.

## Material and Methods

Adequate microbiological procedures were performed. The diagnosis of an infection was defined clinically and was compared to the microbiologic findings. Laboratory findings were documented to identify systemic infections (eg. SIRS, Sepsis) from localised wound infections. In nearly all cases an antiinfective prophylaxis with a  $\beta$ -lactam, cephalosporin or clindamycin was administered.

## Results

In only 50% of the patients with abszesses a pathogen was isolated, in the other groups the rate of microbiologically documented infections was above 80%.

Procedures and diagnoses	Total No	Clinical infections	Nosocomial infections
Abszess incisions	50	50 (100%)	0 (0%)
combined intra- and extraoral tumor resections	49	10 (20%)	10 (100%)
dental surgical	68	6 (9%)	1 (17%)
non-contaminated extraoral	15	1 (7%)	1 (100%)
trauma	47	1 (2%)	0 (0%)
cleft lip palate / orthognatic surgery	31	0 (0%)	0 (0%)
Total	260	65 (25%)	12 (5%)

Tabelle 1: "Rate of nosocomial infections after different procedures and diagnoses"

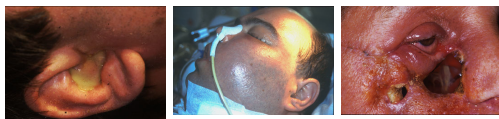

Fig.1 "Severe odontogenic abscess with suppurative efflux from the ear"  
 Fig.2 "Severe odontogenic abscess requiring ventilation"  
 Fig.3 "Midfacial infectious osteoradionecrosis"

**non-nosocomial nosocomial**

Staphylococcus spp.	2	10%	5	13%
Streptococcus spp.	8	42%	3	8%
Enterococcus spp.	1	5%	3	8%
Actinomyces spp.	2	11%	1	3%
Veillonella spp.	1	5%	0	0%
Peptostreptococcus spp.	1	5%	2	5%
Enterobacter spp.	1	5%	1	3%
Klebsiella spp.	1	5%	1	3%
Morganella morganii	0	0%	2	5%
Proteus mirabilis	0	0%	1	3%
Actinobacillus actinomycetemcomitans	0	0%	1	3%
Haemophilus spp.	0	0%	1	3%
Eikenella spp.	0	0%	2	5%
Fusobacterium spp.	1	5%	1	3%
Pseudomonas aeruginosa	0	0%	4	10%
Neisseria spp.	1	5%	1	3%
Acinetobacter spp.	0	0%	2	5%

**Discussion and Conclusions**


For "clean" combined en- and extraoral surgical procedures of the head and neck (Trauma, orthodontic surgery, cleft lip palate) routine prophylaxis should be well considered. Patients with risk factors should receive a broad spectrum antiinfective prophylaxis to prevent nosocomial infections, which in the head and neck area often have dramatic consequences.

This Poster was submitted on 06.09.99 by Dr. Dr. Bilal Al-Nawas.

**Correspondence address:**

Herrn Dr. Dr. Bilal Al-Nawas  
 Univ-Klinik für MKG-Chirurgie  
 Augustusplatz 2  
 D - 55131 Mainz

**Poster Faksimile:**



**The value of antiinfective prophylaxis in head and neck surgery P1113**

B. Al-Nawas<sup>1</sup>, K. A. Grötz<sup>2</sup>, U. W. Wahlmann<sup>1</sup>, M. Mäurer<sup>2</sup>, H. D. Kuffner<sup>1</sup>, W. Wagner<sup>1</sup>

<sup>1</sup>Oral and Maxillofacial Surgery, <sup>2</sup>Medical Microbiology and Hygiene, Univ. Hosp., D-55118 Mainz.

**Objectives**

In a prospective study in 260 patients who underwent surgery at the head and neck at the university hospital Mainz from July to Oktober 1998 the incidence and severity of post-surgical infections was analysed.

**Methods**

Adequate microbiological procedures were performed. The diagnosis of an infection was defined clinically and was compared to the microbiologic findings. Laboratory findings were documented to identify systemic infections (eg. SIRS, Sepsis) from localised wound infections. In nearly all cases an antiinfective prophylaxis with a β-lactam, cephalosporin or clindamycin was administered.


**Results**

In only 50% of the patients with abscesses a pathogen was isolated, in the other groups the rate of microbiologically documented infections was above 80%.


**Rate of nosocomial infections after different procedures and diagnoses**

Procedures and diagnoses	Total No	Clinical infections	Nosocomial infections
Abszess incisions	50	50 (100%)	0 (0%)
combined intra- and extraoral tumor resections	49	10 (20%)	10 (100%)
dental surgical	68	6 (9%)	1 (17%)
non-contaminated extraoral	15	1 (7%)	1 (100%)
trauma	47	1 (2%)	0 (0%)
cleft lip palate / orthognatic surgery	31	0 (0%)	0 (0%)
<b>Total</b>	<b>260</b>	<b>65 (25%)</b>	<b>12 (5%)</b>


Severe odontogenic abscess with suppurative efflux from the ear



Severe odontogenic abscess requiring ventilation



Midfacial infectious osteoradionecrosis



**Microbiologic findings after nosocomial and non-nosocomial infections**

	non-nosocomial		nosocomial	
<i>Staphylococcus spp.</i>	2	10%	5	13%
<i>Streptococcus spp.</i>	8	42%	3	8%
<i>Enterococcus spp.</i>	1	5%	3	8%
<i>Actinomyces spp.</i>	2	11%	1	3%
<i>Veillonella spp.</i>	1	5%	0	0%
<i>Peptostreptococcus spp.</i>	1	5%	2	5%
<i>Enterobacter spp.</i>	1	5%	1	3%
<i>Klebsiella spp.</i>	1	5%	1	3%
<i>Morganella morganii</i>	0	0%	2	5%
<i>Proteus mirabilis</i>	0	0%	1	3%
<i>Actinobacillus actinomycetemcomitans</i>	0	0%	1	3%
<i>Haemophilus spp.</i>	0	0%	1	3%
<i>Eikenella spp.</i>	0	0%	2	5%
<i>Fusobacterium spp.</i>	1	5%	1	3%
<i>Pseudomonas aeruginosa</i>	0	0%	4	10%
<i>Neisseria spp.</i>	1	5%	1	3%
<i>Acinetobacter spp.</i>	0	0%	2	5%

**Conclusions:**

For "clean" combined en- and extraoral surgical procedures of the head and neck (Trauma, orthodontic surgery, cleft lip palate) routine prophylaxis should be well considered.

Patients with risk factors should receive a broad spectrum antiinfective prophylaxis to prevent nosocomial infections, which in the head and neck area often have dramatic consequences.

37th ECCMID March 21-24, 1999 Berlin, contact: bi-nawas@mgklinik.uni-mainz.de