



Sterile gel based on sodium hyaluronate and amino acids: bone healing biological mechanism in patients treated for third stage bisphosphonates-related osteonecrosis of the jaws (BRONJ)

Massimo Corsalini¹, Daniela Di Venere¹, Simonetta Franco², Simona Miccoli², Eugenio Maiorano³, Gianfranco Favia⁴

¹Assistant Professor – Dental School, University of Bari

²Student – Dental School, University of Bari

³Full Professor – Pathological Anatomy, University of Bari

⁴Full Professor – Dental School, University of Bari

Objectives: The aim of this study was to carry out clinical and radiographic outcomes of bone healing using a new medical device, a sterile gel formulation of sodium hyaluronate and amino acids Gly-Leu-Pro-Lys (AMINOGAM®) in treatment of third stage bisphosphonates-related osteonecrosis of the jaws (BRONJ).

Materials and methods: We selected 32 third stage BRONJ patients divided in two groups according to systemic pathology: Neoplastic diseases group that includes 21 patients; Non-neoplastic diseases group of 11 patients.

According to AAOMS guidelines, all patients suspended bisphosphonate therapy three-six months before the surgery and were subjected to antibiotic therapy: three courses of 1g ceftriaxone intramuscular injection/die and 250mg metronidazole oral tablet two times/die for 8 days with 10 days rest between each course.

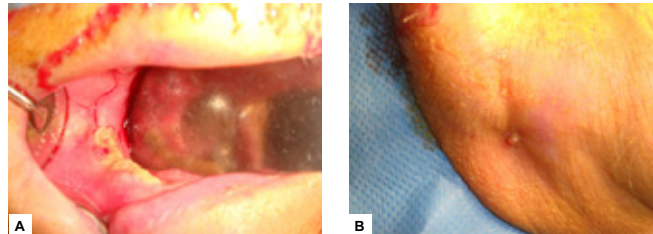
Surgical treatment provides local anesthesia without vasoconstrictor, segmental resection, Piezosurgery osteoplasty, intracavitary intraoperative use of gel to fill up residual bone defect and a first application upon the stitches (sandwich technique).

Our procedure includes using of gel 4 times/die till to complete mucosal healing.

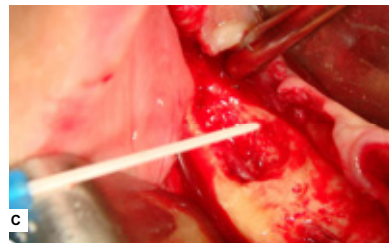Finally a clinical and radiographic follow-up by orthopantomograph and CT examinations at 3, 6, 12 and 24 months was carried out.

Reference

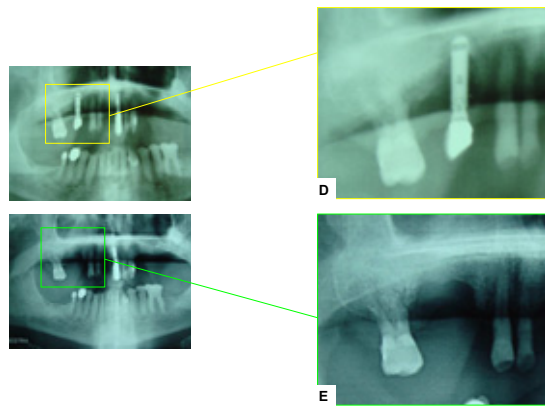
- 1) Enhancement of fibroblast proliferation, collagen biosynthesis and production of growth factors as a result of combining sodium hyaluronate and aminoacids. Mariggio MA, Cassano A, Vinella A, Vincenti A, Fumarulo R, Lo Muzio L, Maiorano E, Ribatti D, Favia G. *Int J Immunopathol Pharmacol.* 2009 Apr-Jun;22(2):485-92.
- 2) Accelerated wound healing of oral soft tissues and angiogenic effect induced by a pool of aminoacids combined to sodium hyaluronate (AMINOGAM). Favia G, Mariggio MA, Maiorano F, Cassano A, Capodiferro S, Ribatti D. *J Biol Regul Homeost Agents.* 2008 Apr-Jun;22(2):109-16.
- 3) Stimulation of osteoinduction in bone wound healing by high-molecular hyaluronic acid. Sasaki T, Watanabe C. *Bone.* 1995 Jan;16(1):9-15.
- 4) Mechanism involved in enhancement of osteoblast differentiation by hyaluronic acid. Kawano M, Ariyoshi W, Iwanaga K, Okinaga T, Haba M, Yoshikake I, Tomimaga K, Mishiura T. *Biochem Biophys Res Commun.* 2011 Feb 25;405(4):575-80. Epub 2011 Jan 23.
- 5) Hypoxia and amino acid supplementation synergistically promote the osteogenesis of human mesenchymal stem cells on silk protein scaffolds. Sengupta S, Park SH, Patel A, Carn J, Lee K, Kaplan DL. *Tissue Eng Part A.* 2010 Dec;16(12):3623-34. Epub 2010 Sep 1.



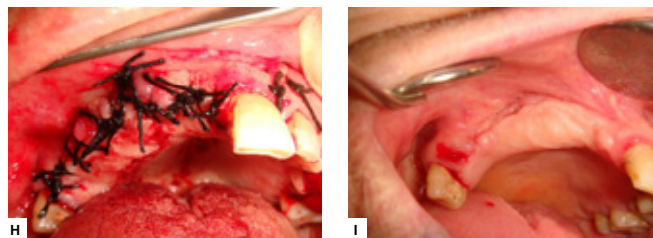
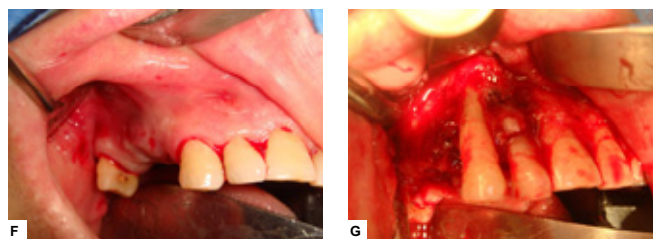
III stage BRONJ affecting a 82-year old woman, treated with zoledronate for breast cancer: bone exposure (A) and extra-oral fistula (B)



Intracavitary intraoperative use of sterile gel based on sodium hyaluronate and aminoacids (Gly, Lys, Leu, Pro) (C)



III stage BRONJ affecting 76-year old man, treated with zoledronate for prostate cancer: peri-implantar osteonecrosis (D) and 6-months radiographic follow-up shows complete bone healing (E)



III stage BRONJ affecting 75-year old man, treated with zoledronate for multiple mieloma: pre-surgical (F), intra-operative (G), post-surgical view (H) and 20-days clinical follow-up shows complete mucosal healing (I)

Results: Clinical outcomes showed complete hard and soft tissue healing in all post-surgical sites, with a difference between two groups: neoplastic diseases group needed a longer soft wound healing time of 5 days compared to non-neoplastic diseases group.

Radiographic outcomes show radiolucent areas decreasing due to gel direct osteoinductive effect with a faster osteoregeneration time in non-neoplastic diseases group: 15% difference between ossification level at 3 and 6 months.

Gel preparation of sodium hyaluronate and amino acids enhances angiogenesis, fibroblast and osteoblast proliferation, collagen biosynthesis and production of growth factors as evidenced by MTT test and alkaline phosphatase histochemical staining. In vivo and in vitro studies have suggested that hyaluronic acid plays important roles in bone wound healing by enhancement of osteoblast differentiation through the down-regulation of BMP-2 antagonists. Lysine and proline regulate collagen matrix synthesis during osteogenesis.

Conclusions: Sodium hyaluronate and amino acids gel formulation decreases postoperative pain, swelling and infective complications after surgery by surgical wound mechanical protection. This new medical device is biocompatible, extremely cheap, safe and useful in all surgical procedure in order to obtain a faster healing of oral hard and soft tissues, specially in BRONJ that are often prone to difficult, slow and complicate recovery.



*AMINOGAM®