



FIXED REHABILITATION OF TWO NON-SYMMETRICAL ADJACENT TEETH WITH ONE IMPLANT

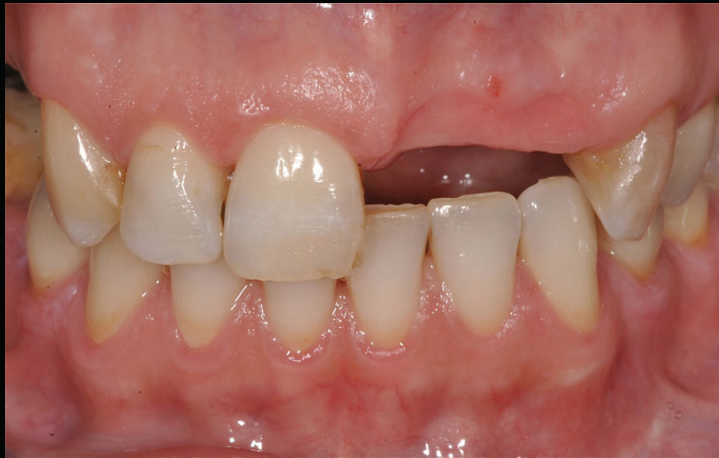

Fig.1

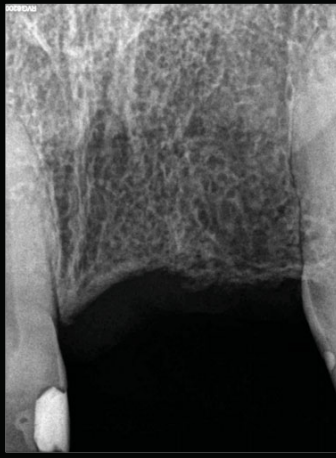

Fig.2

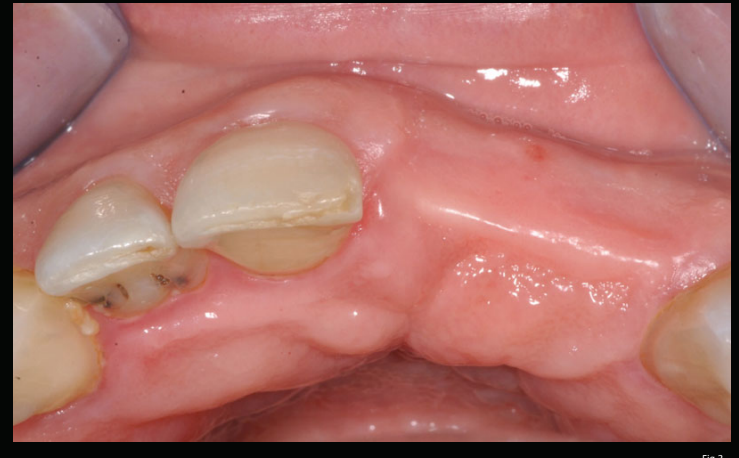

Fig.3

CASE REPORT: A 46-year-old female patient went to our clinic with the absence of some teeth (Figs. 1-3), showing interest in a fixed implant rehabilitation of the left central and lateral incisors. We decided to place one implant with a platform-switched morse-taper connection (IDCam 4,2 x 12 mm, IDI[®]) in the central incisor position with a screw-retained cantilevered restoration (Figs. 4-6). Flap design included papillae-sparing incisions¹ (Fig. 4) Contour augmentation with guided bone regeneration was performed simultaneously to implant placement to correct the fenestration and for aesthetic purposes^{2,3} (Figs. 7, 8). After 3 months of osseointegration, second surgical stage was performed and provisionals were fabricated (Figs. 9, 10).

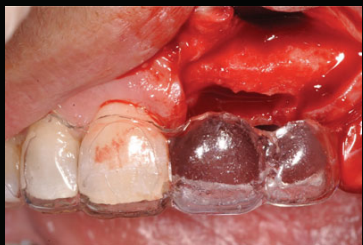

Fig.4

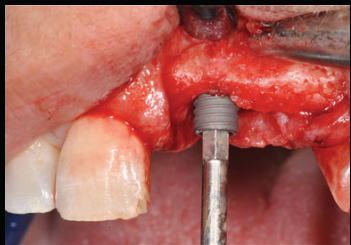


Fig.5

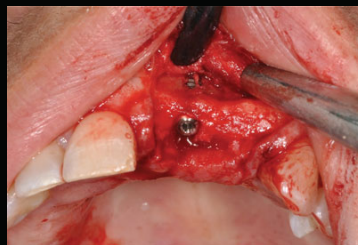


Fig.6

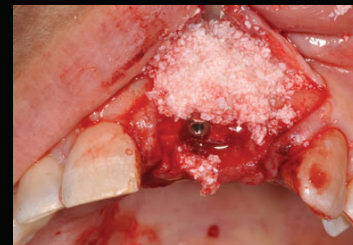


Fig.7

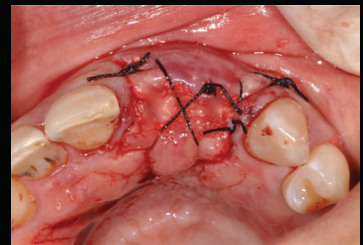


Fig.8

Then there was a soft tissue modeling period through the necessary changes to temporary crowns (Figs. 14-16). One month after the placement of the provisionals, we noticed that there was a groove on the papilla because of the crestal incision for the implant placement (Fig. 11). Our option to solve that was to perform a plasty of the papilla with a diamond bur. The purpose was to deepithelize the area to promote new healing of the soft tissue (Figs. 12, 13, 16). After 6 months, final impression was made and a screw-retained metal-ceramic restoration was fabricated (Figs. 17, 18).

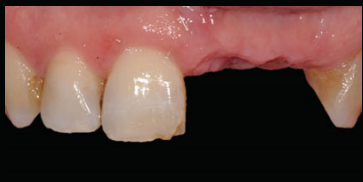

Fig.9

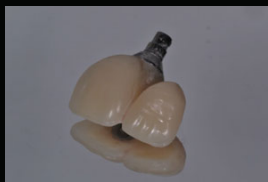

Fig.10

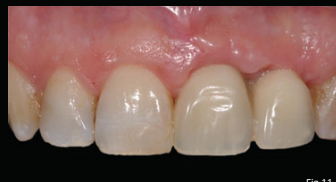

Fig.11

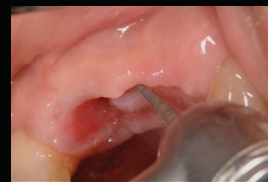

Fig.12

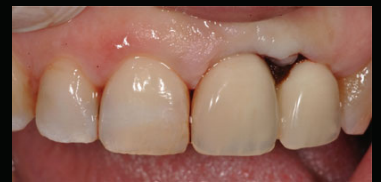

Fig.13

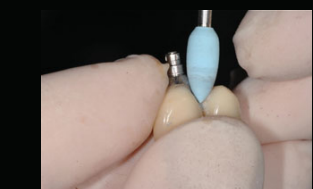

Fig.14

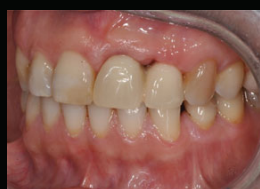

Fig.15

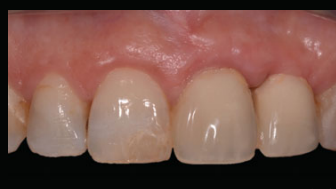

Fig.16

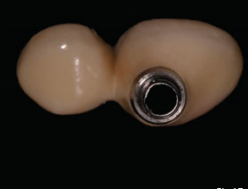

Fig.17

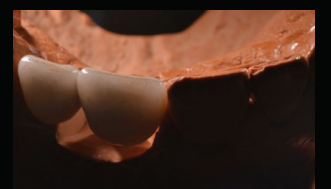

Fig.18

DISCUSSION: Rehabilitation of two adjacent teeth with implants in the aesthetic zone is always a challenge⁴, particularly in the same quadrant due to its asymmetry. According to several authors, the placement of only one implant with two crowns can be advantageous, since it is likely to have more soft tissue height between one implant and one pontic than between two implants⁵, where only 3.4 mm of tissue height is expectable on average⁴. The type of connection as well as the platform-switched abutment used in this case may also be beneficial since it may preserve more bone at the crestal level and thus contribute to better support of the soft tissue^{6,7}.

CONCLUSION: The described procedure was successful in terms of function and esthetics, returning the patient's confidence in her smile (Figs. 19, 21).

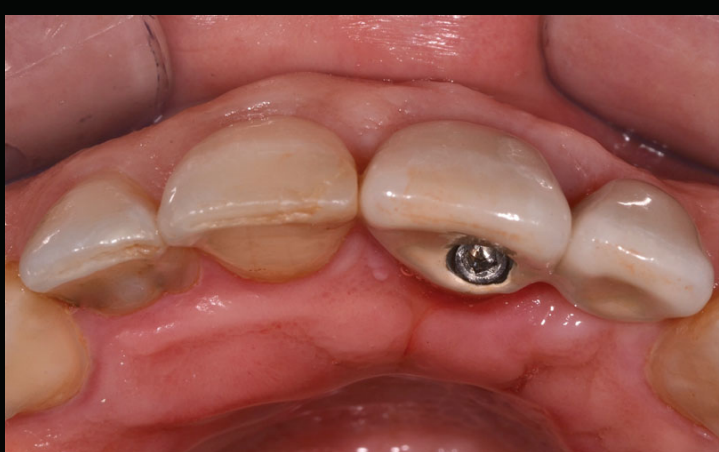

Fig.19

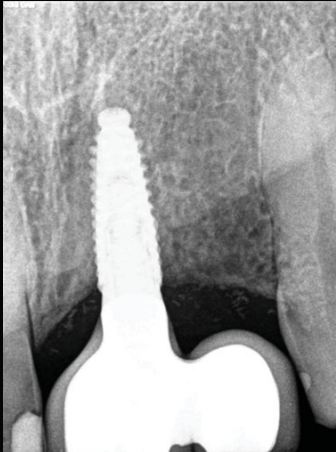


Fig.20

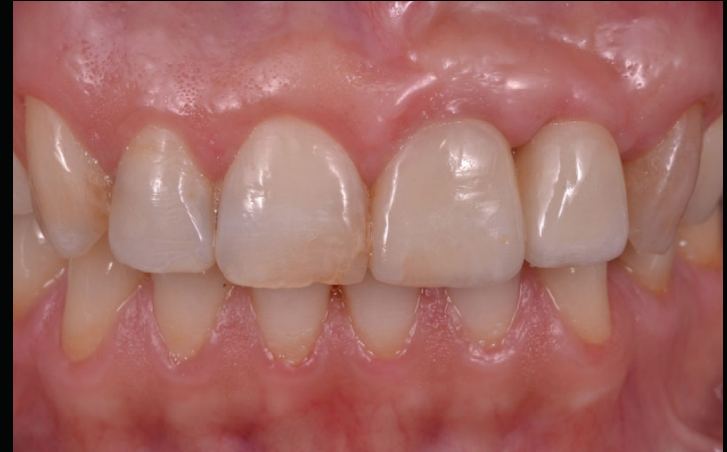

Fig.21

REFERENCES

1. Greenstein G, Tarnow D. Using papillae-sparing incisions in the esthetic zone to restore form and function. *Compend Contin Educ Dent* 2014 May;35(5):315-22.
2. Chigazato M, Zamboni M. Clinical outcomes of GBR procedures to correct peri-implant dehiscences and fenestrations: a systematic review. *Clin Oral Implants Res*. 2009 Sep;20 Suppl 4:113-23. doi: 10.1111/j.1600-0501.2009.01781.x.
3. Jensen SS, Rossbø DD, Gruber R, Buser D. Long-term stability of contour augmentation in the esthetic zone: histologic and histomorphometric evaluation of 12 human biopsies 14 to 80 months after augmentation. *J Periodontol* 2014 Nov;85(11):1549-56. doi:10.1902/jip.2014.140182. Eub 2014 Jul 10.
4. Tarnow D, Eilan N, Fletcher P, Froum S, Magner A, Cho SC, Salama M, Salama H, Garber DA. Vertical distance from the crest of bone to the height of the interproximal papilla between adjacent implants. *J Periodontol*. 2003 Dec;74(12):1785-8.
5. Salama H, Salama MA, Garber D, Adar P. The interproximal height of bone: A guideline to predictable aesthetic strategies and soft tissue contours in anterior tooth replacement. *Pract Periodontics Aesthet Dent* 1998;10:1133-1141.
6. Jishi MA, Ishihara HM, Ishii JH. Platform switching for marginal bone preservation around dental implants: a systematic review and meta-analysis. *J Periodontol*. 2010 Oct;81(10):1350-6. doi: 10.1002/jip.2028. Epub 2010 Jun 22.
7. Vela X, Méndez V, Rodríguez X, Segalá M, Tarnow DP. Crestal bone changes on platform-switched implants and adjacent teeth when the tooth-implant distance is less than 1.5 mm. *Int J Periodontics Restorative Dent* 2012 Apr;32(2):149-55.