



A case report.

#149

TASKIN TUNA

Department of Prosthodontics and Biomaterials, Medical Faculty, RWTH Aachen University, GERMANY

INTRODUCTION AND AIM

The challenge of immediate implant placement in premolar or molar sites is to achieve primary stability at the presence of interradicular bone septa. This case report illustrates a step-by-step approach for the immediate placement of an implant in a premolar area in the upper jaw with pre-extractive implant bed preparation.

MATERIAL AND METHODS

A patient (76y) with a fractured and hopeless upper right first premolar visited our clinic. All neighboring teeth were provided with fixed restorations. After clinical and radiographic analysis, a single crown implant restoration via immediate implant placement was planned (Fig. 1a-d).

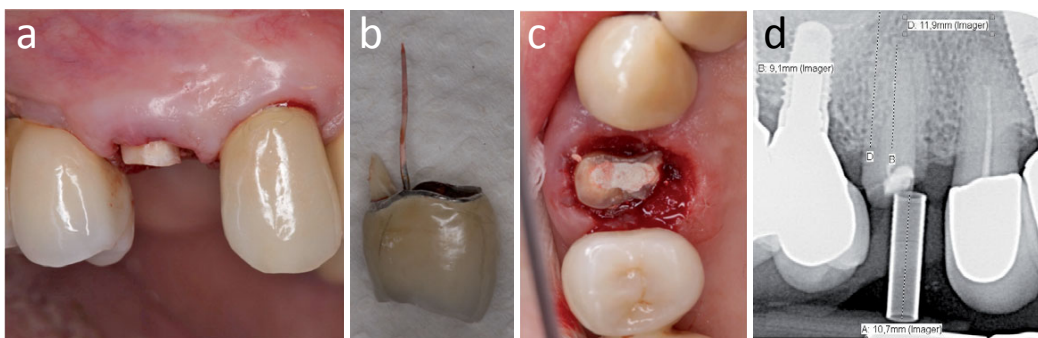


Fig. 1: a) Fractured tooth at gingival level; b) Fractured crown with remaining tooth and guttapercha point; c) Occlusal view of remaining root in situ; root canal openings rinsed and sealed with temporary filling; d) Two-dimensional X-ray analysis for implant placement.

All drilling steps were performed directly through the remaining root for achieving an optimal three-dimensional orientation of the implant axis. After finishing the implant bed preparation, the remaining root was carefully extracted in two parts. The socket walls were well conserved. After sounding of the height of the limbus alveolaris, an implant (3.8x11mm) was placed with sufficient primary stability (Fig. 2a-i).

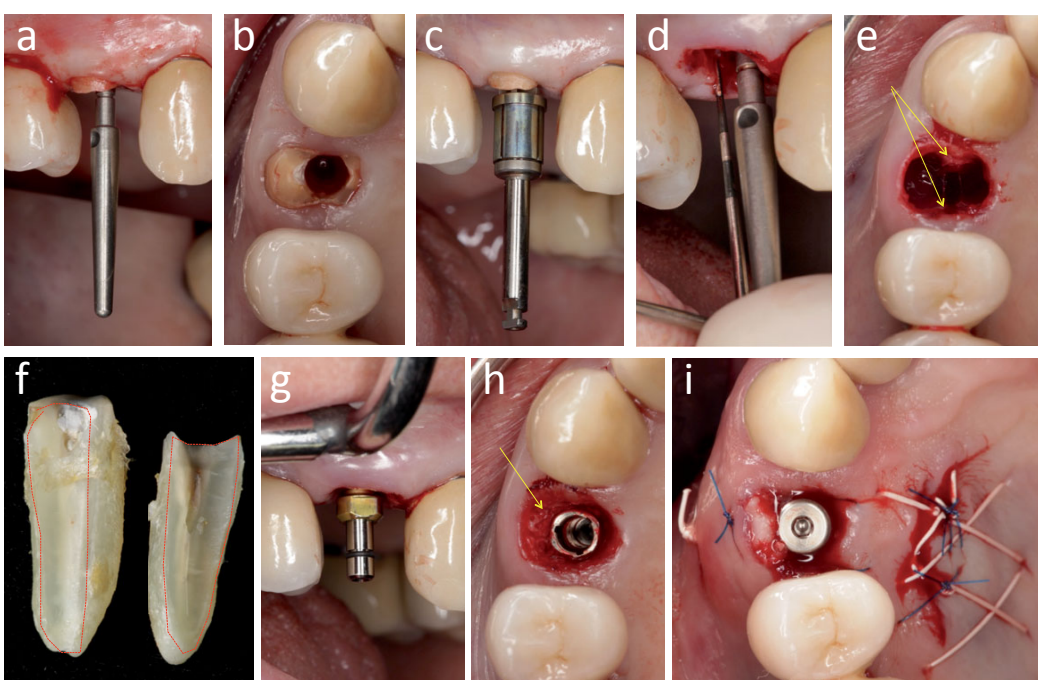


Fig. 2: a) Checking the axis with an indicator after pilot drilling; b) Occlusal view after the last drilling step (3,8x11mm); c) Checking the axis of last drill; d) Measuring the height of the socket walls; e) A maximum preservation of the socket walls can be seen (arrows); f) The two extracted root parts (red lines highlight the drilling access hole); g) Implant in situ; h) Filling the gap with bovine bone chips (arrow); i) A connective tissue graft transplanted buccally via the envelope technique to stabilize gingival conditions.

After a transgingival healing period of 4 months, a CAD/CAM implant restoration was fabricated (Fig 3a-g).

For this, a scan abutment was fixed on the implant and scanned by an optical scanner. Then, a single crown restoration was virtually designed and manufactured in a milling machine.

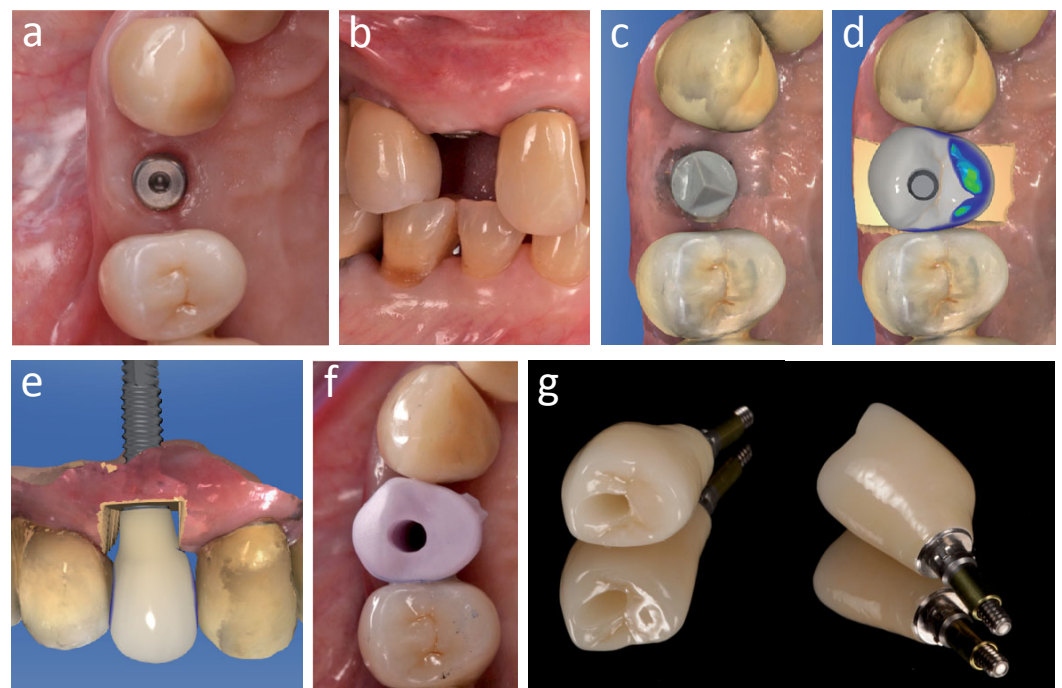


Fig. 3: a&b) Satisfying gingival conditions after 4 months of transgingival healing; c) Intraoral impression taken using a scan abutment and an optical scanner; d&e) Computer-aided designing (CAD) of a screwed implant restoration; f) Try-in of the pre-crystallized lithium disilicate restoration; g) Two views of the finished implant restoration consisting of a Titanium base and the ceramic crown.

RESULTS

The CAD/CAM implant restoration was screwed to the implant. The screw access hole was sealed by white guttapercha followed by a tooth-colored composite material (Fig 4a-d).

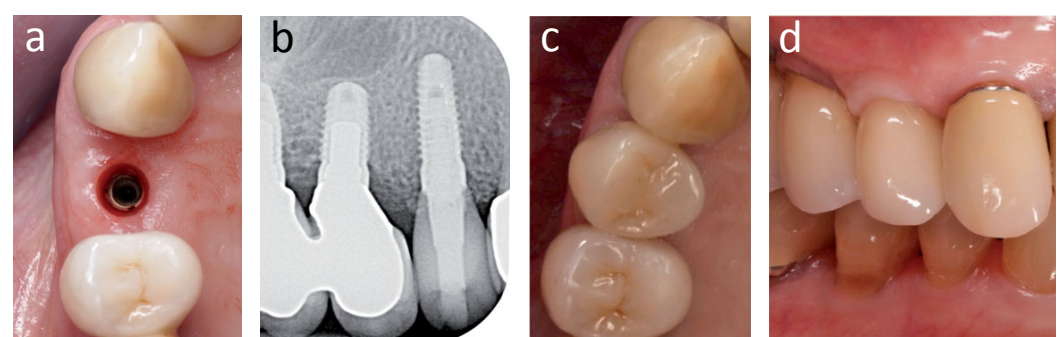


Fig. 4: a) Occlusal view of the implant in situ without healing cap; b) X-ray after definite incorporation of the implant restoration; c) Occlusal view of the restoration after closure of the screw access hole with composite material; d) Lateral view of the restoration and gingival conditions after 12 months.

During the three months to one-year follow-up stable gingival conditions could be observed.

CONCLUSION

From a clinical point of view, the concept of pre-extractive implant bed preparation allowed safe and precise positioning and angulation of an immediately placed implant. This is due to minimization of possible deflection of the osteotomy drills from the ridge of the bone septa. Therefore, the probability to achieve sufficient primary stability seems to be higher than in case of post-extraction implant bed preparation.