

Clara Muscholl, Diana Wolff

# The two-step direct composite restoration (R2 restoration) – a current review

**Introduction:** The treatment of subgingival cavities with direct composite restorations is a challenge in everyday dental practice. Many difficulties must be overcome in the course of treatment, including bleeding and tissue management, a flawless adhesive technique, step-free and margin-free application of the restorative material as well as anatomically correct crown shaping and contact area design. Each individual treatment step in the course of the restorative process is crucial for the long-term clinical success of the restoration.

**Treatment methods:** The R2 restorations divide this complex restorative process into two steps. In the first restorative step, only the deep subgingival portion of the cavity is restored, and the cavity floor is elevated to a paragingival or slightly supragingival level. In the second restorative step, the tooth's crown is reconstructed, and the contact area facing the neighboring tooth is designed. The two restorative steps require the use of various tools and techniques.

**Result:** The methodical, step-by-step approach makes the entire treatment process more manageable and easier to perform.

**Conclusion:** Teeth with extensive tooth substance loss as a result of deep subgingival cavities can be restored safely, predictably and with a good prognosis by means of the R2 restorations. Structured follow-up care which focuses on sufficient cleaning of the proximal area is essential for long-term success.

**Keywords:** adhesives; contamination; MMPs; resin composites; technique sensitivity

## 1. Introduction

The clinical application of the two-step direct composite restoration (R2 restoration) was first presented in 2014 [12, 14, 32], and since then, it has been critically discussed and further developed. The R2 restoration differs from the proximal box elevation (PBE) [11, 18, 29], cervical margin relocation (CMR) or deep margin elevation (DME) [6], margin elevation technique [36] or sandwich technique [5, 8], in that composite is applied directly throughout the procedure, without the use of laboratory fabricated restorations. It is beyond question that the treatment of subgingival cavities must be managed and solved adequately in daily dental practice. In this regard, due to the further development of methods and materials as well as the increasing expertise in this field, patient demands can be addressed with increasingly more tooth preservation solutions. However, the requirements of adhesive systems and dental materials with respect to materials science and processing technology are in conflict with the requirements of the surrounding soft tissues when restoring critical subgingival areas [28]; an example of this is the need for irritation-free restoration margins and biocompatibility of the materials. The R2 restoration is a comprehensive treatment approach which helps overcome many of the difficulties encountered during restorative treatment. In this manner, the challenging task of reconstructing extensive and deep subgingival defects is broken down into manageable steps.

### 1.1 R2 restoration and the biological width

Special attention must be paid to the so-called “biological width”, which represents the minimum distance between the marginal restoration edge and the bone, when restoring deep subgingival defects. As a rule, it is important not to fall below this distance in order to avoid irritation or inflammation of the periodontium. The concept of the biological width is based on the observations of Gargiulo et al. in 1961, who found an average gingival sulcus dimension of 0.69 mm, epithelial attachment of

0.97 mm, and supraalveolar-fiber apparatus of 1.07 mm [15]. These findings are considered to be the basis for the assumption that there is a physiological distance of 3 mm between the limbus alveolaris and the cemento-enamel junction in healthy teeth [26]. However, the dimension of the biological width may differ depending on the position of the tooth as well as the tooth surface and the biotype of the gingiva and alveolar bone [28, 33]. Moreover, the dimensions of the dentogingival complex do not appear to be constant [30]. Nevertheless, a distance of 3 mm between the restoration margin and the limbus alveolaris is still a general requirement in order to prevent inflammatory reactions of the periodontium [16, 19, 24]. Surgical crown lengthening or orthodontic extrusion of teeth is recommended if the biological width falls short of 3 mm during the course of restorative treatment [3, 9, 25]. Deep subgingival restorations inevitably affect the area of the biological width. After the introduction of the R2 restoration and its classification in the context of biological width [14], there have been and continue to be controversial views on this subject. Clinically, it has been shown that periodontal conditions free of inflammation can be observed after treatment with composite restorations which violate the biologic width [13]. In this regard, it can be assumed that composite restoration margins which are smooth and free of excess material in the subgingival area can be tolerated by the periodontium without causing inflammation. The exact relationship has not been fully elucidated until now and are subject to further scientific investigation.

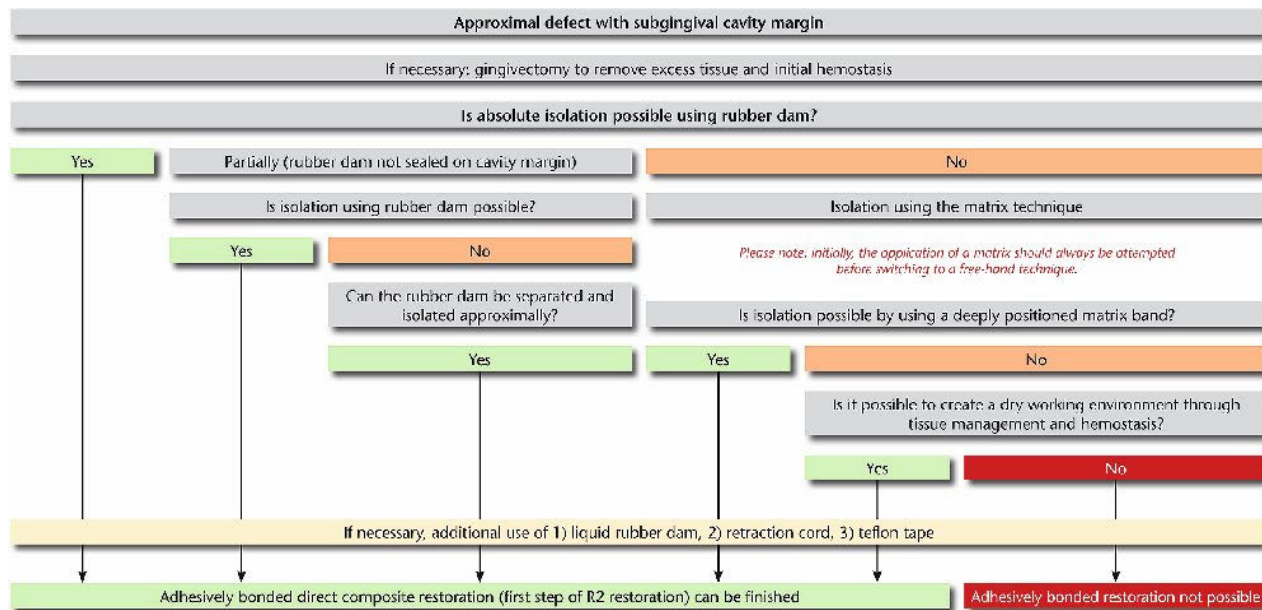
### 1.2 Classification of the R2 restoration based on current literature

Most of the recently published studies on deep restorations, which cross the cemento-enamel junction, are in vitro studies that compare the marginal adaptation between indirect restorations, with and without box elevation [11, 23, 29, 31, 36]. The majority of these studies report no differences in marginal quality between cemented indirect restorations,

which extend subgingivally, and direct restorations with a previous box elevation. Moreover, it has been demonstrated that composite material (flowable or viscous) can be applied in multiple layers [11, 29] or in one layer [36] for box elevation.

To date, only a few clinical studies are available. In addition to a systematic review from 2015 [18] and a literature review from 2018 [17], three other clinical studies can be found. In 2018, Ferrari et al. published their results from a 12-month, controlled study which investigated the impact of CMR on periodontal health [10]. The study compared 35 subjects who had received either a partial ceramic crown with CMR (test) or without CMR (control). The restoration margins of the CMR or the partial ceramic crown were placed within the range of the biological width. At the beginning, the subjects received a single oral hygiene instruction session and professional tooth cleaning. Clinical inflammatory parameters (gingival bleeding index, bleeding on probing, and probing depths) were measured at the start and after 12 months. The study did not provide information on the allocation of the subjects to the respective groups; rather, it only reported the initial gingival and plaque scores as well as bleeding on probing in all subjects at the beginning. After 12 months, the test group (partial ceramic crown with CMR) showed significantly more bleeding on probing ( $p = 0.010$ ), whereas the gingival and plaque scores tended to be slightly higher in the test group than in the control group, but these values were not significantly different. The authors conclude that the procedure is rather technique-sensitive.

In a second clinical study which investigated the response of periodontal tissue to subgingival composite restorations, Bertoldi et al. included 29 subjects with subgingival carious defects who underwent restorative root canal treatment and were scheduled for subsequent crown restoration. CMRs were performed on the teeth, whereby only cases that were at least 3 mm from the alveolar bone were included, and thus, not within the range of the biological width. Over a 3-month observation period



**Figure 1** Flow chart illustrating treatment planning for approximal defects with subgingival margins.

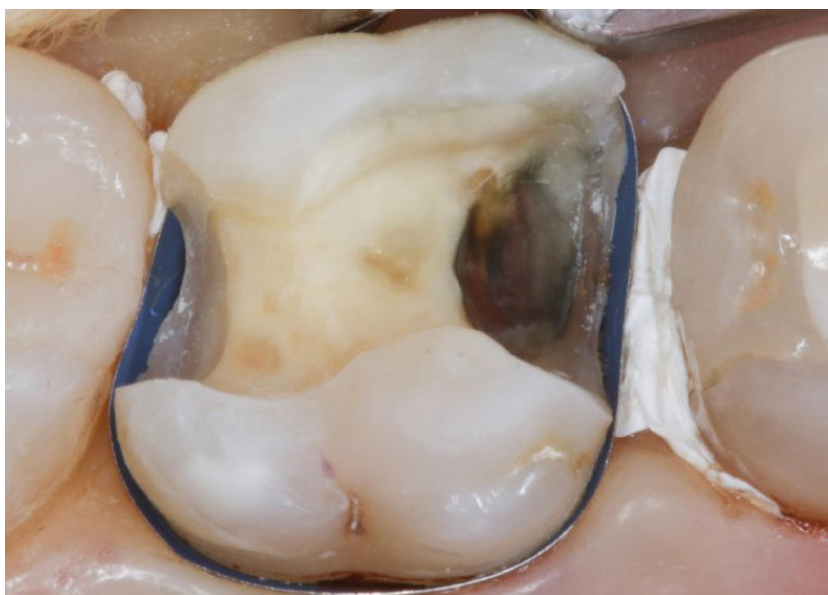
which included a rigorous supportive periodontal therapy (SPT) program, a significant decrease in plaque index, bleeding on probing and probing depths was recorded. Histological specimens which were collected after 3 months showed no indication of inflammatory processes in the CMR area in comparison to control sites on the healthy side of the teeth [1]. The authors concluded that subgingival composite restorations are com-

patible with gingival health in relation to CMR, given that the biological width is not violated and rigorous SPT is implemented.

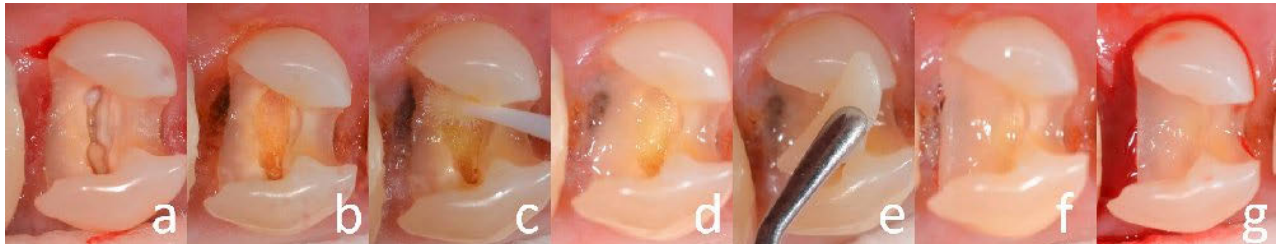
The two studies differ significantly in terms of the frequency and implementation of the SPT program. In the study by Ferrari et al., oral hygiene education and professional tooth cleaning were performed only once at the beginning; subsequently, a very significant increase in plaque and gin-

gival indices and bleeding on probing was observed in both groups, with more pronounced effects seen in the test group with CMR. This indicates that subgingivally positioned composite restorations require adequate cleaning, which must be addressed as part of oral hygiene education preoperatively and as carefully planned follow-up care postoperatively.

Another clinical study investigated 197 partial indirect composite restorations with DME in 120 subjects. The mean follow-up time was 57.7 months. In the cohort, 8 failures were observed, 5 of which were due to secondary caries. The overall survival rate of the restorations was 95.5% (standard deviation 2.9%) after 10 years or longer. Periodontal parameters were not recorded in the study, but quality criteria (USPHS criteria) at the baseline examination and at the last recall were reported. In this case, there was a deterioration in all categories. The authors of the study considered this to be a “normal phenomenon” of aging, as they saw more pronounced manifestations in the older restorations than in the younger ones. In this context, they pointed out that periodontal health (as a criterion of the USPHS analysis) could have deteriorated as a consequence of the biological width violation. However, this was notice-



**Figure 2** Deep subgingival cavity at tooth 26. A matrix band is applied (Slick Bands Margin Elevation Matrix Bands, Garrison Dental Solutions) and teflon tape is used for mesial and distobuccal isolation.



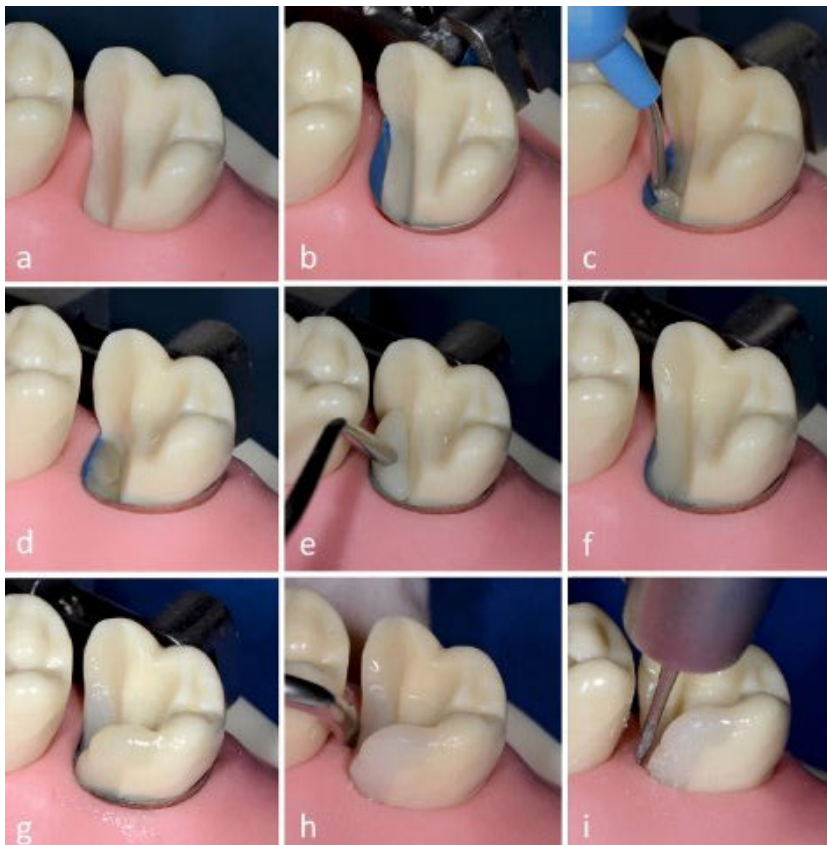
**Figure 3** First step of the R2 restoration using the free-hand technique.

(a) Initial situation of distal subgingival cavity at tooth 14 and accompanying root canal treatment that was performed in parallel; (b) after successful hemostasis with ferric sulfate solution, the working field is dry; (c) after phosphoric acid etching, rinsing and drying, the adhesive system is applied and air drying and light curing is performed; (d) application of a small amount of flowable composite material onto the distal cavity floor, WITHOUT light curing; (e) application of viscous restorative composite onto the flowable material; (f) modeling of both the flowable and viscous composite material in parallel and removal of excess material; (g) after light curing, careful approximal finishing is performed, during which renewed bleeding is induced.

ably not the case. They concluded that indirect restorations with DME showed good survival rates in the observation period of up to 12 years [2].

Unpublished data from the working group of the authors of the present paper show promising results on the clinical quality of R2 restorations

so far. Compared to control teeth, the plaque index, gingival bleeding index, and bleeding on probing were not significantly increased after an average of 2.7 years (min. 0.0 to max. 9.3 years) at 63 deep subgingival R2 restorations, which were located in range of the biological width. In contrast to the previously mentioned studies, subjects with previous periodontitis were not excluded from this study. The periodontium in this patient group showed no clinical signs of inflammatory processes at the R2 restorations. The subjects received supportive periodontal follow-up care. The evaluation also revealed that the regular use of interdental brushes during home-based oral hygiene leads to a significantly reduced tendency of the gingiva to bleed.



**Figure 4** Step-by-step procedure of the first phase of the R2 restoration at model tooth 27.

(a) Initial situation of a cavity extending 2–3 mm subgingivally; (b) the matrix band is applied subgingivally (Slick Bands Margin Elevation Matrix Bands, Garrison Dental Solutions); (c) introduction of flowable composite after conditioning of the cavity with phosphoric acid and application of the adhesive system; (d) flowable composite is applied WITHOUT light curing; (e) restorative composite is placed on the uncured flowable material; (f) approximal step is elevated using composite; (g) free-hand build-up of the missing mesiopalatal enamel wall with restorative composite; (h) smoothing of the restoration margins with single-sided diamond-coated sonic tips (Sonicflex Stripping, Shaping No. 73, 74, 75, 76, KaVo); (i) removal of excess material using a flame-shaped diamond bur (No. 8889415 010, Komet).

## 2. Treatment with R2 restorations

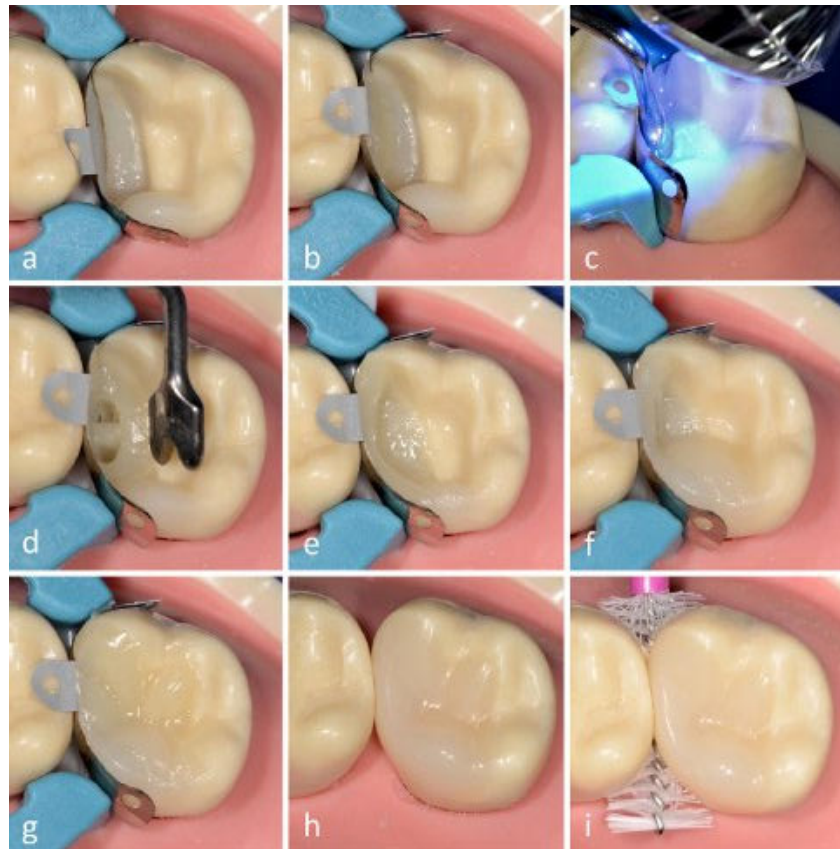
### 2.1 Treatment planning

Decision-making and treatment planning is complex when dealing with extensive subgingival defects. The course of treatment can be assessed in advance based on the clinical findings and the X-ray [22, 34]. However, due to the complex clinical situations that are encountered during treatment, adjustments to the treatment strategy or the techniques and materials are also to be expected. In this respect, it is wise to outline a “best-case” and a “worst-case” treatment scenario for the patient. The former is based on the assessment of whether, depending on the remaining tooth substance, a rubber dam, partial iso-

lation, etc. can be applied in order to facilitate treatment with an adhesive restoration. The “worst-case” scenario should reflect the fact that the treatment attempt may fail, and thus may require additional measures such as surgical crown lengthening, orthodontic extrusion or extraction. An emphasis should be placed on explaining to patients that the treatment procedure is multifaceted and that the outcome depends on numerous factors which cannot (always) be fully assessed in advance.

## 2.2 Hemostasis and tissue management

The flow chart presented for approximal subgingival defects can be used to plan the procedure and prepare for the treatment (Fig. 1). Initially, the defect should be completely exposed. This includes the cleaning of the tooth and neighboring teeth, the removal of any disturbing soft tissue by means of gingivectomy and, if necessary, performing initial hemostasis. Inflamed tissue is frequently found in the area bordering the cavity. This requires hemostasis with effective hemostatic agents; preparations based on aluminum chloride, ferric sulfate or ferric subsulfate are suitable for this purpose. It is extremely important that the preparations are actively embedded into the surface of the soft tissue. In order to adequately stop bleeding and keep the blood vessels constricted during the adhesive procedure, they must be well sealed. Hemostasis is continued by actively rubbing or massaging gel or solution into the bleeding gingival surface. At the same time, excess is aspirated. If no more brownish precipitate/coagulum forms after a certain time, it can be assumed that the bleeding has stopped. The time required for this may vary (1–3 min.). The area is then rinsed vigorously with air-water spray. This is also the test to determine if hemostasis has been successful. If bleeding occurs again, hemostasis must be repeated. Common active ingredients found in commercial hemostatic agents include aluminum chloride and ferric sulfate. In addition to the hemostatic effect on soft tissues, these agents can also alter the tooth hard substance surface that comes in con-



**Figure 5** Step-by-step procedure of the second phase of the R2 restoration at model tooth 27.

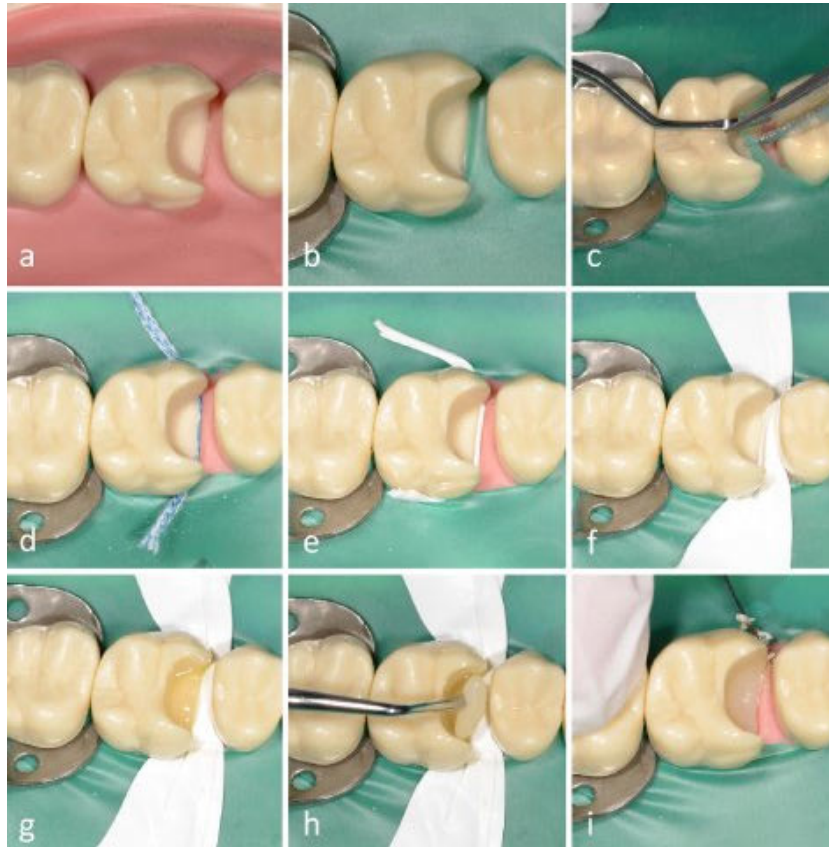
(a) Application of an anatomically pre-contoured matrix band with a wedge and a separation ring (Palodent V3 partial matrix system, Dentsply Sirona); (b) after phosphoric acid etching and application of an adhesive system, flowable composite is applied WITHOUT light curing, followed by restorative composite; (c) pressing of the matrix band onto the adjacent tooth with an approximal contact former (Easy Contact Point hand instruments for molars, Zepf Dental) and light curing; (d) the polymerized composite adapts the matrix band to the adjacent tooth via a bar which is formed at the level of the contact point; (e) build-up of the approximal enamel wall with restorative composite; (f) finishing of the restoration with restorative composite using the oblique layering technique; (g) modeling of the fissure morphology; (h) finished and polished composite restoration; (i) fitting of an interdental brush to ensure hygiene compliance.

tact with them. Consequently, the residues, precipitates and surface changes can have a marked effect on subsequent adhesive bonding. Reference may be made at this point to a recent review on this subject [4]. Literature on this topic is inconclusive, as the extent to which adhesive forces are affected varies depending on the type of adhesive used and active substance. However, in order to ensure safe adhesion after the application of hemostatic agents, the use of an etch-and-rinse adhesive system is recommended according to current literature. This is because a cleaning effect on dentin and enamel is achieved by means of phosphoric acid etching,

thus reducing the effect of the hemostatic agent on the adhesive forces and/or marginal qualities.

## 2.3 Rubber dam isolation

Absolute isolation using a rubber dam should be attempted. This can be achieved to some extent with the aid of subgingival rubber dam clamps (e.g. RDCM14 #14 Molar, RDCM1A #1A Premolar, HuFriedy, Tuttlingen, Germany) or special rubber dam clamps (e.g. new Haller clamps, Kentzler-Kaschner Dental GmbH, Ellwangen, Germany), thereby ensuring the possibility of an adhesive restoration. If the rubber dam cannot be adapted or sealed at a deep subgingi-



**Figure 6** Step-by-step procedure of the first phase of the R2 restoration at model tooth 16.

(a) Initial situation of a cavity extending 2–3 mm subgingivally; (b) an attempt to place a rubber dam reveals inadequate mesial isolation; (c) cutting of the rubber dam's septum using scissors; (d)–(f) various options for secondary isolation of the rubber dam at the mesial margin: insertion of a retraction cord, a rolled-up piece of teflon tape or application of teflon tape over the entire surface to retract the papilla, the tape is also pressed into the sulcus and adapted; (g) after phosphoric acid etching and application of an adhesive system, flowable composite is introduced WITHOUT subsequent light curing; (h) application of restorative composite onto the still soft remaining flowable material and simultaneous modeling of both materials in the area of the step, excess material is removed carefully using a Heidemann spatula that is guided vertically along the tooth neck, followed by light curing; (i) removal of excess material with a scalpel.

val site, it can be cut at the respective site (Fig. 1 and 6c). The rubber dam is then sealed with additional aids such as liquid rubber dam, teflon tape (Figs. 6e and 6f) or retraction cord (Fig. 6d). If it is not possible to apply a rubber dam, the cavity can be isolated by applying a matrix band. Matrix bands which are especially designed for elevating the approximal box or step (e.g. Slick Bands™ Margin Elevation Matrix Bands, Garrison Dental Solutions, Übach-Palenberg, Germany) have proven to be very useful for this purpose (Fig. 4b). The band is applied tightly around the cervical area of the tooth and pressed down along the cavity margin. A Heidemann spatula

can be inserted vertically in the sulcus on the inside of the band as a guiding instrument. Due to its special shape, the band descends apically around the neck of the tooth and in this way manages to seal even very deep defects. The coronal edge of the matrix band often lies at the gingival level or slightly above it. The base of the box should be elevated in such a manner so as to serve as a prop for the separation wedge during the subsequent application of a partial matrix band in the second step of the R2 restoration. If leakage appears at the matrix band, for example due to difficult root morphologies with furcations, a seal can be achieved using a piece of teflon

tape (Fig. 2). The tape is plugged into the periodontal gap from the outside of the matrix, either using a Heidemann spatula or a retraction cord applicator, so as to act as a prop that presses the matrix band against the tooth. One of the advantages of teflon tape, among other things, is its ability to be removed without leaving any residue after the box has been restored [21]. If the application of a matrix band is not possible, the free-hand technique must be considered [14, 32] (Fig. 6). For this objective, thorough hemostasis must be repeated, as described above. In addition, the insertion of a retraction cord should be considered in order to absorb ascending sulcus fluid. However, the retraction cord should be positioned in such a way that it is not polymerized during the adhesive procedure and composite application (Fig. 6d). Alternatively, teflon tape (Figs. 6e and 6f) or liquid rubber dam can be used. During the adhesive process and composite application, a micro suction device should be readily available (e.g. Surgitip-endo, Roeko, Coltène, Langenau, Germany). It can be held in a suitable position in case of minor bleeding and to maintain a dry working field during the adhesive and composite application step.

Figures 4 to 7 show two methods for reconstructing extensive and deep subgingival defects. In the first, the first step of the R2 restorative procedure is prepared with the help of a subgingival matrix band. In the second, the free-hand technique is used to elevate the approximal box base.

#### 2.4 First step of the R2 restoration

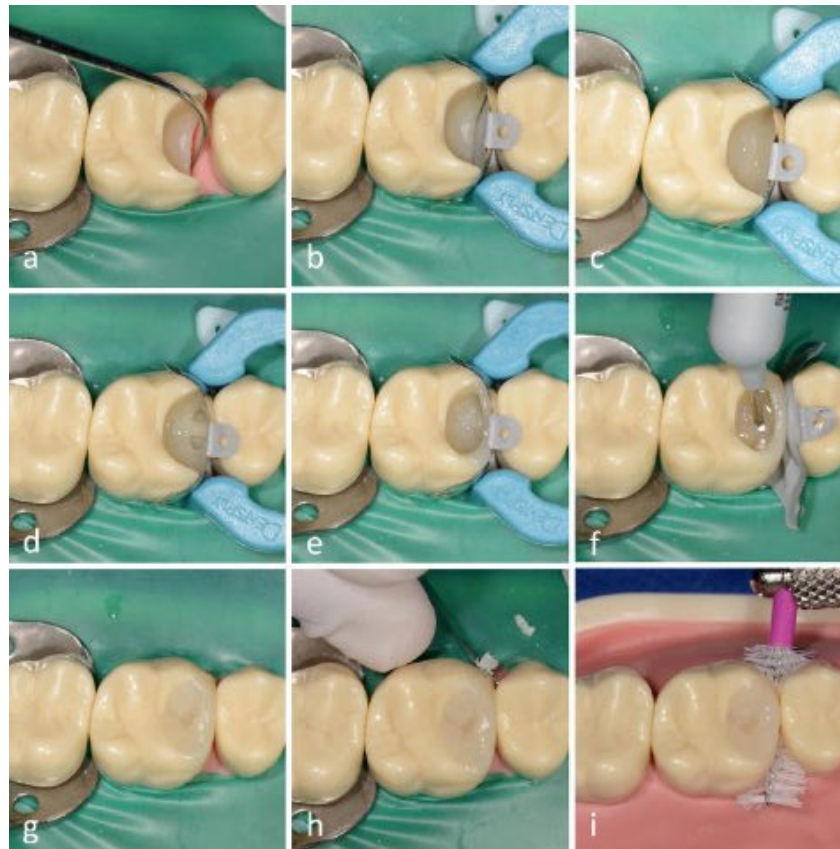
After the adhesive procedure with an etch-and-rinse adhesive system has been performed (Fig. 3a–c), the first step of restorative process can begin. The use of a matrix band for the procedure (Figs. 4 and 5) should always be preferred, as the free-hand technique (Figs. 6 and 7) is clearly more demanding.

In both cases, the snowplow technique is used to introduce the restorative material [27]. (VIDEO LINK). This is accomplished by applying a moderate amount of flowable composite

material on the cavity floor and then distributing it (Fig. 3d); next, viscous restorative composite is applied to the uncured, flowable material (Fig. 3e) and both materials are modeled together. In this way, the harder material pushes the more fluid material across all the areas of the cavity floor and up to the cavity margin. The combination of the two materials achieves better homogeneity and marginal integrity, even when more difficult cavity configurations are present. When using the free-hand technique, overfilling and spreading of the material beyond the cavity margins into the sulcus is unavoidable. Large amounts of excess material should be removed before light curing. This is achieved by carefully guiding a large Heidemann spatula in a vertical direction along the cavity margin (Fig. 3f). Sufficient light curing follows; depending on the light curing lamp used, and the depth of the cavity, the light-curing time should be prolonged for up to at least 40 seconds [7]. Smaller amounts of excess material can be smoothed out later during finishing (Fig. 3g). Finishing is performed in difficult-to-reach approximal areas using a scalpel blade (No. 12) [35], approximal files (e.g. Sonicflex Stripping, Shaping No. 73, 74, 75, 76, KaVo, Biberach, Germany) (Fig. 4h), and a fine-grained diamond-coated flame bur (e.g. No. 8889314 010, Komet, Gebr. Brasseler, Lemgo, Germany) (Fig. 4i) (VIDEO LINK). An X-ray image can be taken after treatment in order to check for marginal integrity and for any overhanging filling material. Further restorative treatment of the tooth is performed either during the same appointment or in the subsequent appointment.

### 2.5 Second step of the R2 restoration

The second step of restoration is also performed using the direct technique. Given that significant bleeding can once again be triggered after the subgingival restoration margin has been finished, ideally, a rubber dam should be applied at first, and then the matrix system. For this purpose, an anatomically pre-formed partial matrix band with a wedge and ring is suitable (e.g. Palodent V3 partial matrix



**Figure 7** Step-by-step procedure of the second phase of the R2 restoration at model tooth 16.

(a) Checking of the smooth, step-free restoration margin with the aid of a probe; if there is uncertainty regarding the quality of the restoration margin, an X-ray can be made at this point; (b) insertion of an anatomically pre-formed matrix band with a wedge and separation ring (Palodent V3 partial matrix system, Dentsply Sirona); (c) application of flowable composite WITHOUT light curing and subsequent application of restorative composite; (d) situation after removal of the approximal contact former, the cured bar of composite presses the matrix against the adjacent tooth at the level of the contact point; (e) build-up of the approximal enamel wall with restorative composite; (f) removal of the wedge and separation ring for a clearer working field (the partial matrix was folded away, but still left in the approximal space in case isolation would have been necessary once again at a later stage, for example for any corrections in the area of the approximal surface) and filling of the cavity with bulkfill composite (SDR Flow+, Dentsply Sirona) for efficient working; (g) after occlusal modeling with restorative composite; (h) removal of excess with scalpel blade no. 12; (i) fitting of an interdental brush into the interdental space that borders the finished and polished composite restoration.

system, Dentsply Sirona, Bensheim, Germany) (Figs. 5a and 7b). The matrix band must be adapted securely and tightly to the first part of the restoration in depth using the wedge. It is possible for a space to taper into the apical direction between the inner side of the matrix and the approximal wall of the already existing restoration (i.e. overcontouring) during the shaping of the matrix band in the direction of the approximal surface of the neighboring tooth. Thus, it is necessary to ensure that the wedge seals the matrix band in depth, so

that overfilling does not occur when the composite material is applied. The filling of this space is needed so that the restoration acquires an anatomically correct emergence profile in the approximal area. The cavity is then completely etched with phosphoric acid. Phosphoric acid does not have a direct surface altering effect on composite, but merely cleans it of residual blood and saliva or other possible contaminants [20]. This step is then followed by application of the adhesive system and light curing. Subsequently, through the use of the

snowplow technique described above, flowable and viscous composite material is used to fill the area between the matrix and the cavity margin into the depth (Figs. 5b and 7c). An approximal contact point former (e.g. Easy Contact Point hand instruments for molars/premolars, Zepf Dental, Seitingen-Oberflacht, Germany) is introduced into the still soft remaining material and inclined towards the adjacent tooth (Fig. 5c). Light curing is then performed (VIDEO LINK). After the removal of the contact point former, the matrix remains fixed at the level of the contact point through the composite bar (Figs. 5d and 7d). The approximal wall is then built up (5e and 7e) and the cavity is filled using the oblique layering technique (Fig. 5f). If the cavity is very deep, such as in the case of endodontic therapy, a bulkfill composite can be of practical use (Fig. 7f). The time and effort required for the layering technique is thus reduced. It is also possible to apply flowable bulkfill composite as an alternative to flowable composite during the earlier stage using the snowplow technique. In this manner, an efficient use and combination of materials is possible. Finishing, shaping and high-gloss polishing are carried out in the conventional manner using a scalpel (No. 12) (Fig. 7h), fine-grain diamond burs (e.g. No. 8889415 010, No. 8830L314 012, Komet Gebr. Braseler, Lemgo, Germany), polishing discs (e.g. Sof-Lex polishing discs, 3M Deutschland GmbH, Neuss) and a multi-step polishing system (e.g. Astropol polisher, Ivoclar Vivadent, Schaan, Liechtenstein).

### 3. Conclusion

The treatment of deep subgingival defects close to the bone presents the dentist with technical and operative challenges. The two-step restorative approach facilitates safe treatment planning and implementation, by providing flexible solutions that are in accordance with the degree of difficulty of the clinical situation. Clinical experience and initial evidence from a small number of studies to date lead to the assumption that smooth and irritation-free composite restoration margins of deep subgingi-

val defects close to the bone can be tolerated by the periodontium, even when the biological width is disregarded. However, this requires strong patient compliance with regard to home-based oral hygiene with interdental brushes and carefully planned long-term follow-up care.

### Note

For certain treatment steps marked with (VIDEO LINK) in this article, you will find the corresponding video sequences at [online-dzz.de](http://online-dzz.de).

### Conflict of interest

The authors declare that there is no conflict of interest within the meaning of the guidelines of the International Committee of Medical Journal Editors.

### References

- Bertoldi C, Monari E, Cortellini P et al.: Clinical and histological reaction of periodontal tissues to subgingival resin composite restorations. *Clin Oral Investig* 2020; 24: 1001–1011
- Bresser RA, Gerdolle D, van den Heijkant IA, Sluiter-Pouwels LMA, Cune MS, Gresnigt MMM: Up to 12 years clinical evaluation of 197 partial indirect restorations with deep margin elevation in the posterior region. *J Dent* 2019; 103227
- Dibart S, Capri D, Kachouh I, Van Dyke T, Nunn ME: Crown lengthening in mandibular molars: a 5-year retrospective radiographic analysis. *J Periodontol* 2003; 74: 815–821
- Dieckmann P, Attin T, Tauböck T: Blutstillungsmittel – Fluch oder Segen für die Adhäsivtechnik? *Quintessenz* 2018; 69: 742–748
- Dietrich T, Kraemer M, Losche GM, Roulet J: Marginal integrity of large compomer Class II restorations with cervical margins in dentine. *J Dent* 2000; 28: 399–405
- Dietschi D, Spreafico R: Evidence-based concepts and procedures for bonded inlays and onlays. Part I: Historical perspectives and clinical rationale for a biosubstitutive approach. *Int J Esthet Dent* 2015; 10: 210–227
- Ernst CP, Meyer GR, Müller J, Stender E, Ahlers MO, Willershausen B: Depth of

- cure of LED vs QTH light-curing devices at a distance of 7 mm. *J Adhes Dent* 2004; 6: 141–150
- Fabianelli A, Sgarra A, Goracci C, Cantoro A, Pollington S, Ferrari M: Microleakage in class II restorations: open vs closed centripetal build-up technique. *Oper Dent* 2010; 35: 308–313
- Felippe LA, Monteiro Junior S, Vieira LC, Araujo E: Reestablishing biologic width with forced eruption. *Quintessence Int* 2003; 34: 733–738
- Ferrari M, Koken S, Grandini S, Ferrari Cagidiaco E, Joda T, Discepoli N: Influence of cervical margin relocation (CMR) on periodontal health: 12-month results of a controlled trial. *J Dent* 2018; 69: 70–76
- Frankenberger R, Hehn J, Hajtő J et al.: Effect of proximal box elevation with resin composite on marginal quality of ceramic inlays in vitro. *Clin Oral Investig* 2013; 17: 177–183
- Frese C, Wolff D, Jörg SH: Die R2-Technik: zweiphasige direkte Kompositrestauration. *Zahnärztliche Mitteilungen* 2014; 104: 50–59
- Frese C, Wolff D, Staehle HJ: Die R2-Technik: zweiphasige direkte Kompositrestauration. *Zahnärztl Mitt* 2014; 104 (05): 50–59
- Frese C, Wolff D, Staehle HJ: Proximal box elevation with resin composite and the dogma of biological width: clinical R2-technique and critical review. *Oper Dent* 2014; 39: 22–31
- Gargiulo AW, Wentz FM, Orban B: Dimensions and relations of the dentogingival junction in humans. *The Journal of Periodontology* 1961; 32: 261–267
- Gunay H, Seeger A, Tschernitschek H, Geurtsen W: Placement of the preparation line and periodontal health – a prospective 2-year clinical study. *Int J Periodontics Restorative Dent* 2000; 20: 171–181
- Juloski J, Köken S, Ferrari M: Cervical margin relocation in indirect adhesive restorations: A literature review. *J Prosthodont Res* 2018; 62: 273–280
- Kielbassa AM, Philipp F: Restoring proximal cavities of molars using the proximal box elevation technique: Systematic review and report of a case. *Quintessence Int* 2015; 46: 751–764
- Lanning SK, Waldrop TC, Gunsolley JC, Maynard JG: Surgical crown lengthening: evaluation of the biological width. *J Periodontol* 2003; 74: 468–474
- Loomans BA, Cardoso MV, Opdam NJ et al.: Surface roughness of etched composite resin in light of composite repair. *J Dent* 2011; 39: 499–505
- Lührs A-K. Nicht nur für Installateure! – Der Einsatz des Teflonbandes in der



Zahnheilkunde. Deutsche Zahnärztliche Zeitschrift 2017; 72: 116–132

22. Lührs A-K. Subgingival = suboptimal? Die Proximal Box Elevation zur Therapie tiefer Defekte. Zahnmedizin up2date 2020; 14: 127–143

23. Müller V, Friedl KH, Friedl K, Hahnel S, Handel G, Lang R: Influence of proximal box elevation technique on marginal integrity of adhesively luted Cerec inlays. Clin Oral Investig 2017; 21: 607–612

24. Nevins M, Skurow HM: The intracrevicular restorative margin, the biologic width, and the maintenance of the gingival margin. Int J Periodontics Restorative Dent 1984; 4: 30–49

25. Nugala B, Kumar BS, Sahitya S, Krishna PM: Biologic width and its importance in periodontal and restorative dentistry. J Conserv Dent 2012; 15: 12–17

26. Oh SL: Biologic width and crown lengthening: case reports and review. Gen Dent 2010; 58: e200–205

27. Opdam NJ, Roeters JJ, de Boer T, Pesschier D, Bronkhorst E: Voids and porosities in class I micropreparations filled with various resin composites. Oper Dent 2003; 28: 9–14

28. Padbury A, Jr., Eber R, Wang HL: Interactions between the gingiva and the margin of restorations. J Clin Periodontol 2003; 30: 379–385

29. Roggendorf MJ, Krämer N, Dippold C et al.: Effect of proximal box elevation with resin composite on marginal quality

of resin composite inlays in vitro. J Dent 2012; 40: 1068–1073

30. Schmidt JC, Sahrman P, Weiger R, Schmidlin PR, Walter C: Biologic width dimensions – a systematic review. J Clin Periodontol 2013; 40: 493–504

31. Spreafico R, Marchesi G, Turco G et al.: Evaluation of the in vitro effects of cervical marginal relocation using composite resins on the marginal quality of CAD/CAM crowns. J Adhes Dent 2016; 18: 355–362

32. Staehle HJ, Frese C, Wolff D: Die zweiphasige direkte Kompositrestauration (R2-Technik). Deutsche Zahnärztliche Zeitschrift 2014; 69: 182–191

33. Tristao GC, Barboza CA, Jr., Rodrigues DM, Barboza EP: Supracrestal gingival tissue measurement in normal periodontium: a human histometric study. Int J Periodontics Restorative Dent 2014; 34: 97–102

34. Veneziani M: Adhesive restorations in the posterior area with subgingival cervical margins: new classification and differentiated treatment approach. Eur J Esthet Dent 2010; 5: 50–76

35. Wolff D, Schick S, Staehle HJ, Frese C: Novel microscalpels for removing proximal composite resin overhangs on Class II restorations. Oper Dent 2017; 42: 297–307

36. Zaruba M, Gohring TN, Wegehaupt FJ, Attin T: Influence of a proximal margin elevation technique on marginal adaptation of ceramic inlays. Acta Odontol Scand 2013; 71: 317–324.



Photo: University Clinic Heidelberg

Corresponding author

**CLARA MUSCHOLL**

Department of Oral, Dental and  
Maxillofacial Diseases

Polyclinic for Conservative Dentistry  
Im Neuenheimer Feld 400

69120 Heidelberg

[clara.muscholl@med.uni-heidelberg.de](mailto:clara.muscholl@med.uni-heidelberg.de)



Photo: University Clinic Heidelberg

**PROF. DR. MED. DENT.**

**DIANA WOLFF**

Polyclinic for Conservative Dentistry  
University Clinic Heidelberg

Im Neuenheimer Feld 400

69120 Heidelberg

[diana.wolff@med.uni-heidelberg.de](mailto:diana.wolff@med.uni-heidelberg.de)