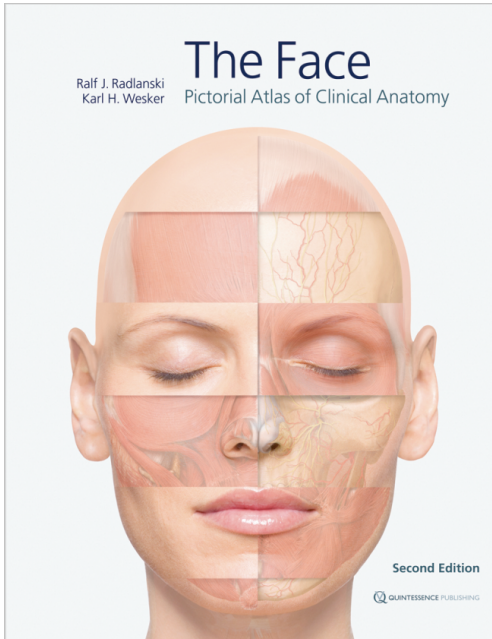


Edición: 2nd revised Edition 2015
páginas: 368
Imágenes: 380
Portada: Hardcover, 24 x 30 cm
ISBN: 978-1-85097-289-1
Nº de stock: BG116
Publicado en: junio 2015

Precio
Sujeto a cambios.

\$178.00

Quintessence Publishing Company, Inc.

 411 North Raddant Road
Batavia
Illinois IL 60510
Estados Unidos de América

 +1 (0)630 / 736-3600

 +1 (0)630 / 736-3633

 contact@quintbook.com

 <http://nginx/usa/en>

Información sobre el libro

Autores: Ralf J. Radlanski / Karl H. Wesker

Título: The Face

Subtítulo: Pictorial Atlas of Clinical Anatomy

Texto breve:

For the first time, the highly complex topographic-anatomical relationships of facial anatomy are depicted layer by layer using extremely detailed anatomical illustrations with a three-dimensional aspect. Important landmarks, anatomical details, and clinically relevant constellations of hard and soft tissues, as well as of nerves and blood vessels, have been detailed. Another important feature is that the point of view is maintained throughout while moving through the different layers of preparation. While the accompanying text and figure captions highlight specific issues, the images remain in the foreground. The elaborate illustrations are based mainly on live anatomy and corresponding images obtained from magnetic resonance imaging, with some support from anatomical preparations.

Contents

Chapter 1. The Face

- Introduction
- The face in anterior view
- The face in lateral view
- The head in vertical view
- The head in dorsal view
- The neck
- Facial expression
- The facial skeleton
- Sectional anatomy
- Schematic representations of pathways in the face

Chapter 2. The Orbital Region

- Surface topography of the orbital region
- Preseptal muscles and fat layers
- The orbital septum and the eyeball
- Vascular and nerve supply in the orbital region
- Vascular and nerve supply in the orbital region in relation to the muscles
- Sectional anatomy of the orbital region

Chapter 3. The Nasal and Midfacial Region

- Surface topography of the nasal region
- The nose in anterior view
- The nose in lateral view
- The nose in caudal view
- The nasal cavity
- The sinuses

Chapter 4. The Mouth

- Extraoral topography of the oral region
- Topographical anatomy of the oral region
- Vascular and nerve supply of the oral region
- The oral cavity
- Anatomy of the lips, teeth, periodontium and alveolar bone in sections
- The anterior oral vestibule
- Anatomy in the area around the mandibular ramus
- The temporomandibular joint

- Anatomy of the oral region in sections
- Pathways of odontogenic spread of infections

Chapter 5. The Ear

Chapter 6. The Skin and Aging of the Face

Categorías: [Anatomía, Dermatología, Cirugía oral y maxilofacial](#)