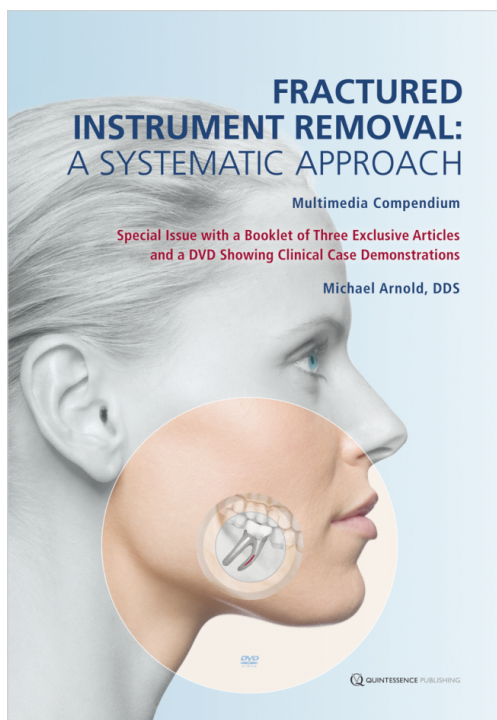



Edición: 1st Edition 2015

páginas: 30

Imágenes: 85

Portada: Multimedia Compendium  
(PAL/NTSC); Runtime: 140 min

ISBN: 978-1-85097-273-0

Nº de C0300

stock:

Publicado octubre 2014


en:

\$20.00

Precio

Sujeto a cambios.

#### Quintessence Publishing Company, Inc.

 411 North Raddant Road  
Batavia  
Illinois IL 60510  
Estados Unidos de América

 +1 (0)630 / 736-3600

 +1 (0)630 / 736-3633

 [contact@quintbook.com](mailto:contact@quintbook.com)

 <http://nginx/usa/en>

## Información sobre el resultado

**Autores:** Michael Arnold

**Título:** Fractured Instrument Removal

**Subtítulo:** A Systematic Approach

#### Texto breve:

Instrument breakage is a possible complication of mechanical preparation and widening of complex root canal systems. The more difficult the endodontic treatment, the greater the risk of instrument fracture. Recent studies show that more than 90% of all broken endodontic instruments can be successfully removed without surgical intervention. However, before undertaking a removal attempt, clinicians must know how to determine when a broken instrument should be removed and when it should be left in place; the appropriate methods for broken instrument removal; and which instruments should be used for each level of difficulty. This DVD provides a simple, step-by-step strategy to instrument removed that is illustrated by numerous images and clinical case demonstrations. This systematic approach can help significantly improve the odds of successfully removing broken endodontic instruments from the root canal. The accompanying booklet includes insightful articles on minimally invasive fragment removal using CBCT as well as a systematic approach to orthograde removal of fractured instruments.

#### Contents

##### Booklet

- Minimally Invasive Fragment Removal: Using Dental Cone Beam Computed Tomography
- Orthograde Removal of Fractured Endodontic Instruments: Methods
- Orthograde Removal of Fractured Endodontic Instruments: A Systematic Approach

##### DVD

- Complex Case with Long, Tapered NiTi Fragments in the Mandibular Molars (57:35 min)
- Fragment Removal from Maxillary First Molar with Vertucci Type VI Canal Configuration (33:33 min)
- Fragment Removal from Maxillary First Molar with Rare and Difficult Root Morphology (50:26 min)

**Categorías:** Endodoncia